

THIOURACIL IN THE TREATMENT OF COMPLICATED HYPERTHYROIDISM

Report of Six Cases

E. PERRY McCULLAGH, M.D.

R. S. DINSMORE, M.D.

AND

FLORENCE KELLER, M.D.

Since the work of the Mackenzies^{1, 2} and of Astwood and others^{3, 4} the use of thiouracil and related drugs has effected an important advance in the study of thyroid disease and may bring about a permanent change in the principles of their clinical management. Many cases have been reported, but opinions about the usefulness of these drugs vary widely. Enthusiastic observers tend to believe that thyroidectomy for hyperthyroidism will be replaced by medical treatment⁵. Others recommend the preoperative use of thiouracil for more complete control of hyperthyroidism⁶. Still others believe that the drug is dangerous and that compared with the well proved value of iodine and surgery, its disadvantages outweigh its benefits. Whatever the final decision may be, it should be kept in mind for the present that a definite mortality rate, probably somewhat over 0.5 per cent, is directly connected with the use of the drug and is entirely apart from the mortality rate of hyperthyroidism itself. It seems likely that this risk superimposed on the risk of the disease exceeds the mortality rate with treatment with iodine and competent surgery. It is possible that some of the newer related drugs, such as thiobarbital, are less toxic. It has been suggested recently⁷ that vitamin B₆ (pyridoxine) may be useful in the treatment of leukopenia of toxic origin such as may occur in the course of thiouracil therapy. Many important questions remain to be answered, among which are whether or not treatment with thiouracil will be followed by a continued remission of symptoms after the drug is stopped, how consistently such a remission can be depended upon, and how permanent it will be. The final answer remains in the future.

Even in the hands of the most conservative, however, a trial of thiouracil or related drugs seems clearly indicated in some cases, including those in which response to standard therapy is poor or in which complicating factors are present and surgery is contraindicated. Six such cases, which showed a wide variation in response to thiouracil, were selected for this report.

CASE REPORTS

Case 1—A woman, aged 70, was seen on June 24, 1943 because of goiter and sugar in the urine. Systolic blood pressure was 220 and diastolic 95 mm. of mercury. The pulse rate was 130 per minute. Height was 59 inches and weight 86 pounds. Both lobes of the thyroid gland showed visible nodular enlargement, the right lobe extending below the clavicle. Cardiac dullness extended to the anterior axillary line. Cardiac rhythm was regular, and a systolic murmur was heard at the apex. There was a moderate degree of pitting edema of the ankles. The liver was palpated one finger's breadth below the costal margin. The urine showed 4 plus sugar, and the blood sugar was 428 mg. per 100 cc. two and one-half hours after a meal.

Diagnoses of nodular goiter with hyperthyroidism, cardiac enlargement and decompensation, diabetes mellitus, and varicose veins of the legs were made.

JUNE 27—Admitted to the hospital. B.M.R. plus 48. Diabetic regimen, digitalis, and Lugol's solution, 1 cc. three times a day. Operation contraindicated. X-ray therapy, 1200 r, to thyroid.

JULY 14—Discharged on Lugol's solution, 5 minims a day, and diabetic care: carbohydrate 338 Gm., protein 114 Gm., and fat 187 Gm., calories 3581. Crystalline insulin four times daily with meals and at bedtime as follows: 46 units, 36 units, 40 units, and 10 units.

OCT. 22—Readmitted because of uncontrolled diabetes. B.M.R. plus 29 to plus 32. Weight 98 pounds. Hyperthyroidism still active. Additional x-ray therapy recommended.

OCT. 25—Thiouracil, 0.1 Gm. three times a day, substituted for Lugol's solution. First day of thiouracil therapy leukocyte count 2550, following day 2150. Thiouracil discontinued. Leukocyte count promptly returned to normal.

NOV. 1—Leukocyte count 4500. Thiouracil, 0.1 Gm. twice a day, started.

NOV. 11—Leukocyte count unaltered, dose increased to 0.1 Gm. four times a day.

NOV. 24—X-ray to thyroid, 1200 r.

NOV 29—B.M.R. plus 19, weight 109 pounds.

DEC. 1—Discharged on diabetic regimen and thiouracil, 0.1 Gm. four times a day. Diet unchanged, 160 units of protamine-zinc insulin and 150 units of crystalline insulin each morning required to maintain relative aglycosuria with fasting blood sugar level about 100 mg. per 100 cc.

DEC. 22—Pedal edema. Family physician discontinued thiouracil.

MARCH 22—Patient well until two weeks previously. Symptoms of hyperthyroidism severe. Blood sugar levels: fasting, 148 mg. per 100 cc., and 102 mg. per 100 cc. after a meal. Insulin, 130 units protamine-zinc and 140 units crystalline. B.M.R. plus 59, weight 110¼ pounds, pulse rate 96 per minute. Lugol's solution, 1 cc. three times a day, and thiouracil, 0.6 Gm. a day, prescribed.

APRIL 21—B.M.R. plus 25, pulse rate 100 per minute, diabetic control fair. Cardiac murmur, liver enlargement, and edema disappeared. Blood pressure 160/96. Diet unchanged. Insulin, 115 units protamine-zinc and 90 crystalline in morning. Leukocyte count 4450.

APRIL 26—Thiouracil reduced to 0.4 Gm. a day and Lugol's solution to 10 minims a day. Diet changed: carbohydrate 300 Gm., protein 114 Gm., and fat 127 Gm. Insulin, 60 units protamine-zinc and 45 crystalline.

JUNE 20—Lugol's solution discontinued.

AUG. 29—Leukocyte count 4900. B.M.R. plus 6. Pulse rate 64 per minute. Weight 126 pounds, a gain of 40 pounds.

In a recent communication the patient stated that she felt well, weighed 136 pounds, and was able to do her own housework.

JAN. 6, 1945—Weight 136 pounds. B.M.R. plus 5. Symptom free. Insulin has been reduced to 20 units of crystalline and 25 of protamine-zinc a day, a total of 45 units as compared to a previous maximum of 300 units a day in November 1943.

THIOURACIL IN HYPERTHYROIDISM

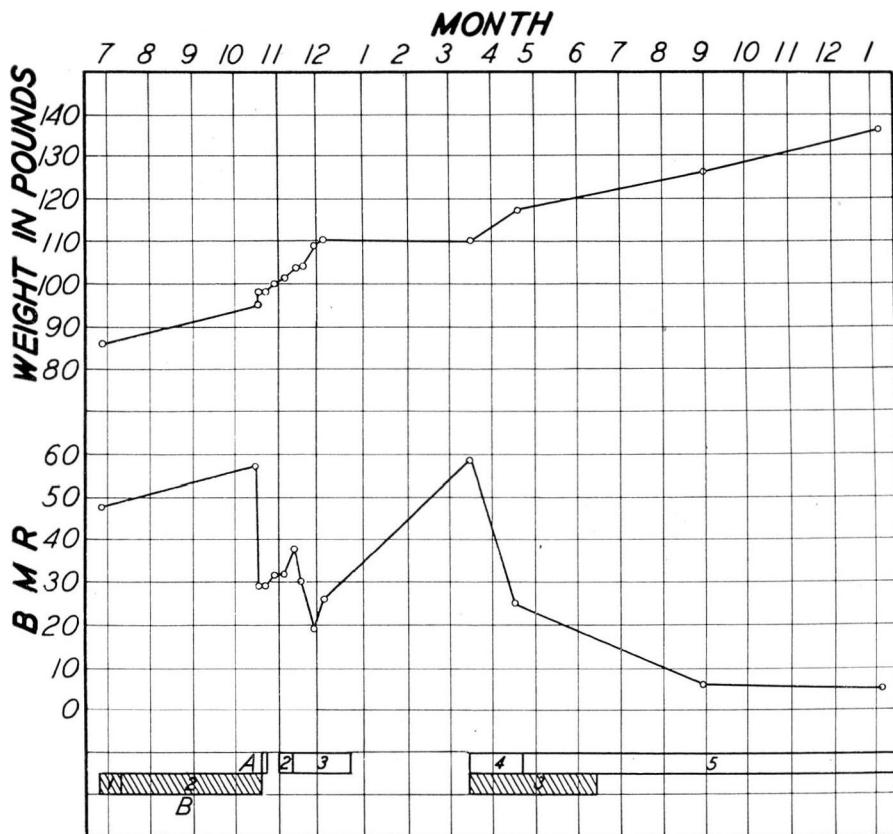


FIG. 1, Case 1. A. Thiouracil in Gm. (1) 0.3 (2) 0.2 (3) 0.4 (4) 0.6 (5) 0.4.
 B. Lugol's solution in cc. (1) 3.0 (2) 0.3 (3) 3.0.

Comment This elderly woman with a large nodular goiter, severe hyperthyroidism, cardiac decompensation, and diabetes mellitus, who probably would not have survived operation, experienced a degree of improvement on thiouracil that would not have been expected on iodine alone. Although x-ray therapy may have been beneficial, the sustained improvement was not due to this as was demonstrated by the pronounced rise in basal metabolic rate that occurred three months after thiouracil was discontinued. Improvement was slow but definite. The slowness of the response may have been exaggerated by the long continued use of iodine. When first admitted to the hospital she was emaci-

ated and bed-ridden and had severe hyperthyroidism, diabetes, orthopnea, and edema. At present she is comfortable, well, and happy and is able to be as active as she wishes. If thyroidectomy had been possible, improvement might have been more rapid but could not have been more complete. It is fortunate that the drug was given a second trial after the first occurrence of leukopenia. Operation, which was considered and postponed repeatedly, finally seemed unnecessary. Whether improvement may eventually be maintained without thiouracil is not known but is not a matter of much importance.

Case 2—An Italian woman, aged 55, was seen on March 14, 1944 with the complaint of goiter, nervousness, and weight loss of 85 pounds in five months. She had been treated for cardiac decompensation. The goiter was first discovered five weeks previously during hospital treatment elsewhere for dropsy. She had taken Lugol's solution, 15 drops three times a day, for one month prior to admission.

The patient was quite thin. Her height was 62.5 inches and her weight 102 pounds. Möbius sign was present but no exophthalmos. The goiter was moderately large, rubbery, and slightly nodular. The radial pulse rate was 76 per minute and grossly irregular. Râles were present at the lung bases, and the heart was enlarged. The apical rate was 112. There was pronounced tremor of the hands and slight edema of the feet.

APRIL 14—Admitted to the hospital. Risk of surgery considered prohibitive. Lugol's solution, 1 cc. three times a day, for seven days prior to admission.

APRIL 15—Thiouracil, 0.6 Gm. a day, and digitalis prescribed. Iodine discontinued.

APRIL 23—Thiouracil dose changed to 0.5 Gm. twice a day.

MAY 14—Discharged. Regimen including thiouracil, digitalis, and 4000 calorie diet.

MAY 19—Ankle edema.

JUNE 9—Thiouracil decreased to 0.2 Gm. three times a day.

JULY 14—Thiouracil, 0.5 Gm. a day.

AUG. 4—B.M.R. plus 8.

AUG. 25—B.M.R. minus 13. Thiouracil reduced to 0.2 Gm. a day.

SEPT. 15—B.M.R. plus 24. Thiouracil increased to 0.2 Gm. twice a day. Auricular fibrillation present, liver two fingers' breadth below costal margin, ankle edema still present.

SEPT. 30—B.M.R. minus 1. Gland strikingly enlarged. In addition to thiouracil, 0.1 Gm. four times a day, thyroid, $\frac{1}{2}$ gr. a day, given in an attempt to reduce vascularity of gland.

OCT. 7—B.M.R. plus 12. Thiouracil, 0.6 Gm., and desiccated thyroid, $\frac{1}{2}$ gr., a day. Operation again postponed because of vascularity of gland, pronounced thrill, and loud bruit.

OCT. 13—Discharged on regimen of thiouracil, 0.2 Gm. three times a day, and desiccated thyroid, 1 gr. twice a day.

NOV. 3—B.M.R. plus 18. Patient taking thyroid, 4 gr. a day, by mistake. Thiouracil, 1.2 Gm. a day, desiccated thyroid, 4 gr. a day.

NOV. 10—Thiouracil, 1.0 Gm. a day of which 0.5 Gm. was taken, thyroid, 4 gr. a day. Gland still hypervascular with loud bruit.

NOV. 24—B.M.R. plus 31. Desiccated thyroid discontinued, and iodine (iodostarine), 10 milligrams a day, prescribed. Thiouracil, 0.5 Gm. a day.

DEC. 15—Patient in automobile accident on way to clinic. B.M.R. plus 12. Gland large and bulging symmetrically on each side of neck, more solid; thrill and bruit entirely gone.

DEC. 27—B.M.R. plus 4. Chronic leg edema present.

THIOURACIL IN HYPERTHYROIDISM

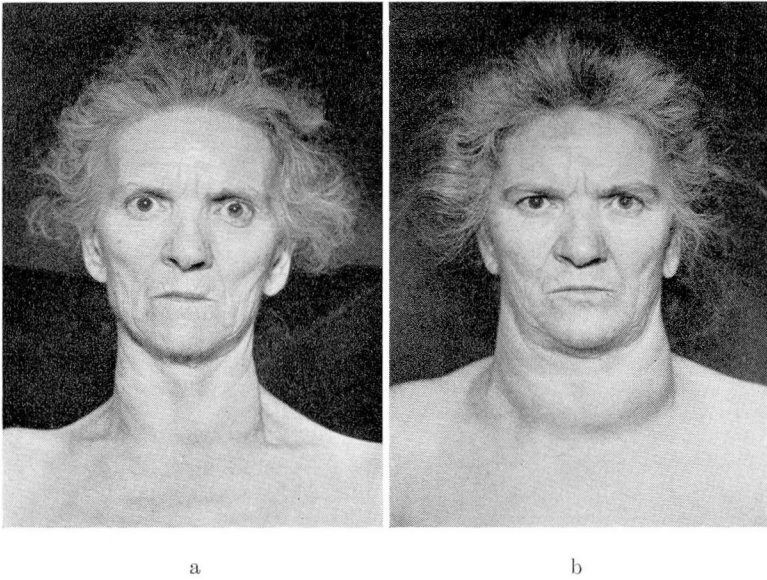


FIG. 2, Case 2. (a) April 15, 1945, before taking thiouracil. (b) After taking thiouracil as shown in chart. Note increase in weight, disappearance of expression of anxiety and stare, and pronounced change in the size of the thyroid.

Comment Clinically the patient improved greatly during treatment with thiouracil, the improvement was slow, and the clinical condition did not approximate normal. After five months of treatment an attempt was made to maintain the improvement with a dose of thiouracil of 0.2 Gm. a day, but the basal metabolic rate rose quickly. Later an attempt was made to avoid using iodine and to reduce the extreme vascularity of the gland by feeding desiccated thyroid. Doses varying from $\frac{1}{2}$ gr. to 4 gr. a day for thirty-four days failed to accomplish this. Discontinuation of thyroid medication and substitution of 10 milligrams of iodine a day was followed by rapid reduction in glandular vascularity and return of metabolic rate to normal.

Case 3—A woman, aged 50, was seen on May 25, 1944 because of goiter which was present for two years. Operation was advised elsewhere but refused. She was taking Lugol's solution, 5 drops a day, and tincture of digitalis, 15 drops a day.

Her face was thin, and she was in obvious respiratory distress. Height was 60 inches and weight $124\frac{1}{2}$ pounds. The skin was cold and moist. There was severe exophthalmos and symmetrical, smooth enlargement of the thyroid gland. The heart was enlarged to the left anterior axillary line, and there was a low systolic apical murmur. Mild pitting edema of the ankles and legs was present.

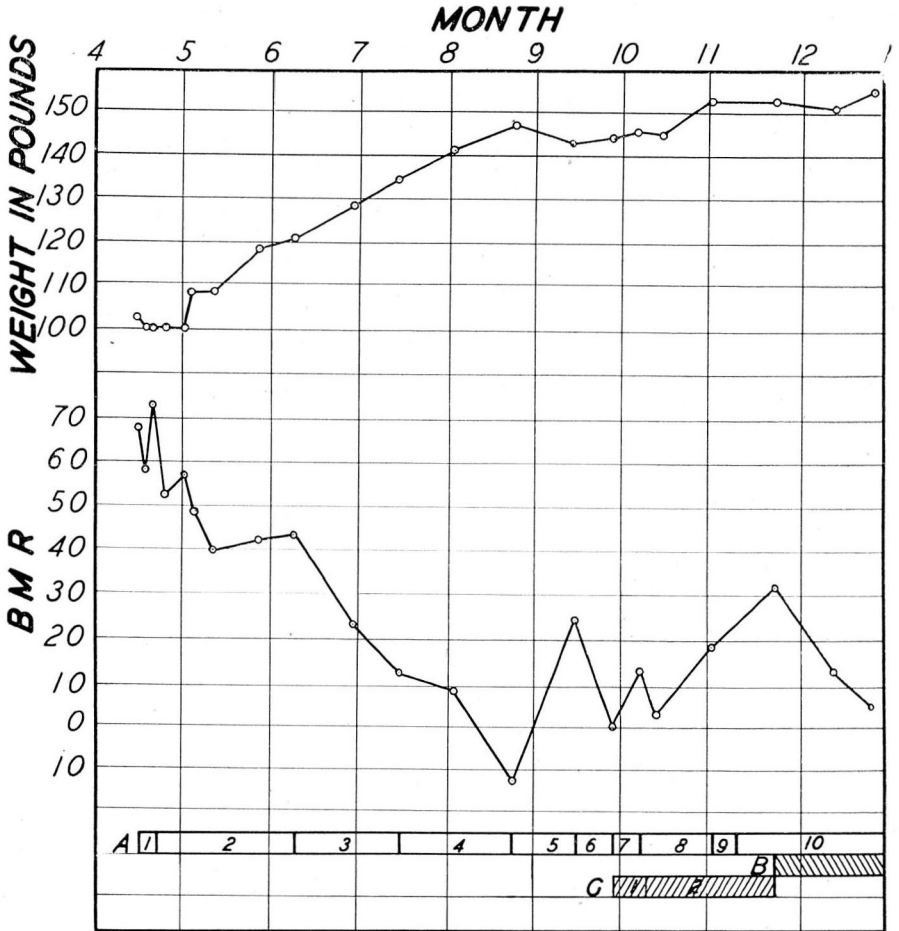


FIG. 3, Case 2. A. Thiouracil in Gm. (1) 0.6 (2) 1.0 (3) 0.6 (4) 0.5 (5) 0.2 (6) 0.6 (7) 0.4 (8) 0.6 (9) 1.2 (10) 0.5. B. Iodine—mg. of iodostarine. (1) 10.0. C. Thyroid in grains. (1) $\frac{1}{2}$ (2) 4.

JUNE 16—Admitted to the hospital for thyroidectomy. Operation postponed because of auricular fibrillation and cardiac decompensation. B.M.R. plus 58. Apical pulse rate 120 per minute, grossly irregular. Blood pressure 160/86. Cardiac condition improved under treatment, patient brought into compensation and discharged. Lugol's solution discontinued, iodine (potassium iodide), 5 gr. three times a day, begun.

JULY 10—Thiouracil, 0.2 Gm. three times a day. Iodine continued.

SEPT. 18—Fibrillation still present. B.M.R. plus 22. Pulse rate 100 per minute. Weight 143 pounds. Patient appeared calm and greatly improved. Iodine discontinued.

OCT. 7—Leukocyte count 3950.

OCT. 11—B.M.R. plus 21. Pulse rate 104 per minute. Weight 144 pounds. Fibrillation still present. Ankles swollen, liver slightly enlarged. Right shoulder stiff and painful, motion restricted as in peri-arthritis frequently associated with hyperthyroidism. Otherwise, patient felt better than at any previous time during treatment.

THIOURACIL IN HYPERTHYROIDISM

Nov. 1—Patient felt ill. Right shoulder and hand painful with considerable swelling of hand. Thyroid gland enlarged, no bruit. Leukocyte count 3150, 28 per cent neutrophils. Thiouracil discontinued. Patient admitted to the hospital. Lugol's solution, 1 cc. four times a day, prescribed, but only part taken. Fever and rash appeared. Iodine discontinued, rash subsided, appetite improved. B.M.R. plus 38. Pulse rate 100 per minute. Weight 124½ pounds.

Nov. 6—Lugol's solution discontinued.

Nov. 14—Discharged on thiouracil, 0.1 Gm. twice a day, plus digitalis.

Dec. 5—Patient felt ill. Losing weight, appetite poor. B.M.R. plus 54. Pulse rate 92 per minute. Leukocyte count 3800. Thiouracil dose increased from 0.2 Gm. to 0.6 Gm. a day.

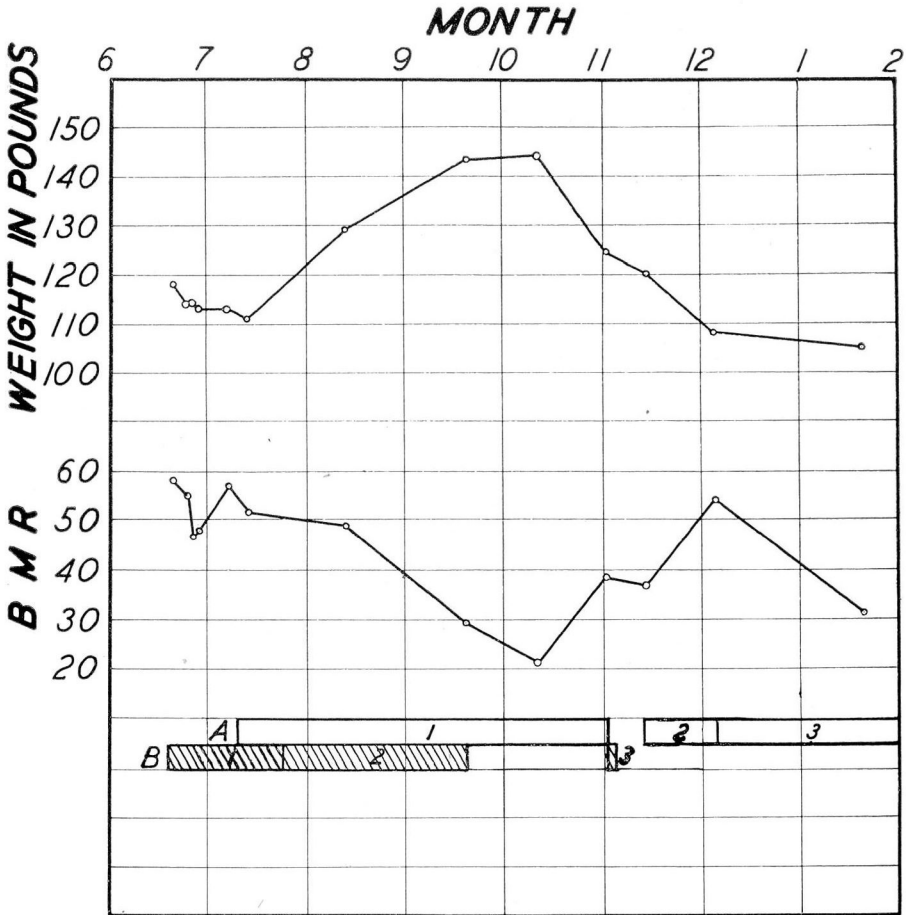


FIG. 4, Case 3. A. Thiouracil in grams. (1) 0.6 (2) 0.2 (3) 0.6. B. Iodine (1) and (2) 15.0 gr. potassium iodide. (3) 4.0 cc. of Lugol's solution.

DEC. 18—Patient confined to bed with decubitus ulcer. Shoulders less stiff and painful. Little evidence of hyperthyroidism. Slight but definite increase in size of goiter. No bruit nor thrill. Heart enlarged, soft systolic apical murmur and short aortic murmur. Pulse rate 67 per minute, regular. Treatment for ulcer recommended. Other treatment unchanged.

JAN. 20, 1945—B.M.R. plus 31. Weight 105 pounds. Leukocyte count 4300, 50 per cent neutrophils, 48 per cent lymphocytes, 2 per cent monocytes.

Comment The effectiveness of thiouracil was demonstrated in this case of hyperthyroidism in which operation was contraindicated. The patient improved strikingly for about one and one-half months, after which her general condition seemed to become worse, and the leukocyte count decreased. Progress was further retarded by peri-arthritis of the shoulder, by polynuclear leukopenia, which appeared dangerous enough to warrant withdrawal of the drug, and finally by iodine rash, fever, nausea, weight loss, and a rise in the basal metabolic rate. After many months of treatment the total improvement over her condition at the beginning of treatment was slight. Thiobarbital was prescribed in an attempt to obtain further benefit without undesirable side reactions.

Case 4—A woman, aged 62, came to the Ophthalmology Department on January 25, 1944 because of failing vision. Hemorrhagic retinitis was present. The patient was referred to the Department of Endocrinology on March 1. A diagnosis of diabetes mellitus was made on the basis of 4 plus urine sugar and a blood sugar level of 500 mg. per 100 cc. two hours after a meal. A nodular goiter was found. The pulse rate was 100 per minute, and the blood pressure was systolic 190 and diastolic 90 mm. of mercury. Hyperthyroidism was diagnosed. A smooth mass was palpated in the cul-de-sac of the pelvis. The patient was put on a diabetic regimen consisting of carbohydrate 190 Gm., protein 92 Gm., fat 100 Gm., calories 2118, and insulin, 30 units of protamine-zinc and 5 units of crystalline each morning. She was also given digitalis, 1.5 gr. daily.

MARCH 6—B.M.R. plus 38. Weight 115 pounds. Pulse rate 88 per minute. Thyroidectomy advised but refused.

MARCH 22—B.M.R. plus 39. Weight 115¼ pounds. Pulse rate 92 per minute. Because of clinical evidence of hyperthyroidism, placed on thiouracil, 0.2 Gm. three times a day.

APRIL 12—Digitalis prescribed. Thiouracil, 1.0 Gm. a day.

MAY 5—Thiouracil, 0.2 Gm. three times a day.

MAY 15—Dependent edema present. Patient refused B.M.R. determination.

MAY 22—Condition unchanged. B.M.R. plus 40. Weight 120½ pounds. Pulse rate 92 per minute.

JUNE 14—B.M.R. plus 35. Weight 123 pounds. Pulse rate 92 per minute.

JUNE 23—Much improved. Gaining weight.

JULY 7—Edema of legs. Rumpel-Leede fragility test positive. 90-100 petechiae in 1 inch circle on arm. B.M.R. plus 49.

AUG. 9—Ankles, thighs, hands swollen. Face puffy. Dyspnea, loss of appetite, weakness. Insulin reactions. Thiouracil reduced to 0.4 Gm. a day.

SEPT. 2—Admitted to hospital. Dyspnea, swelling of abdomen, feet, and ankles. Severe pain in lower back and thigh for five months. After few days of urinary incontinence, acute urinary retention developed.

THIOURACIL IN HYPERTHYROIDISM

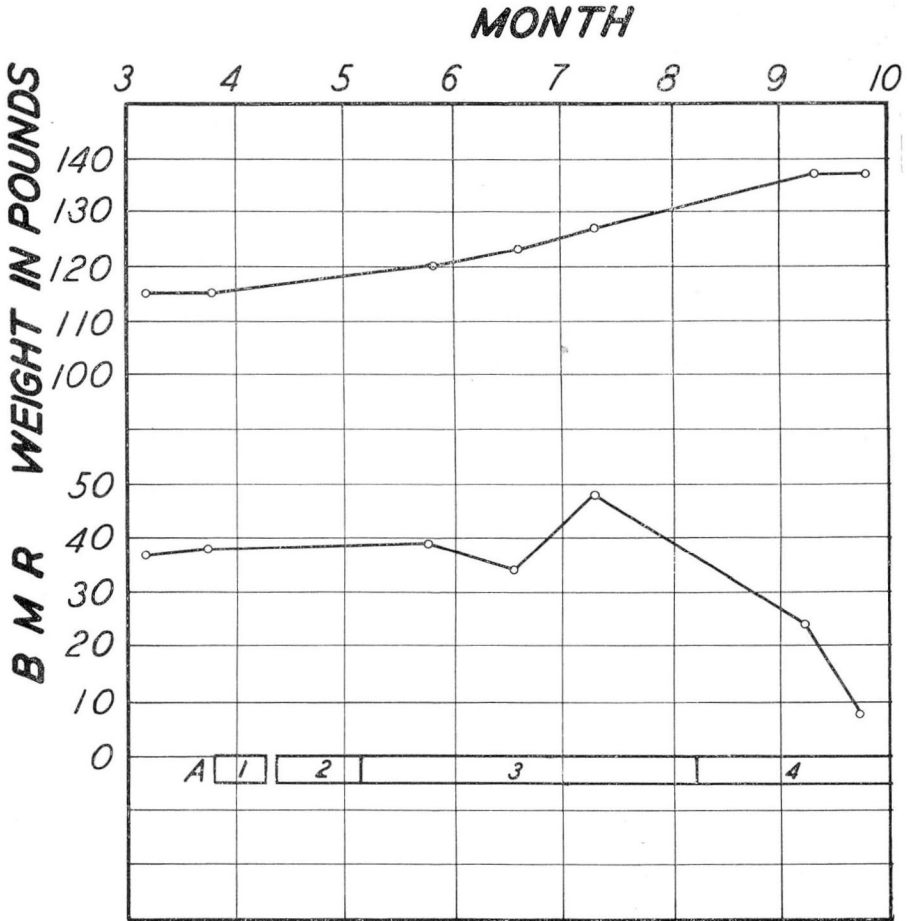


FIG. 5, Case 4. A. Thiouracil in Gm. (1) 0.6 (2) 1.0 (3) 0.6 (4) 0.4.

SEPT. 8—B.M.R. plus 24. Digitalis given. Diagnosis: pelvic tumor with questionable cord lesion, primary or secondary. Operation not considered possible.

SEPT. 22—B.M.R. plus 9.

SEPT. 30—Discharged on thiouracil, 0.4 Gm. a day, digitalis, 1½ gr. a day, bladder medication, supportive therapy, diabetic regimen.

Comment This patient had a nodular goiter, moderately severe hyperthyroidism, pelvic tumor, and diabetes mellitus. Operation was originally advised, but the risk would have been considerably greater than average because of cardiovascular condition. Later operation was not possible. Because of the poor cardiovascular condition and the grow-

ing pelvic mass, which was probably an ovarian tumor, she failed to show much improvement. That the hyperthyroidism diminished considerably in severity was evidently due to thiouracil.

Case 5—A woman, aged 56, was first seen on July 22, 1944 because of goiter. In the preceding two years she lost 80 to 85 pounds in weight. She complained of being nervous and hot and of having shaky hands. Stiffness of the knees and neck and generalized aching had been present for some time.

Physical examination revealed a well developed, obese woman, whose skin was warm and moist. Systolic blood pressure was 190 and diastolic 90 mm. of mercury. Pulse rate was 120 per minute. There was slight exophthalmos with some retraction of the upper lids. Both lobes of the thyroid gland were visibly and palpably enlarged, and a bruit was present over the gland. A soft aortic systolic murmur was heard.

A diagnosis of diffuse goiter with hyperthyroidism was made, and the patient was given Lugol's solution, 1 cc. three times a day. The basal metabolic rate was plus 81. Sedatives were ordered, and hospital care was suggested.

JULY 31—Pain in both shoulders. Severe limitation of motion. Diagnosis: peri-arthritis of shoulders. Analgesic medication given. B.M.R. plus 48.

AUG. 10—Much improved. B.M.R. plus 58.

AUG. 25—Shoulder pains increased. Pain and aching generalized. For thirty-nine days phenobarbital, $\frac{1}{2}$ gr. three times a day, and Lugol's solution, 1 cc. three times a day. Medication continued, and heat applied to shoulders. B.M.R. plus 60. Hospital care urged.

AUG. 31—Severe shoulder pain caused sleeplessness. Pulse rate 130 per minute. B.M.R. plus 71. Hospitalization for treatment of peri-arthritis and hyperthyroidism. Given sedation, traction applied to arms. Diathermy and massage refused. Improvement moderate, shoulder pain severe. Physical therapy discontinued.

SEPT. 5—After Lugol's solution, 1 cc. three times a day, for fifty days, thiouracil, 0.6 Gm. a day, started. Patient restless and difficult to manage. Insisted on getting out of bed and fell frequently in doing so. Lugol's solution was discontinued for five days, then given again.

SEPT. 25—Severely "toxic" appearance developed. Temperature rose rapidly to 106 F. and pulse rate to 150 per minute. Possibility of drug reaction prompted withdrawal of thiouracil. Condition continued critical. Despite oxygen and other supportive measures, entered acute thyroid crisis. Died.

NECROPSY—Hypertrophy and dilatation of heart (460 Gm.). Acute portal inflammation and focal necrosis of liver. Healed nondeforming endocarditis of all four valves. Persistent thymus. Bronchopneumonia (terminal). Hypertrophy, hyperplasia, and multiple small adenomas of thyroid. Thyroid 205 Gm. Grossly firm, moderately friable, contained multiple circumscribed nodules 3 to 4 cm. in diameter. On cross section most tissue pale yellow. Microscopically follicles chiefly small but varied considerably in size. Acinar lining cells chiefly columnar, many of the secreting type. Acini contained colloid in varying amounts.

Comment This patient had severe hyperthyroidism with the late complication of very painful peri-arthritis. No improvement of consequence was produced by any of the treatment. In retrospect it must be questioned whether she might have been able to withstand operation if she had entered the hospital when first advised. Also the question might be asked whether the thiouracil action was obscured because of quantities of thyroid hormone stored in the gland during the iodine action, or whether the thiouracil effect was inhibited in some other way.

THIOURACIL IN HYPERTHYROIDISM

Perhaps it was used over too short a time to expect much effect. The severity of the hyperthyroidism was obviously an important factor and was made apparent by lack of response to iodine. The gland showed little of the hyperplasia commonly associated with a thiouracil reaction.

Case 6—A woman, aged 65, was first seen on March 2, 1944. She had been well except that her voice had become quite deep, and diagnosis of chronic laryngitis had been made. Vocal cord paralysis was not present. In December 1943, auricular fibrillation developed, and the basal metabolic rate was plus 42. A high basal metabolic rate was confirmed several times, readings as high as plus 55 being found. The patient was quite nervous. There was a mild diabetes readily controlled by diet. X-ray films taken elsewhere were reported to show a substernal goiter.

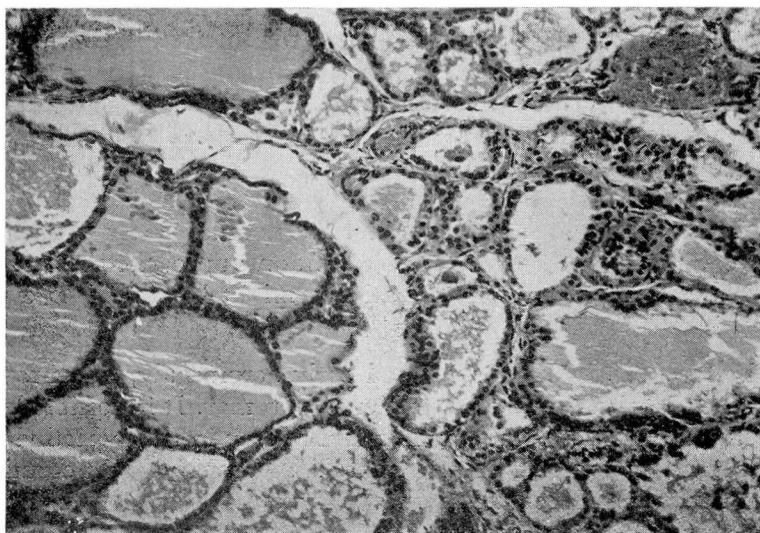


FIG. 6, Case 5. Relatively large amount of colloid in many of the follicles and virtually none of the evidences of hyperplasia commonly seen in the thyroid gland after treatment with thiouracil.

The pulse rate was 132 per minute. Auricular fibrillation was present. She had gained 10 pounds in weight, and pitting edema was present. The eyes were somewhat prominent, and there was a mild digital tremor. The patient had been given Lugol's solution for five days and thiouracil, 0.6 Gm. a day, for sixty-five days. No clinical improvement was apparent, although she gained about six pounds in weight, and the cholesterol level rose from 108 to 149 mg. per 100 cc. Lugol's solution, 5 minims a day, was recommended.

MARCH 22—Admitted to the hospital for possible thyroidectomy. No palpable thyroid enlargement. Height 65 inches, weight 138 $\frac{3}{4}$ pounds. Apical cardiac rate 104 a minute. Facial appearance suggested early acromegaly, but x-ray films of sella turcica reported normal.

Given digitalis, $1\frac{1}{2}$ gr. a day; Lugol's solution, 1 cc. three times a day; and supportive therapy. B.M.R. plus 43. Electrocardiogram showed evidence of myocardial damage, auricular fibrillation, and digitalis effect. Diuretic therapy, mercuperin, and ammonium chloride instituted. Sedation. Placed on diabetic regimen: carbohydrate 190 Gm., protein 80 Gm., fat 200 Gm., and 15 units of protamine-zinc insulin daily.

MARCH 28—B.M.R. plus 29. Weight 125 pounds. Pulse rate 46 per minute.

APRIL 11—Became steadily worse. Ate poorly. X-ray therapy totaling 1200 r to thyroid gland.

APRIL 25—B.M.R. plus 32. Weight 107 pounds. Pulse rate 80 per minute.

MAY 6—B.M.R. plus 31. Weight 108 pounds. Pulse rate 92 per minute.

MAY 10—Thiouracil, 0.4 Gm. a day.

MAY 12—Cerebral accident, right hemiplegia, coma.

MAY 13—Death.

Comment This is an example of apparent and unexplained failure of thiouracil. No improvement of clinical significance occurred while the patient took thiouracil for two months. It is interesting that there was also little or no improvement on iodine, which is also unexplained. Although the patient's course was steadily downhill, death never appeared imminent and apparently was due to a vascular accident. At no time was there reason to doubt the accuracy of the diagnosis. In retrospect it appears that the relative severity of the hyperthyroidism in this case was lessened. In other cases with large nodular goiter many months were required before the patient's condition approached normal, and continuation of thiouracil with patience might have lead to eventual control in this instance.

The facial appearance suggested early acromegaly, but x-ray films of the sella turcica revealed no evidence of tumor. It is possible but not likely that a pituitary factor similar to that seen in the hyperthyroidism of acromegaly may have been present. Whether this might constitute a reason for some difference in response from that seen in other cases of hyperthyroidism is not known.

SUMMARY

These 6 cases of hyperthyroidism were selected because they demonstrate a wide range in response to treatment with thiouracil, varying from complete recovery in severe complicated hyperthyroidism to apparent total lack of response. All of these cases except one (case 5) were treated over many weeks or months. All were considered inoperable for one reason or another. In such cases any kind of treatment is at a great disadvantage, and where improvement is obtained with thiouracil, it may be considered greater than that possible with any other type of therapy. Various interesting facts are demonstrated by these cases.

- (1) Improvement in chronic severe hyperthyroidism may be very slow.
- (2) Pronounced enlargement of the gland with striking increase in

THIOURACIL IN HYPERTHYROIDISM

vascularity may occur. (3) In one instance the glandular vascularity failed to change materially during a month on thyroid therapy, but was quickly reduced with doses of iodine of 10 milligrams a day. (4) After as much as five months of treatment with thiouracil and a good response, the metabolic rate may rise rapidly with reduction of the dose to 0.2 Gm. a day. (5) In one case a mild leukopenia proved to be no contraindication to thiouracil, and recovery was the most complete we have seen with this drug. In one case moderately severe polymorphonuclear leukopenia occurred.

In summary the response in the various cases was as follows:

Case 1—Apparently complete control with rehabilitation.

Case 2—Considerable improvement without rehabilitation of the patient. However, although we did not see the patient before the onset of hyperthyroidism, her present condition probably approximates that prior to the present illness.

Case 3—Striking improvement was followed by polymorphonuclear leukopenia, severe iodine reaction, peri-arthritis, and exacerbation of the hyperthyroidism.

Case 4—Improved greatly so far as the metabolic rate was concerned, but clinical status remained poor largely because of factors other than hyperthyroidism.

Case 5—Died in thyroid crisis after iodine had been used for nearly six weeks. Thiouracil was given a trial of twenty days during which true crisis supervened.

Case 6—Little or no improvement on thiouracil for two months and none subsequently on iodine therapy. After resumption of thiouracil therapy the patient died suddenly from a cerebral vascular accident.

REFERENCES

1. MacKenzie, J. B., MacKenzie, C. G., and McCollum, E. V.: The effect of sulfanilyl-guanidine on the thyroid of the rat. *Science* 94:518 (Nov. 28) 1941.
2. MacKenzie, C. G., and MacKenzie, J. B.: Effect of sulfonamides and thioureas on thyroid gland and basal metabolism. *Endocrinology* 32:185 (Feb.) 1943.
3. Astwood, E. B., Sullivan, J., Bissell, A., and Tyslowitz, R.: Action of certain sulfonamides and of thiourea upon function of thyroid gland of rat. *Endocrinology* 32:210 (Feb.) 1943.
4. Astwood, E. B.: Treatment of hyperthyroidism with thiourea and thiouracil. *J.A.M.A.* 122:78 (May 8) 1943.
5. Thompson, W. O., and Thompson, P. K.: Changes in treatment of toxic goiter produced by thiouracil. *Proc. Central Soc. Clin. Research* 17:10 (Nov.) 1944.
6. Bartels, E. C.: Thiouracil: Its use in the preoperative management of severe hyperthyroidism (Preliminary report). *J.A.M.A.* 125:24 (May 6) 1944.
7. Canter, M. M., and Scott, J. W.: Effect of vitamin B₆ (pyridoxine) in the treatment of leukopenia and granulocytopenia of toxic origin in humans (Preliminary report). *Science* 100:545 (Dec. 15) 1944.