

PARTIAL GIGANTISM OF THE FACE WITH NEUROLOGIC COMPLICATIONS

LOUIS J. KARNOSH, M.D., AND W. JAMES GARDNER, M.D.

Although it is a rather rare "embryonic error," congenital unilateral hypertrophy of the tissues of the face has been described in the medical literature at frequent intervals since 1836. Werner¹ in 1905 gave this subject special attention when he reviewed a case of his own and reported his findings on histologic examination of the soft tissues involved in the hypertrophy. A year later Pagenstecher² described a patient with this deformity and, on performing a cosmetic operation, found that the enlargement involved not only fat and connective tissues but the salivary glands, the mucous membranes, and even the external maxillary artery and facial nerve.

More recently Rushton³ pointed out that the structures chiefly affected in partial gigantism of the face are among those derived from the first branchial arch, but other parts may be involved, such as the nostril, the upper jaw, the zygoma, the frontal bone, and the ear. The increased size of the teeth arising from the latter maxillary process in contrast with those developing from the premaxilla is invariably noted in this condition and should aid in differential diagnosis, for no such dental disparity occurs in simple hyperplasia or in tumors.

It is generally agreed that in this disturbance the involvement is never restricted to one type of tissue or to one organ. In a sense partial gigantism of the face is the antithesis of hemiatrophy of the face, and a neurotrophic influence may be present in both. However, Werner¹ emphasized that the hypertrophied regions do not correspond to the distribution of certain nerves or groups of nerves. Sensory disturbances are rarely found, and paralysis of a motor nerve, when it does occur, appears to be secondary to hypertrophy of the soft tissues through which it passes.

In all carefully studied cases it is evident that embryonic dispositions rather than neurotrophic factors are responsible for the overgrowth. The areas of hypertrophy are clearly delineated by the embryonic folds and cleavage lines of the face. The line of demarcation between normal growth and overgrowth is usually established along the fusion zones between the premaxilla and the lateral maxillary process in the upper jaw and in the midline of the lower jaw. Hence dental malformations are

important criteria in establishing the extent and degree of hypertrophy, which will usually be found to involve the teeth, gums, and alveolar bone and all accessory structures in the mucous membranes.

Although such hypertrophy has been known to involve any or all structures of the face on one side, no data are on record indicating that the brain case or its contents may be affected by the abnormal process. No predominantly neuroblastic structure has been incorporated in the description of partial gigantism of the face, although portions of motor nerves passing through the hypertrophied connective tissues, particularly the facial and hypoglossal trunks, have been found to be greatly thickened.

However irregular and variable this anomaly may be, it has always been assumed that the process is entirely a surplus growth in tissues other than those that arise from the neural tube. Hence a patient with partial gigantism of the face who presents symptoms of cerebral complication is not without interest and may indicate that this puzzling congenital disturbance may extend to structures within the skull.

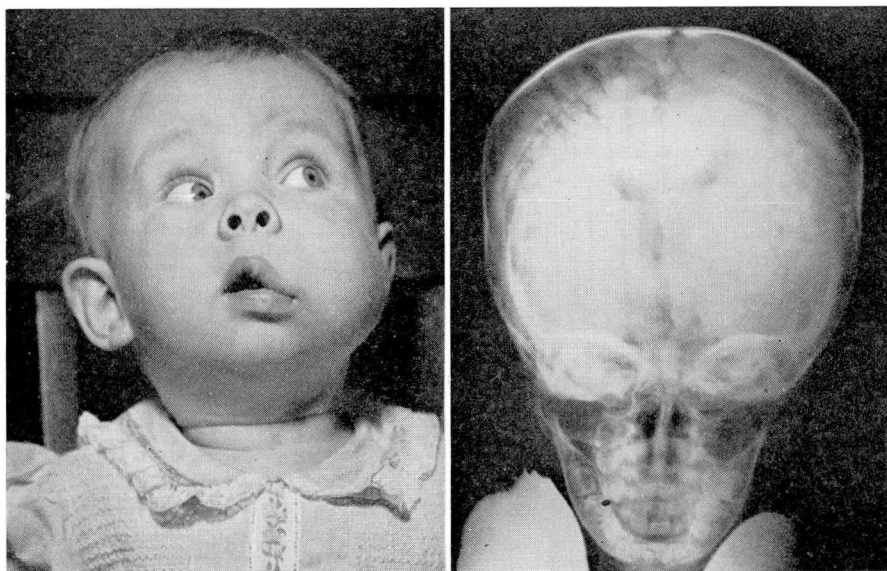


FIG. 1 (a) Partial gigantism of left side of face involving cheek, lips, and jaws.

- (b) Pneumoencephalogram showing abnormal angle in vertical midline of skull and face. The filling defect over left hemisphere is more than an artefact and indicates hypertrophy of that side of brain.

CASE REPORT

A baby girl, aged 14½ months, was first examined on August 5, 1944. She was the first-born child of a mother aged 34. Labor was somewhat prolonged, but delivery was accomplished with ease by high forceps. For several minutes the child showed a moderate degree of asphyxia with shallow respirations. The obstetrician immediately observed an obvious deformity of the left cheek and left superior maxilla, which was not the result of instrumentation. This swelling was described as elephantiasis of the cheek.

When the baby was about 3 months old, she had her first episode of unconsciousness and subsequently had twelve to fifteen more. These seizures appeared without warning and lasted from fifteen minutes to an hour; the child became pale, produced a clicking sound from the throat, lost consciousness, and became utterly limp without muscular twitching or stiffening of the limbs. She had frequent bleeding from the left ear and recently bled rather profusely from the mouth when cutting two upper teeth. The teeth on the left side of the jaws erupted much earlier than did those on the right side.

Despite these handicaps the youngster appeared healthy, ate very well, and developed normal toilet habits. However, at 14 months of age she manifested no desire to crawl, stand, walk, or talk. She sat up, played normally with toys, and was rather overactive and somewhat irritable and sensitive to noise. She made no attempt to support herself when propped up in the standing position.

The skull, on examination, showed no gross asymmetry. The head was not enlarged, and the anterior fontanelle was normal in size for her age. Percussion note over the head was not increased. There was a light brown discoloration on the left side of the neck extending from the mastoid area to the supraclavicular level. This was a nevus not unlike that existing in the same area described by Werner.¹

The left cheek was enormously enlarged (fig. 1a). There was slight enlargement of the left nostril. In the upper lip the overgrowth was restricted to the portion arising from the left lateral maxillary process. The cheek substance was soft and sagged downward. The lower lip showed less pronounced hypertrophy beginning in the midline. The left ear was slightly longer than the right (0.2 cm.), and the contours were slightly irregular.

The contents of the oral cavity showed as prominent an asymmetry as did the face. The left side of the tongue was much thicker, and the papillae were more prominent than were the same structures on the right side.

The teeth and the hard tissues of both upper and lower jaws presented a striking contrast (fig. 2). The midline of the upper jaw appeared to be shifted to the right; the gum tissue was greatly thickened in the areas extending to the left of a clearly marked cleavage line between the lateral incisor and the first bicuspid. Three erupted teeth in the hypertrophied left jaw were definitely larger than the corresponding teeth on the opposite side, and all erupted prematurely. The same asymmetry to a lesser degree was present in all lower teeth and periodontal structures in the lower jaw beginning in the midline.

Neurologic examination did not disclose elements of particular value in establishing cause for the attacks of unconsciousness or the delay in standing and walking. The eyeballs appeared equal in size; the pupils were equal and reacted to light and distance. There was a tendency to bilateral internal squint. Glimpses of the eyegrounds were obtained, and these were quite clear. Corneal reflexes were normally intact.

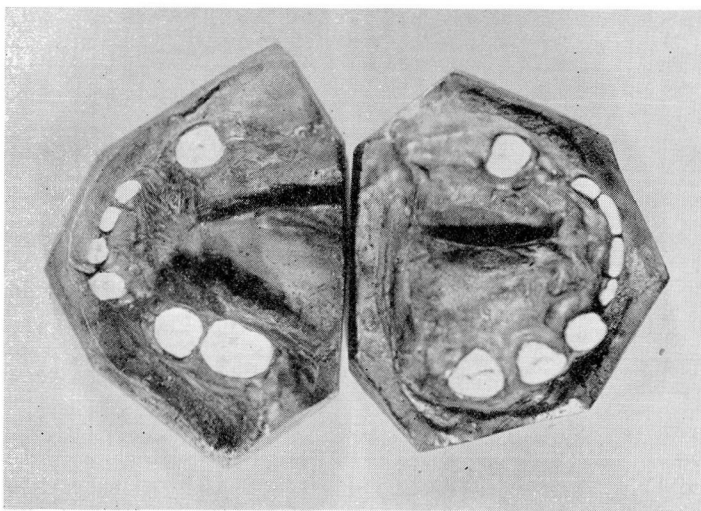


FIG. 2 Plaster casts of upper and lower jaws showing general overgrowth of teeth, gums, and jaws in left lateral maxillary and mandibular embryonic processes. (Courtesy of Dr. Charles A. Resch.)

The zygomatic branches of the left facial nerve, which passed through the substance of the enlarged left cheek, were paralyzed. The left angle of the mouth sagged, and grimacing movements of this part of the face were entirely absent. The facial muscles about the eyes were bilaterally active.

Hearing tests could not be accurately performed. The child gave no evidence of difficulty in swallowing. Tongue movements appeared normal.

Deep tendon reflexes were normally present and active in all extremities. No pathologic reactions could be elicited. There was no evidence of spastic or flaccid weakness in the lower extremities which would explain the child's indisposition to learning to walk.

Roentgenographic and pneumoencephalographic studies were made (fig. 1b).^{*} Most striking was the angle between the vertical anteroposterior midline plane of the brain case and the same plane of the face. The asymmetry of the facial bones was not pronounced, probably because bone density was not greatly increased on the hypertrophied side.

Of particular interest to the neurologist was the evidence of asymmetry of the cranial contents. Air studies showed the left lateral ventricle to be elevated and both ventricles shifted to the right. Over the entire left hemisphere was a filling defect in definite contrast to the normal air spaces outlining the right hemisphere. These findings were subject to several interpretations, among which could be included the idea that the left cerebral hemisphere was part of the congenital partial gigantism.

Electroencephalographic studies were made in an attempt to classify the seizures of unconsciousness in terms of epileptic variants. Bipolar recordings were made over six regions of the scalp. The record showed an almost continuous two to three per second

^{*} Courtesy of Dr. J. E. McClelland, University Hospitals, Cleveland.

activity. Some of these slow waves alternated with a rapid spike not unlike discharges observed in petit mal epilepsy and were bilaterally synchronous, indicating that the abnormality was subcortical and not due to a local cortical lesion.

SUMMARY

The patient had partial gigantism of the face. Roentgenography, pneumoencephalography, and electroencephalography indicated that the ipsilateral cerebral hemisphere was also involved. From a purely clinical standpoint it is difficult to correlate the attacks of unconsciousness and the delay in walking with unilateral cerebral hypertrophy. However, there is no reason to believe that such asymmetry must present unilateral neurologic defects or a focal form of epilepsy.

The pigmented nevus on the neck is suggestive and is emphasized in the consideration of the child's seizures, because the cerebrum may be the site of the angioma.

Treatment of partial gigantism of the face is almost entirely a problem for the plastic surgeon. Pagenstecher's² experience with surgery has not been very encouraging. His patient had a resection of some of the fatty tissue of the cheek at 3 years of age. Hypertrophy recurred and even became worse. Another operation at the age of 35 revealed huge overgrowth of the parotid gland and duct, blood vessels, skin, fatty and connective tissue, and local nerve trunks. Resection of nonessential tissue and a large part of the zygomatic bone produced only a slightly satisfactory cosmetic effect. The treatment of the facial nerve palsy is an even more insurmountable problem, because any nerve transplant from another source is likely to be affected by the peculiar local factor, which distorts all tissues in the vulnerable area. Whatever the surplus growth factor may be in partial gigantism of the face, it is evident that its activity is sharply restricted by definite embryonic zones.

If it is true that partial facial hypertrophy may be associated with partial brain hypertrophy, then it can be said that the neurologist has a new syndrome for which no rational treatment exists at present. Neurosurgery will be indicated only if and when intracranial tension is increased and progressive brain symptoms make their appearance.

REFERENCES

1. Werner, R.: Congenitale halbseitige Gesichtshypertrophie. *Arch. f. klin. Chir., Berl.*, **75**: 533-541, 1905.
2. Pagenstecher, E.: Einseitige angeborene Gesichtshypertrophie. *Deutsche Ztschr., f. Chir., Leipz.*, **82**:519-529, 1906.
3. Rushton, M. A.: Partial gigantism of face and teeth. *Brit. Dent. J.* **62**:572-578, 1937.