

CUTANEOUS BLASTOMYCOSIS

Report of Two Cases, One Being a Mucocutaneous Form

GEORGE H. CURTIS, M.D., and EARL W. NETHERTON, M.D.
Department of Dermatology

Blastomycosis is an uncommon but well known chronic infectious disease produced by budding yeast-like organisms commonly grouped as blastomycetes. North American, South American, and European types have been described. Although the botanical classification of the various organisms producing the protean forms of the disease has not yet been clarified, a more recent and probably correct term for the causative organism of the North American type is *Zymonema dermatitidis* (blastomyces dermatitidis), for the South American types (paracoccidioidal granuloma) *P. braziliensis*, *P. cerebriforme*, and *P. tenui* (*B. braziliensis*), and for European blastomycosis, *Cryptococcus neoformans*.¹ Since the latter two types do not originate in the United States this paper is concerned only with the North American type, under which the 2 cases herein described fall.

North American blastomycosis, as well as the other two types, occurs in two forms, systemic and cutaneous. Cutaneous lesions appear in 95 per cent of cases of the systemic form. A brief description of the clinical manifestations of the systemic form will bring into sharp relief those of primary cutaneous blastomycosis as exemplified by one of our 2 cases. The cutaneous lesions in systemic blastomycosis are probably hematogenous in origin, as they appear in successive crops of subcutaneous nodules and abscesses with subsequent development into ulcers having a purulent discharge. They tend to be disseminated on the unexposed parts such as the back, abdomen, and thighs, although the face and extremities may be involved.

In the cutaneous form the sites of predilection are the exposed surfaces, head, and neck, especially the face, hands, wrists, forearms, legs, and ankles, the frequency of sites in the order named. Owing to auto-inoculation, multiple lesions are usually present. The eruption begins as a papulopustule that slowly increases in height and extent until it becomes a granulomatous lesion with a sharply elevated border. The surface is verrucous or papilliform with elevations and crypts which are covered with a crust. On removal of the crust miliary abscesses (crypts) which exude a somewhat mucilaginous, mucopurulent fluid of a dirty white color are exposed. The exposed surface bleeds readily. The border is

surrounded by a bluish-red, infiltrated zone in which miliary abscesses may be seen, although at times only with a magnifying glass. Occasionally the lesions are somewhat flat with a firm, dry, verrucous surface from which purulent material is obtained with some difficulty. The lesions are only slightly tender unless secondary infection results in more acute inflammation. Cutaneous blastomycosis does not spread to the regional lymph nodes nor to the blood stream, but occasionally systemic dissemination occurs.

There is a less superficial form of the cutaneous type called the gummatous type of cutaneous blastomycosis, in which the lesions originate in the deep corium or subcutaneous tissue. They are deep-seated, dark red, soft nodules surrounded by a violaceous zone of infiltrated skin. Other nodules appear in the periphery. Upon reaching the surface the lesions ulcerate, forming fungating masses. The ulcers are surrounded by the characteristic bluish-red borders containing miliary abscesses. Cutaneous blastomycosis is chronic and may continue over a period of years, although cures have been reported. Systemic blastomycosis, on the other hand, is highly fatal. Martin and Smith² state that 93 per cent of these patients die within three years after the onset of symptoms.

The exact habitat of *Zymonema dermatitidis* is unknown, but the organism is thought to be a plant saprophyte. Cases of blastomycosis have been reported from thirty states in the United States and from Canada. The majority occur in the section of the United States east of the Mississippi River and north of the southern boundaries of Tennessee and North Carolina. Outside of this section a goodly number have been reported from Louisiana. Persons have become infected in large cities as well as in the country. The disease occurs in slum districts and among people working in cellars and excavations, hide workers, milkers, stable employees, handlers of dead animals, railroad men, and farmers.

Martin and Smith² found in the literature one proved case of direct transmission of the disease in man. The inoculation occurred during a necropsy. Infections resulting from thorn pricks, chewing of blades of grass, and scratches from bramble bushes have been reported. Men are infected more often than women, the ratio being 9 to 1, and the age incidence of cutaneous blastomycosis ranges from 6 months to 80 years, the highest incidence in the third to the fifth decades and the peak in the fourth decade of life.

Histologically, primary cutaneous blastomycosis is characterized by irregular, papilliform, epithelial projections above the normal skin level. The surface is covered with dried pus, blood, and debris. There is extensive hyperplasia of the prickle cell layer, producing branching

down growths of various sizes and shapes. Numerous intra-epithelial abscesses are filled with polymorphonuclear leukocytes, red blood cells, an occasional giant cell, and often contain the causative yeast-like organisms. In the corium there are acute to chronic inflammatory changes with miliary abscesses. Occasionally a tubercle-like nodule with giant cells that often contain one or two of the organisms is present. The single and budding yeast-like cells are readily seen in hematoxylin and eosin sections or other stains, particularly methylene blue. Mycelial growth does not occur in tissue.

When pus from an abscess is placed on a microscopic slide and potassium hydroxide solution is added, the highly refractile, double-countered, single and budding organisms stand out. On culture mediums such as Sabouraud's and dextrose agar mycelial growth is obtained, while on blood agar incubated at 37° C. the yeast-like form is obtained. By subculture the yeast-like growth may be maintained on blood agar and kept in a refrigerator.

Of the 2 cases presented the first represents the typical primary cutaneous form of blastomycosis with multiple lesions; case 2, we believe, demonstrates the rarest form of cutaneous blastomycosis.

Case Reports

Case 1. (Fig. 1a) A white man and farmer, aged 60, came to the Clinic on November 3, 1941, presenting a number of growths on the face, trunk, and extremities. He lived in West Virginia and spent his working time between his grocery store and his farm. In June, 1941, he had first noticed two small, itchy red "mosquito bites" on the forehead. The lesions continued to grow in size, and during the next several weeks other "bites" appeared on the sides of the face, on the chin, elbow, left knee, and back. Growth of the lesions was regular and painless.

In September a positive blood serologic test for syphilis was discovered, and the patient was given antisyphilitic therapy including arsenicals, mercury rubs, and calomel. The lesions themselves were treated with roentgen rays. He had lost 26 pounds since June but felt in good health. He had had gonorrhea at the age of 20 but did not recall having had a chancre. The patient denied taking bromides or iodides.

The patient was obese but showed evidence of weight loss; otherwise, the general physical examination was normal. There were ten granulomatous growths on the cutaneous surface, two in the middle of the forehead, one just lateral to the right eyebrow, two on the left side of the face, two under the chin, one on the right forearm near the elbow, one on the upper part of the back, and one on the left patella. The lesions were annular and oval and from 2 to 5 cm. in diameter, rising abruptly to about 0.5 cm. from the skin surface. They were flat and covered with crusts beneath which were numerous tiny abscesses. The hairs were loose and easily lifted out of the lesions in the bearded region. From the bases of the lesions bluish-red zones extended peripherally for several millimeters and were studded with minute abscesses. The regional lymph nodes were not enlarged.

The hemogram and blood chemistry including bromine and iodine determinations were normal, and a chest roentgenogram showed normal findings. Droplets of pus were

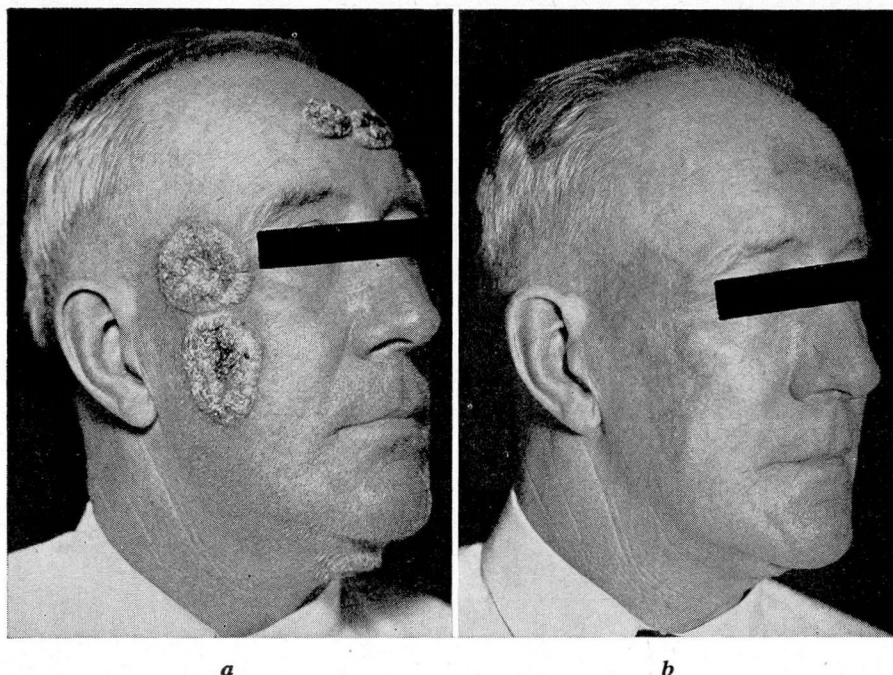


FIG. 1. Case 1 (a) November, 1941, (b) January, 1942. Showing the effect of iodide therapy.

mixed with a 20 per cent potassium hydroxide solution on a microscopic slide. A number of highly refractile, single, and budding organisms were readily seen under high power (fig. 2). Mycelian growths were obtained on cultures of the pus. The organism was considered to be *Zymonema dermatitidis*.

A small piece of one of the lesions was excised for histologic examination. The histopathology was typical of the description given in the preceding section.

Clinical course and treatment. As soon as the diagnosis was made the patient was given 1.3 Gm. (gr. 20) sodium iodide intravenously. Within twelve hours the lesions became swollen, red, and painful, but there were no toxic symptoms, and the reaction subsided in the next twelve hours. A saturated solution of potassium iodide was then administered in gradually increasing doses until the patient was taking 12 Gm. daily. In addition the lesions were treated with superficial unfiltered roentgen irradiations, 150 r. to each lesion. Antisymphilitic therapy was administered.

The patient was seen again in January, 1942, at which time the lesions had considerably healed (fig. 1b); however, the organisms were again obtained from military abscesses in several lesions. The patient was lost from observation after this visit.

Case 2. (Fig. 3.) A white man, aged 49, a resident of Ohio, came to the Clinic on April 1, 1946, complaining of hoarseness and a growth of three months' duration on the upper lip. The hoarseness was first noticed in December, 1945. In the beginning it was transient and slight but became progressively worse and continuous. About three weeks later a "cold sore" appeared on the upper lip, growing steadily in size and extent until it had invaded the nostrils, nose, and most of the upper lip. The involved nasal region became sore and painful. Concurrently, the hoarseness increased in severity. During the period from December, 1945, to April, 1946, the patient had lost about 4 pounds

and felt increasing weakness and loss of vitality. He was subject to frequent colds in the winter time. The patient was a boiler maker and worker in a railroad roundhouse. He could not recall having chewed straw or grass or twigs nor sustaining any injury about the mouth. A serologic test for syphilis in February, 1946, was negative.

The general physical examination revealed a well built and well nourished man. A large, dry, crusted granulomatous mass involved most of the upper lip, extended into the nostrils and to the tip of the nose. The surface was verruca-like and the color dull red. The margins of the lesion were sharp and perpendicular. There were a few small pustules at the mucocutaneous border of the left commissure. The vermilion border of the lip was invaded. The border was a dull bluish-red, and in it miliary abscesses were seen. In the mouth an extensive vegetating lesion involved most of the hard palate, and

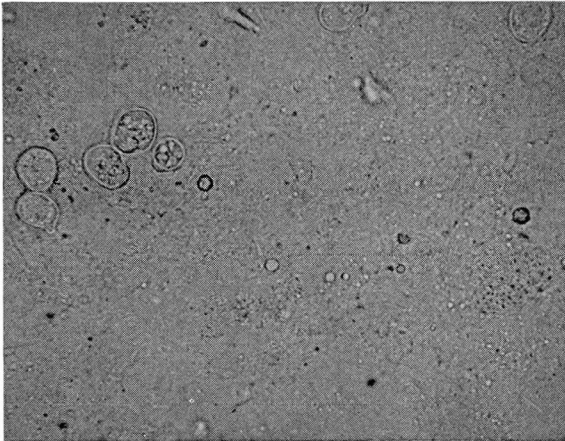


FIG. 2. Photomicrograph, single and budding organisms under high power (x 450).

a number of small red papules were present on the buccal mucosa. There appeared to be no direct connection between this lesion and that on the lip and nose. On laryngoscopic examination a vegetating lesion appeared to involve the left half of the larynx, the true cord, and extended superiorly to include the false cord to the base of the epiglottis and the aryepiglottic fold. The left cord was in an abducted position and did not move on phonation. The lesion was covered with an exudate. The surface of the right vocal cord was somewhat rough.* The submaxillary lymph nodes were palpable bilaterally, which was thought to be due to secondary infection.

A roentgenogram of the chest showed normal findings, as did the hemogram, urinalysis, and blood chemistry, including bromine and iodine determinations. Blood Wassermann and Kahn tests were negative. A droplet of pus from an abscess in the lesion on the lip and on the hard palate was treated with 20 per cent potassium hydroxide solution, and numerous single budding yeast-like cells were found. Mycelial growth was obtained on culture. The organism was identified as *Zymonema dermatitidis*.

Clinical course and treatment. The patient was hospitalized for trial on penicillin therapy. After 1,700,000 units had been administered the lesions seemed to be less inflammatory but at the same time had increased in size and extent, while the regional lymph nodes had subsided to normal size. Sulfathiazole, 1 Gm. every four hours, and

*The laryngoscopic examination was made and lesions described by Dr. H. E. Harris of the Department of Otolaryngology.

urea, 30 Gm. every four hours, were administered for seven days. The blood level of sulfathiazole rose to 8.5 mg. and that of urea to 63 mg. per 100 cc. of blood, but the lesions showed no appreciable change. Upon discharge from the hospital the patient was given a saturated solution of potassium iodide. In June, 1946, the patient reported considerable improvement but has since been lost from observation.

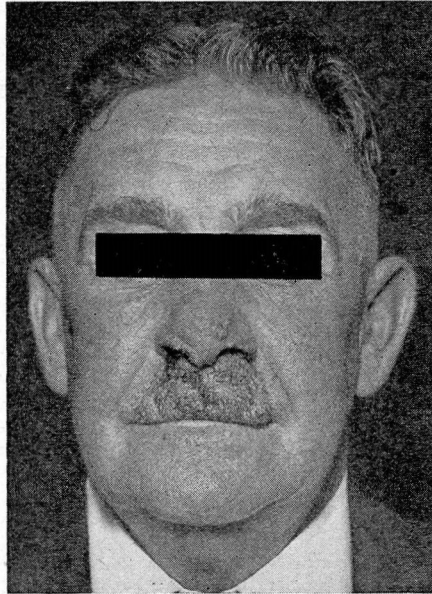


FIG. 3. Case 2. Cutaneous blastomycosis involving the upper lip and nose.

Comment

From the standpoint of diagnosis it was fortunate that the patient of case 1 had not been given iodides during the two months' treatment for syphilis before the diagnosis was established, otherwise the lesions would have been considered syphilitic by the response to treatment and may have been cured. According to Stokes,³ cutaneous blastomycosis may at times be benefited by arsphenamine, and Ormsby and Montgomery⁴ state that in some of their cases arsphenamine rendered the disease more responsive to iodides. This patient was treated with mapharsen (m-amino parahydroxyphenylarsine oxide), therefore it is a matter of speculation as to whether or not the drug has the same effect as arsphenamine. Notwithstanding the presence of a positive blood serologic test for syphilis and the history of gonorrhea some twenty years before, the papillomatous surface studded with miliary abscesses, the bluish-red border containing abscesses in contrast to the elegant arciform infiltrated borders of late syphilitic lesions, and the yeast-like cells

contained in the pus would have immediately disclosed the true nature of the disease.

Martin and Smith² caution against rapid treatment of blastomycosis before an estimate of the degree of hypersensitivity to the organism is made. They advocate preliminary hyposensitization with vaccines because mild to severe reactions may occur. In this case such a reaction occurred and was manifested by acute redness, swelling, pain, and tenderness of the lesions following the injection of sodium iodide.

We believe that case 2 presents a rare form of the disease. Martin and Smith,² in their review of 347 case reports, mentioned 1 case of laryngeal blastomycosis and a questionable case of blastomycosis of the larynx and vocal cords. Our belief that the primary site of inoculation was the larynx and vocal cords is based upon the chronology of symptoms in the history and the fact that there was no continuity of the lesions in the larynx, hard palate, and upper lip. It is possible that under a condition of ordinary extent of excursion of tidal air during the respiratory cycle one or several organisms would lodge on the "shelf" created by the vocal cords in the larynx. On the other hand, the patient could not recall having introduced any foreign objects into the mouth. Furthermore, because of the anatomic structure of the larynx and hard palate, lesions produced by more recent infection may give rise to symptoms here earlier than will older points of inoculation in the skin, where growth of lesions may proceed more slowly. Roentgenograms showed no evidence of lung involvement, and the patient showed no clinical symptoms of systemic infection. Hence it is unlikely that the lesions were secondary to a pulmonary infection.

In vitro experiments show that in order to obtain a partial inhibitory effect on the growth of *Zymonema dermatitidis*, concentrations of 50 mg. per 100 cc. or higher of the sulfonamides are necessary. This is about five times the concentration that may be safely maintained in the blood for any length of time. Franks and Taylor⁵ reported the failure of sulfonamides and penicillin in systemic blastomycosis. Thus the failure of penicillin and sulfathiazole and urea is well demonstrated in this case.

Tuberculosis cutis (tuberculosis verrucosa cutis), cutaneous lesions of tertiary syphilis, bromide and iodide gummas, and carcinoma (epitheliomas) are most often confused with the cutaneous lesions of blastomycosis. Tuberculosis verrucosa cutis and cutaneous blastomycosis may at times be clinically indistinguishable, but the finding of *m. tuberculosis* on smear or culture and/or animal inoculation, increased skin sensitivity to tuberculin, and the histologic picture is in direct contrast with the finding of organisms of blastomycosis, and the histology only superficially resembles that of tuberculosis verrucosa cutis. Usually

the miliary abscesses in the border of the lesion of blastomycosis are not seen in tuberculosis verrucosa cutis. Syphilis complicating blastomycosis is a coincidence. The ulcerative gummas and late nodulo-ulcerative lesions of syphilis are not verrucous or papilliform and do not show miliary abscesses within or at the border. Bromide and iodide gummas are usually exquisitely tender and more painful than the lesions of blastomycosis, which produces only mild symptoms. The miliary abscesses are not found in the periphery of bromide or iodide gummas. A history of ingestion of bromides or iodides is almost always obtained, and iodides and bromides are frequently present in high concentrations in the blood. Epitheliomas present a smooth border in which telangiectasis is seen. The border is nodular and pearly and does not contain miliary abscesses. The surface of a skin carcinoma when ulcerated is granular rather than papilliform and does not contain miliary abscesses. There are no miliary abscesses at the periphery, as in blastomycosis. The histologic picture of carcinoma is characteristic. The finding of the yeast-like organisms in the pus and tissue sections of a lesion suspected of being blastomycosis establishes the diagnosis.

Summary

Two cases of North American blastomycosis are described. One case was of the primary cutaneous form, the initial lesions located on the forehead and the others produced by auto-inoculation. The coincidental discovery of a positive blood serologic test for syphilis led to antisyphilitic therapy. However, the fact that iodide was not administered made it possible to establish the diagnosis, which otherwise might have been confused and delayed for a considerable period. A mild Herxheimer reaction resulted from initial rapid treatment but could have been avoided by slow treatment with gradually increasing doses of potassium iodide. The second case we believe to have demonstrated a rare form of the disease, the initial lesions originating in the larynx and the mouth, and lip lesions occurring later. This case represents the mucocutaneous form of cutaneous blastomycosis. *Zymonema dermatitidis* was found in the pus on culture and in tissue sections in both cases.

References

1. Moore, M.: Blastomycosis, coccidioidal granuloma and paracoccidioidal granuloma. *Arch. Dermat. and Syph.* 38:163-190 (Aug.) 1938.
2. Martin, D. S., and Smith, D. T.: Blastomycosis. (*American Blastomycosis, Gilchrist's Disease*) I. A review of the literature. *Am. Rev. Tuberc.* 39:275-304 (March) 1939. II. A report of 13 new cases. *Am. Rev. Tuberc.* 39:488-515 (April) 1939.
3. Stokes, J. H.: *Modern Clinical Syphilology*, Revised ed. 2 (Philadelphia: W. B. Saunders Co., 1942).
4. Ormsby, O. S., and Montgomery, H.: *Diseases of the Skin*, ed. 6 (Philadelphia: Lea and Febiger, 1943).
5. Franks, A. G., and Taylor, H. G.: Cutaneous blastomycosis complicated by meningitis. *Arch. Dermat. and Syph.* 48:88-90 (July) 1943.