

DIFFERENTIAL DIAGNOSIS BETWEEN CEREBRAL AND CEREBELLAR DEGENERATION AND BRAIN TUMOR

AVERILL STOWELL, M.D., and W. JAMES GARDNER, M.D.
Department of Neurosurgery

The clinical picture of a brain tumor and a degenerative process in the brain is often similar, and the manifestations of these two pathologic states which progress slowly or intermittently make a differential diagnosis difficult.

During the last eight years at the Neurological Institute of New York, at the University Hospital of Baltimore, and the Cleveland Clinic a relatively large number of patients have been seen who were suspected of having a brain tumor but were shown to have atrophic disease of the brain by pneumo-encephalography or craniotomy. Fifty-two of these cases of cerebral and cerebellar atrophy were selected for a study to determine possible differences in the signs and symptoms of brain tumor and brain atrophy.

In these selected cases the average age was 33 with the youngest 17 and the oldest 47. In all cases hypertension, arteriosclerosis, toxic factors, trauma, and birth injury were ruled out as well as possible by detailed histories and examinations. The patients did not fit into the clinical picture of Pick's disease, Alzheimer's disease, or other clearly defined brain atrophies. There have been reported, however, cases of pseudo-sclerosis and of multiple sclerosis which clinically had certain resemblances to the patients in our series.

The average duration of symptoms before pneumo-encephalography or craniotomy was two and one-quarter years. The course of the disease in the great majority of the patients was slowly progressive, but there were several instances of fluctuation or an apparent arrest or improvement in the signs and symptoms. Many of the patients were followed over two years, while the longest follow-up was ten years.

The chief presenting symptoms were convulsive seizures and headache. Weakness of one side of the body, blurred vision, difficulty in saying words or in understanding words, loss of memory, lack of ability to concentrate, and staggering gait also were listed as complaints. On examination the most consistent finding was an increased excitability of the tendon reflexes on one side of the body. The following charts will present the principal symptoms and signs.

Symptoms

<i>Headache</i>	21	<i>Convulsions</i>	27
Localized	11	Generalized	15
Generalized	10	Jacksonian features	12
Weakness on one side of the body	17		
Mental symptoms	14		
Numbness on one side of the body	10		
Aphasia, motor or sensory	6		
Blurred vision	6		
Double vision	3		

Signs

Hyperreflexia on one side of the body	40
Hemiparesis or hemiplegia	22
Visual field defect	11
Ataxia, clumsiness, or staggering gait	11
Hypesthesia on one side of the body	10
Blurred disks or edema of the disk	8
Cranial nerve palsy	6
Unequal pupils	4
Primary optic atrophy	3

The tentative diagnosis in these cases was most often a tumor in the motor or premotor area. Parasagittal meningioma was considered in 14 cases.

The pneumo-encephalograms were extremely interesting. In two instances the diagnosis of brain tumor was actually more convincing after air studies when a definite ventricular shift was observed. However, nothing more than an atrophic process was found at the time of the craniotomy. In 26 cases the films showed changes consistent with atrophy of the right or left cerebral hemisphere. In 24 cases the atrophy was diffuse. In both groups there was either ventricular dilatation or marked increase of cortical markings or both.

The accompanying plates show typical examples of the encephalographic pictures (figs. 1, 2, 3, 4).

In the 17 cases which had complete removal of the fluid at encephalography the volume of fluid removed was greater than 160 cc. The greatest amount of fluid obtained was 338 cc. It was arbitrarily assumed that the average amount of spinal fluid in a normal healthy adult of 30 years of age was between 110 and 140 cc.

The spinal fluid pressure was below 150 mm. of water in all cases, and the spinal fluid protein was below 60 mg. in every case.

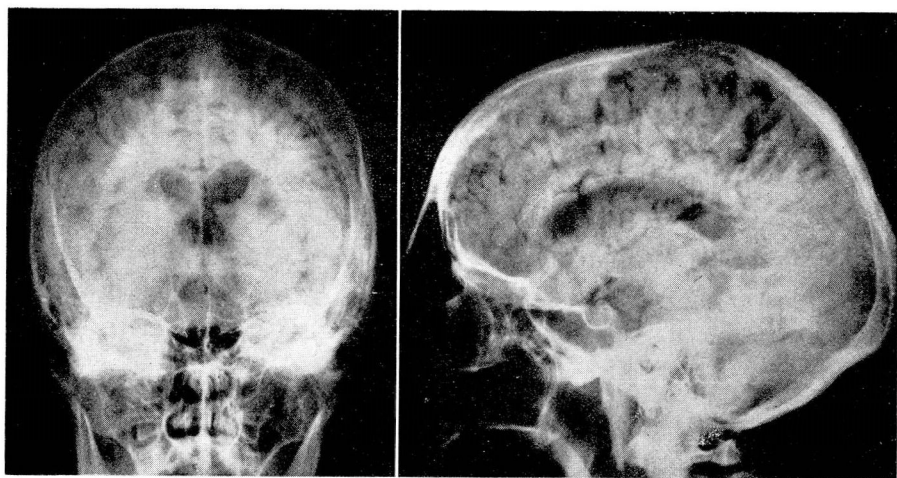


FIG. 1. Anteroposterior and lateral views showing dilatation of the lateral ventricles, more marked on the left. Increased cortical markings are visualized.

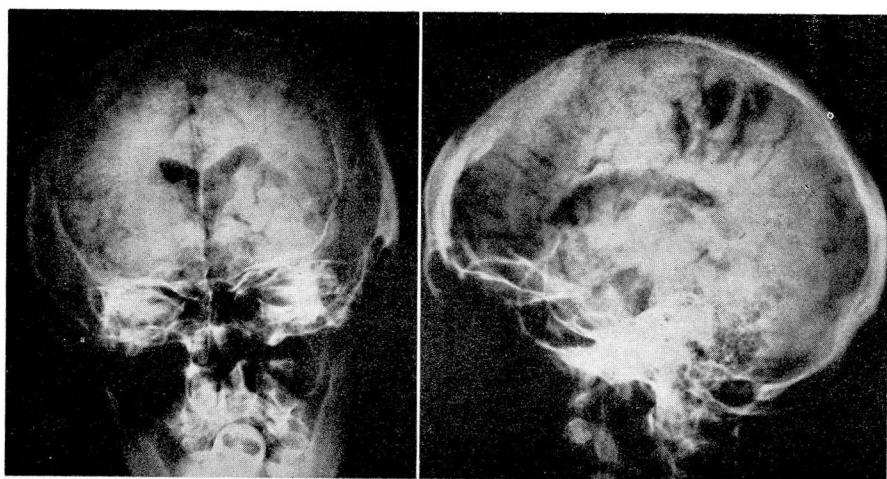


FIG. 2. Anteroposterior and lateral views showing minimal enlargement of the lateral ventricles with localized increase of cortical markings. Patient complained of Jacksonian convulsions of sensory type.

Electro-encephalograms were obtained in 18 cases. Thirteen of these showed evidence of a localized lesion usually corresponding to the clinical localization. In 4 cases a diffuse dysrhythmia was found and in 1 case a normal reading was recorded.

Discussion of Signs and Symptoms

Headache

Of the 21 patients who complained of headache, 11 localized the pain on one side of the head. This was usually to the side of the greatest atrophy, a localization which is occasionally found in posttraumatic degenerative disease of the brain. Of the 3 cases of cerebellar atrophy 2 had suboccipital headache. In our experience the headache of brain tumor is not as frequently referred to one side as it is in this type of brain atrophy.

Another interesting feature of the pain was the marked or moderate relief experienced by the patient upon lying down; in this sense it simulated the headache after spinal puncture, sometimes called the hypotensive headache. This headache is considered to be caused by a decreased cerebrospinal fluid pressure as recorded by the manometer, but in the cases selected no low spinal fluid pressures were recorded. The pain was described as dull or throbbing and in over 50 per cent of the cases as a severe pressure sensation associated with pain. In 3 cases the headache was improved after pneumo-encephalography and in 1 case was entirely relieved. In contradistinction to this, the headache of brain tumor is occasionally increased by the prone position and is rarely improved by pneumo-encephalography. In the atrophic diseases as well as in brain tumor the pain is increased by exertion. Excitement, nervousness or emotional strain is likely to increase the headache of brain atrophy to a greater degree than that of brain tumor.

In some cases of brain atrophy the headache tended to have a periodicity, lasting two to four hours and recurring at fairly regular intervals. The headache was rarely nocturnal.

Mental symptoms and signs

Of the strictly mental symptoms, loss of recent memory was the most commonly encountered. In the patients who were seen within a year or two after the onset of symptoms there was often found a depressed emotional state, of which the patient and his family or friends were clearly aware. The patients had a relatively keen insight into their disabilities and there was rarely a dulling of the whole sensorium as was

found in the infiltrating gliomas. These patients with atrophic brain disease appeared more fully aware of their surroundings than the tumor cases did, and their perceptive integration of ideas had a clarity and sensitivity that was not often found in patients with brain tumors. It is possible that in the atrophic diseases, an explanation for this lies in a selective degeneration of certain cortical layers or pathways.

Convulsions

In the majority of cases the convulsive seizure was not distinguishable from that occurring in brain tumor. There was, however, a fairly high proportion of cases with distinct reference of the convulsions to one side, and in many cases Jacksonian components were observed. The convulsions were often less severe and less frequent or disappeared entirely after pneumo-encephalography.

Hemiparesis and hemihypesthesia

The complaint of weakness or numbness on one side of the body was found in 27 cases and in the majority of these this symptom assumed a progressive course. On the other hand in some cases a story of remission of symptoms could be obtained and in a few instances in the early stages of the disease there were acute temporary exacerbations which suggested multiple sclerosis, a vasospastic or occlusive vascular process. Remissions in patients with brain tumors were relatively rare.

The other feature that we observed was that the degree of weakness or numbness described by the patient was rarely confirmed by examination. The patient felt that the numbness was far greater than could be actually demonstrated objectively. This was brought out by giving the patient a coin with his eyes closed and asking him to name the object and then the denomination. If the coin was placed in the affected hand he usually started immediately to feel it with the normal hand. If he was prevented from doing this, he would name the coin correctly by feeling it with the affected hand. On questioning he would say, "I didn't think I could name it with my bad hand" or "I always use my good hand to feel things." If the patient was not sure of loss of sensation it was found that when the right and left side of the body were stimulated simultaneously the patient in many cases would state immediately that the stimulus was less well perceived on the affected side.

On the motor side examination often showed varying degrees of loss of strength in the affected lower extremity, and this was associated with an increase of deep reflexes. The interesting feature, however, was the surprisingly high percentage (over 75 per cent) of cases of paresis of

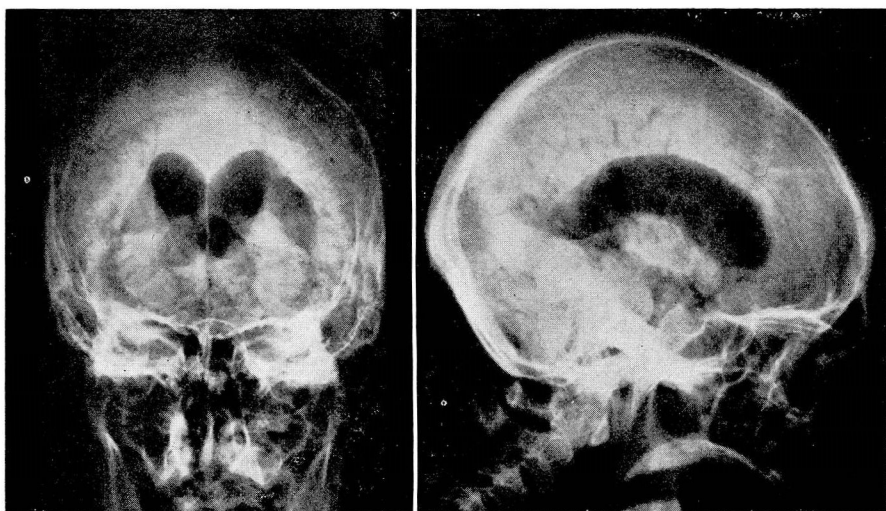


FIG. 3. Anteroposterior and lateral views revealing marked dilatation of the lateral ventricles with essentially normal cortical markings.

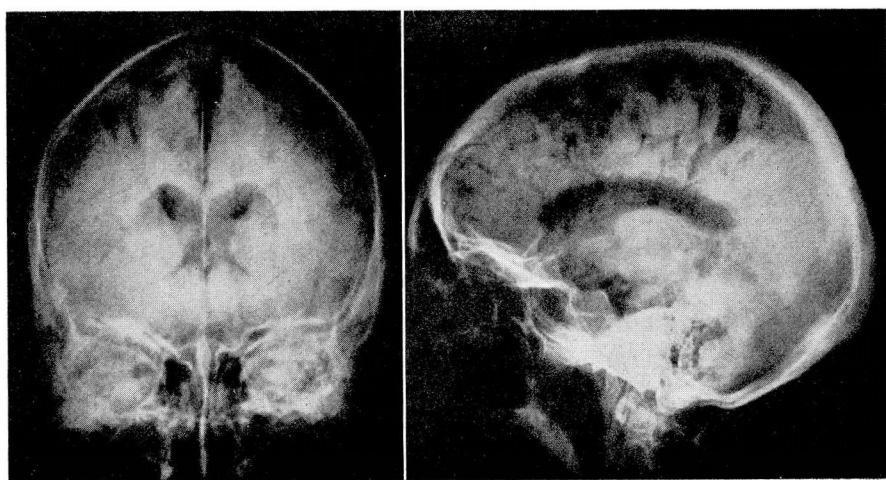


FIG. 4. Anteroposterior and lateral views showing diffuse increase of cortical markings and slight dilatation of the lateral ventricles.

the leg without a Babinski response or confirmatory responses such as are found in cases of brain tumor that involve the motor cortex or pyramidal tracts.

Discussion of Literature

The literature on brain atrophy is voluminous and no attempt will be made here to review it. Recently, an interesting paper on cortical atrophy was published in England that has a direct bearing on this report. Fleminger (1946)¹ described 28 cases of brain atrophy and discussed the differential diagnosis of brain tumor. Four of these patients had craniotomies and at operation "the cortex was shrunken and rubbery." There was microscopic evidence of cortical degeneration and sclerosis of unknown etiology, but in 2 cases it was observed that the greatest changes were in close proximity to the blood vessels. Seventy-five per cent of the cases of brain atrophy described by Jackson (1946)¹ had epilepsy, 25 per cent had a visual field defect and 50 per cent had headache of the hypotensive type.

Riley and Elsberg (1926)² and Gordon (1940)³ emphasized in the differential diagnosis of brain tumor and brain atrophy that the symptoms and signs in the latter condition are often remittent or intermittent and that they may be referred to both cerebral hemispheres.

Fay in 1930⁴ suggested that a hydraulic pressure mechanism might be responsible for the development of certain types of widespread atrophic degeneration of the brain in younger patients and in those without arteriosclerosis. He also presented encephalographic evidence to show that the frontal areas were involved most frequently and the anterior and upper part of the parietal region were next. In the majority of cases selected for this report the frontal and superior parietal regions were the areas of greatest predilection.

The occurrence of constriction of the peripheral vascular bed on the side of the body opposite the brain atrophy was stressed by Kerr and Underwood in 1936.⁵ Vegetative disturbances of this nature were encountered by us when coldness of the extremities with vasomotor changes were found in 11 of our cases.

Summary

In the 52 cases a brain tumor was suspected because of the occurrence of headache, convulsions or localized central nervous system symptoms.

The differences and the similarities of the headache, convulsions, and neurologic findings in brain tumor and brain atrophy have been

discussed. It has been pointed out that in many instances patients with atrophic brain disease had a different type of headache, a greater preservation of the sensorium than in brain tumor. On examination of the sensory and motor systems in cases of brain atrophy, the objective findings were definitely less marked than were the subjective symptoms. The pneumo-encephalograms showed a diffuse or localized atrophy, and in some cases improvement of signs and symptoms followed air injection. In a few recent cases interruption of the sympathetic nervous system impulses to the brain produced by stellate ganglion blocks, stellate ganglionectomy, or upper thoracic anterior rhizotomy has been of measurable value, although it is too early to state with any certainty that there will be lasting beneficial effects.

References

1. Jackson, H., and Fleminger, J. J.: Discussion on cortical atrophy. *Proc. Roy. Soc. Med.* **39**:423-430 (May) 1946.
2. Riley, H. A., and Elsberg, C. A.: Differential diagnosis between cerebral degeneration, infiltrating cerebral neoplasm, and infiltrating cerebral neoplasm with degeneration. *Arch. Neurol. and Psychiat.* **15**:48-74 (Jan.) 1926.
3. Gordon, A.: Cortical atrophy or tumor of brain: differential diagnosis. *J. Nerv. and Ment. Dis.* **91**:53-57 (Jan.) 1940.
4. Fay, T., and Winkelman, N.W.: Widespread pressure atrophy of brain, and its probable relation to function of paccionian bodies, and cerebrospinal fluid circulation. *Am. J. Psychiat.* **9**:667-685 (Jan.) 1930.
5. Kerr, W. J., and Underwood, F. J.: Hemiconstriction of vascular system associated with cerebral disease. *Am. Heart J.* **12**:713-723 (Dec.) 1936.