

GASTROCOLIC FISTULA: A NEW CONCEPT OF PATHOLOGIC PHYSIOLOGY; MECHANISM OF PRODUCTION OF THE SYNDROME*

ROBERT McKEE KISKADDON, M.D.,** FREDERIC E. TEMPLETON, M.D.,†
and R. JOHN F. RENSHAW, M.D.‡

The pathologic physiology in gastrocolic fistula has not been fully explored, and there are conflicting opinions as to the mechanism which produces the syndrome.^{1,2,3,4,5} Gastrocolic fistula does not occur frequently, but it is one of the most dreaded complications of surgical treatment for peptic ulcer. It may produce a devastating syndrome which includes diarrhea, weight loss, malnutrition, anemia, and steatorrhea.

Haller⁶ described the first case of gastrocolic fistula in 1755, and in 1903 Czerny⁷ made the first report of fistula following gastrojejunal ulcer. Voorhoeve⁸ collected 103 cases in the literature in 1912.

As the utilization of gastroenterostomy in the treatment of peptic ulcer increased the incidence of gastrojejunocolic fistula secondary to jejunal ulcer increased. Atwater, Butt, and Priestley⁹ reported that 11 to 14 per cent of gastrojejunocolic ulcers finally develop into gastrojejunocolic fistulae. In their series of 42 cases, 40 were secondary to gastrojejunal ulcer following surgical treatment of peptic ulcer, and 2 were the result of carcinoma. There are other causes for gastrojejunocolic fistula, but they are rare. These include tuberculosis, syphilis, ulcerative colitis, peritoneal abscess, trauma, and congenital deformities.

Direction of the flow of aliment has been the subject of much discussion. Earlier workers^{8,10} accepted fecal vomiting as evidence of a flow of colonic contents into the stomach. Other authors indicate that the flow is largely from the stomach to the colon. They believe that the shunting of food through the fistula from the stomach into the colon is a major factor in the production of the syndrome.^{4,9,11,12}

In 1920, Bolton and Trotter¹ made an important observation. They observed rapid improvement in the patient's condition after making a temporary cecostomy for treatment of gastrojejunocolic fistula. They stated, "It was also clear that the direction of flow was from the colon into the stomach and not vice versa, as no undigested food or excess of

*This is part of a thesis submitted by Dr. Kiskaddon in fulfillment of fellowship requirements and awarded the William E. Lower Prize.

**244 Lincoln Ave., Youngstown, Ohio. Former Fellow, Dept. of Medicine.

†Cobb Bldg., Seattle, Washington. Former Head of Dept. of Roentgenology.

‡1626 Bush Street, Santa Ana, California. Former Associate, Section on Gastrointestinal Disease.

fat was present in the faeces", and "The passage of the colonic content along the small intestine no doubt was responsible for the diarrhea."

Pfeiffer and Kent² reported similar observations on flow of aliment and the clinical improvement of the patient following colostomy proximal to the fistula. They believed that the diarrhea was caused by fecal irritation of the stomach and intestines. Mathewson⁵ also disagreed with the common concept that diarrhea was due to emptying of acid contents into the colon. Other authors reported clinical improvement in patients having other types of operations to prevent or interrupt the flow of fecal material to the fistulous region. Lahey and Swinton¹³ and Lahey and Marshall¹⁴ accomplished this result by "internal colostomy". Baker³ produced the same effect with ileostomy. The result of these procedures was not only improvement in the patient's condition but cessation of the diarrhea, although the fistulous communication between the colon and the stomach was still present. This evidence would suggest that a condition other than shunting of food from the stomach into the colon might be responsible for diarrhea and production of the syndrome.

The problem of steatorrhea in patients with gastrojejunal colic fistula was investigated by Strauss in 1921.¹⁵ After making extensive chemical analyses of the stools of 2 patients he concluded that there was poor absorption of fat in the presence of adequate secretion of pancreatic ferments.

Anemia has also been an interesting problem in cases of gastrojejunal colic fistulae. Although most of these patients have microcytic hypochromic anemia, a small percentage of them develop a macrocytic type. It is interesting in this connection to recall the hypothesis of Knud Faber¹⁶ concerning the mechanism and production of pernicious anemia in patients having strictures of the small intestine. He believed that gastric achylia permits bacterial growth in the stomach and duodenum, and as a result bacterial decay permits absorption of intestinal poisons which gave rise to pernicious anemia. Meulengracht^{17,18} reported 10 such cases and attributed the anemia to absorption of hemotoxic material through the damaged mucosa. Seyderhelm, Lehman, and Wichels¹⁹ made strictures in 10 dogs, 4 of which developed hyperchromic anemia. The authors also reported upper intestinal contamination with *Escherichia coli*. All this evidence suggested to us that in gastrojejunal colic fistula regurgitation of fecal contents through the fistula into the stomach might in some way damage the absorptive and digestive functions of the small intestine, thereby producing a sprue-like syndrome.

In the literature there are few references to morbid changes in the intestine in cases of gastrojejunal colic fistula.

In 1940, Colp²⁰ mentioned hypertrophy and injection of the stomach and jejunal mucosa, but there was no reference to histologic changes remote from the gastrocolic fistula.

Because of conflicting opinion and because shunting of food from the stomach into the colon did not seem to provide an adequate explanation for the syndrome, we reviewed the clinical records of 20 patients with gastroenterocolic fistula seen at Cleveland Clinic between February, 1921, and February, 1946. We made gastroenterocolic anastomoses in dogs to observe the findings and to compare them with those in human patients having similar communications between the stomach and intestines.

Clinical Study

Of the 20 patients with gastroenterocolic fistula 12 developed the fistula following operation for benign peptic ulcer. In 5 the fistula developed as a result of carcinoma. Two patients acquired fistulae as a result of perforation of a diverticulum of the colon. One was a duodenocolic communication and the other ileocolic. The twentieth patient had an ileocolic fistula of undetermined origin, but this was thought to be the probable result of perforated diverticulum of the colon. The 12 patients who developed fistula after operation for peptic ulcer were all men, their ages ranging from 37 to 57 years. In 9 patients the site of the primary ulcer was the duodenum, and in 3 instances the site of the primary lesion could not be determined from the available records.

In 8 of the 12 patients the primary operation was posterior gastroenterostomy. One had an anterior gastroenterostomy. It is significant that 1 patient had partial gastric resection. The types of operation upon 2 patients could not be determined from the records. The fistulae developed from two to twenty years after the original operation. Hollander and Mage²¹ state that complications of surgical treatment of peptic ulcer usually develop within one to five years after operation and rarely after ten years. In our series 6 of the 12 fistulae developed twelve or more years after the initial operation, and symptoms of the syndrome had been present from three months to five years.

The outstanding symptoms were diarrhea and loss of weight and strength. Diarrhea was the chief complaint in 11 of the 12 patients. One patient complained of persistent constipation. When diarrhea was present the stools were watery, foamy, and foul, but not voluminous. The number varied from three to fourteen stools daily. With but one exception the patients did not note undigested food in the stools. Diarrhea was usually the first symptom, and the associated symptoms of loss of

weight, avitaminosis, edema, and other features developed after diarrhea had become persistent. Eleven of the 12 patients had weight loss which varied from 5 to 50 pounds. Seven of these patients complained of marked loss of strength in association with loss of weight. Four patients complained specifically of foul or fecal odor to the breath, usually associated with belching or vomiting. Appetite, even in the presence of fecal odor to the breath, usually remained good. One patient stated that his appetite was excessive despite "constant fecal breath" and continuous weight loss.

The objective manifestations observed in the 12 patients with gastrocolic fistula following operation for benign peptic ulcer varied with the severity of the symptoms. In the early phase of an illness without remissions or in an illness of long duration but with intermittent symptoms the patient appeared to be in reasonably good health. In the more severe or advanced phases the patient appeared emaciated, dehydrated, and desperately ill. There were signs of multiple vitamin deficiency including night blindness, paresthesia, peripheral neuritis, cheilosis, glossitis, conjunctivitis, pellagra, achymosis, and tetany.

Biophotometer tests were done on 3 of our patients. Two had distinctly abnormal curves, while the third was within normal limits, although the patient complained of blurred vision for a period of one month prior to admission. Prothrombin time was measured in 2 patients and found to be normal. Isolated blood sugar determinations were normal. Two patients had glucose tolerance studies, and 1 revealed a dysinsulin type curve. Four of 12 patients had blood protein examinations, and all were below normal. Only 3 patients had bromsulfalein liver function tests, and in 1, using 5 mg. dye per kilogram body weight, there was 36 per cent retention of dye at the end of thirty minutes. Two patients had blood calcium and phosphorus determinations. One was normal and one was abnormal. The latter revealed 8.4 mg. of calcium per 100 cc. of blood and 2.5 mg. phosphorus per 100 cc. of blood. This patient complained of pain in the skeletal structures of three months' duration preceding admission to the Clinic. Roentgenograms of the spine revealed decalcification. None of the patients who had peptic ulcer developed anacidity with the fistulae. Diarrhea was the major complaint of all patients, but only 6 had recorded stool examinations. All 6 had steatorrhea, but serial studies in 2 patients revealed steatorrhea to be inconstant. Eleven of the 12 patients had blood examinations, 6 of which were normal. Four patients had normocytic hypochromic anemia, and one had anemia of an undetermined type. In several instances the patient had received liver and/or iron for anemia prior to admission to the Clinic.

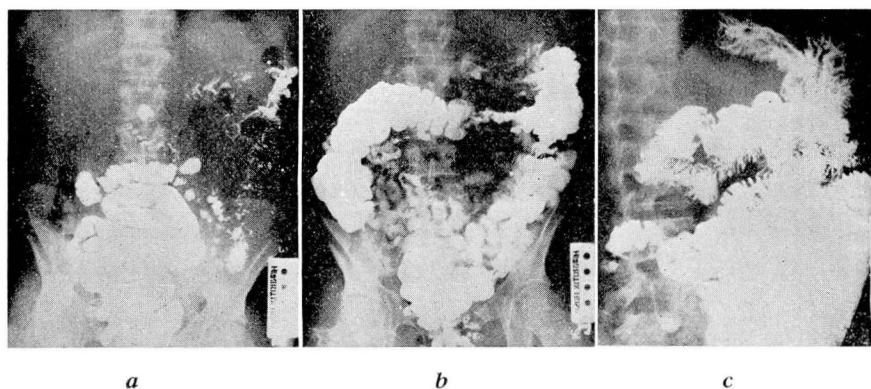


FIG. 1. Flow of barium meal in patient with gastrocolic fistula. Demonstrates regurgitation of colonic contents into stomach through fistula. (a) Two hours after meal. Barium fills upper intestine. (b) Five hours after meal. Stomach is empty. Barium is scattered throughout small intestine. Small traces of barium are in distal transverse and descending colon. This probably entered the colon directly from stomach. (c) Twenty-four hours after meal. Considerable barium remains in small intestine and colon, but there is more barium in stomach than at end of five hours, indicating regurgitation from colon through fistula into stomach.

A review of the roentgenologic material revealed that 8 patients who had developed fistulae following operation for peptic ulcer had sufficient evidence for analyses of direction of the flow of barium, motility, and change in small bowel pattern. Because we were concerned primarily with the direction of flow of aliment, 2 other patients with sufficient evidence for analysis of direction of flow are included in the discussion of the roentgenologic findings, although these 2 patients had fistulae as a result of carcinoma of the stomach which had perforated into the colon. Finally, the roentgenograms of 1 case observed elsewhere* are included in this part of the discussion because they demonstrated the phenomenon which we were able to observe in dogs with gastrocolic anastomoses and were not able to observe in our series of human patients (fig. 1).

In our analysis of the direction of the flow, orally ingested barium always passed through the pylorus or into the small intestine and thence into the colon through the ileocecal valve (fig. 2). The colonic fistula was shown in only 2 patients using the barium meal but was demonstrated in all 11 by administration of a barium enema. Furthermore, in 1 of the patients in whom much of the oral barium flowed through the fistula into the colon at one examination, at a later examination the entire aliment passed through the pylorus and did not enter the fistula (fig. 3). In most instances the stomach emptied rapidly, and the head of the meal progressed rapidly through the small intestine. However, it

*This patient was under the care of Dr. Leo Hardt, Chicago.

GASTROCOLIC FISTULA

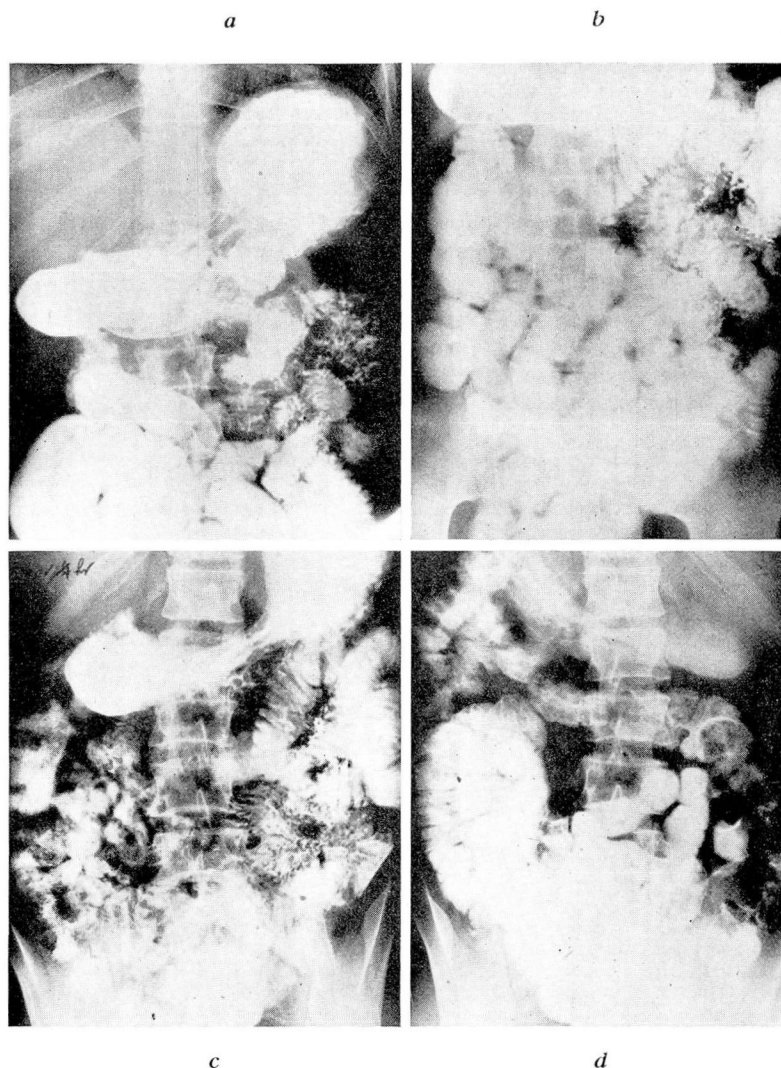


FIG. 2. Flow of barium meal in patient with gastrocolic fistula. (a) Fifteen minutes after meal. Stomach is well filled. Considerable barium has passed through pylorus, and only a trace outlines gastrocolic stoma. (b) One-half hour after meal. Barium is scattered through small intestine, but none has passed ileocecal valve. There is no apparent increase of barium entering transverse colon through fistula. (c) One and one-half hours after meal. Stomach still contains considerable barium. Head of meal has reached hepatic flexure, but bulk of meal is scattered through small intestine or remains in stomach. Still only a very small part of meal has passed through fistula. (d) Three and one-quarter hours after meal. Small amount of barium remains in stomach. Head of meal has reached splenic flexure, but bulk of meal still remains scattered throughout small intestine.

is significant that serial observation revealed barium scattered throughout the large and small intestine for long periods after the administration of a barium meal, even though the barium *head* progressed rapidly through the intestines (fig. 2). Similarly, barium administered by enema was observed scattered throughout the small intestine for long periods after regurgitation into the stomach. Abnormalities in pattern of the mucosa of the small intestine, commonly called "deficiency state" or "deficiency pattern", were found in 6 of the 11 patients.

Microscopic study of tissue was limited to specimens of stomach and intestine from the region of the fistula. In 2 instances chronic inflammation of the jejunal and gastric mucosa was recorded.

The treatment advised in the series of 12 patients with fistula following operation for benign peptic ulcer was reoperation for correction of the fistula. Eight of the 12 patients had corrective operations at Cleveland Clinic, and there were no operative or hospital deaths. The preoperative treatment consisted of such general supportive measures as low residue diet, supplemental oral and parenteral vitamins, whole blood transfusions, and the use of the intravenous and subcutaneous saline dextrose solutions. Protein hydrolysates, sulfonamides, or penicil-

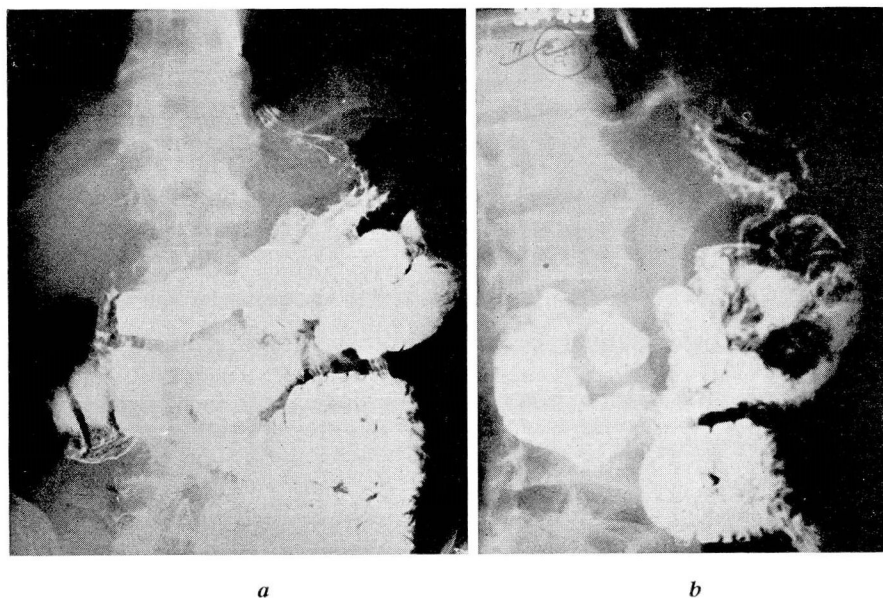


FIG. 3. Flow of barium meal in patient with gastrocolic fistula. (a) During one examination some barium passed directly from stomach to colon through fistula, although considerable amount also passed through pylorus into small intestine at the same time. (b) At a later examination of same patient only a very small part of meal passed through the fistula, while nearly all passed through the pylorus.

lin were not available for the patients operated upon in earlier years, and the illness of those operated upon in recent years was not of sufficient gravity to require use of the drugs.

Experimental Study

Experiments on 7 dogs are the basis for this part of the report, although additional dogs with various types of operations are under observation. All animals were kept on a standard diet of Purina Chow Dog Food, supplemented twice weekly with one-half pound of ground horse meat. During the preoperative control period observations were made on weight, appetite, general behavior, blood count, stools, and roentgenologic appearance of the gastrointestinal tract.

Four dogs had gastrocolic fistulae, 1 had an anterior gastrojejuno-colic fistula, 1 had a posterior gastrojejuno-colic anastomosis, and 1 had a duodenocolic communication. In all but 1 the artificial stoma was 3 to 4 cm. in diameter. The last dog had a gastrocolic fistula with a stoma only 1 cm. in diameter and one year after operation has not developed the syndrome.

After operation the dogs appeared to pass through four stages of the syndrome when the stoma was large enough for the syndrome to develop. They remained healthy for three to nine months postoperatively. The smaller the stoma the longer time required for development of the syndrome, as evidenced by the 1 dog with a 1 cm. fistula. After this first stage, which might be called the "latent period", the second stage developed. It was characterized by weight loss and microcytic normochromic anemia. The third phase included intermittent diarrhea and steatorrhea, more marked anemia, and early inflammatory changes in the gastrointestinal tract. The fourth or last stage was characterized by persistent diarrhea and steatorrhea, severe malnutrition, striking inflammation with some ulcerative changes in the gastrointestinal tract, and progression of anemia. In 2 dogs the anemia became definitely macrocytic hyperchromic.

Diarrhea developed in all but 1 dog (the animal with 1 cm. stoma). The fistula in this animal was "functionally closed", but under slight pressure part of a barium enema passed through the fistula into the stomach. (Postmortem examination sixteen months after operation revealed a valve-like flap of tissue which during life prevented flow of material either way.) Diarrhea was intermittent in the earlier stage of the syndrome. Stools were light in color, watery, and foul. Steatorrhea was demonstrated in 5 dogs. The severity of steatorrhea corresponded to the severity of diarrhea.

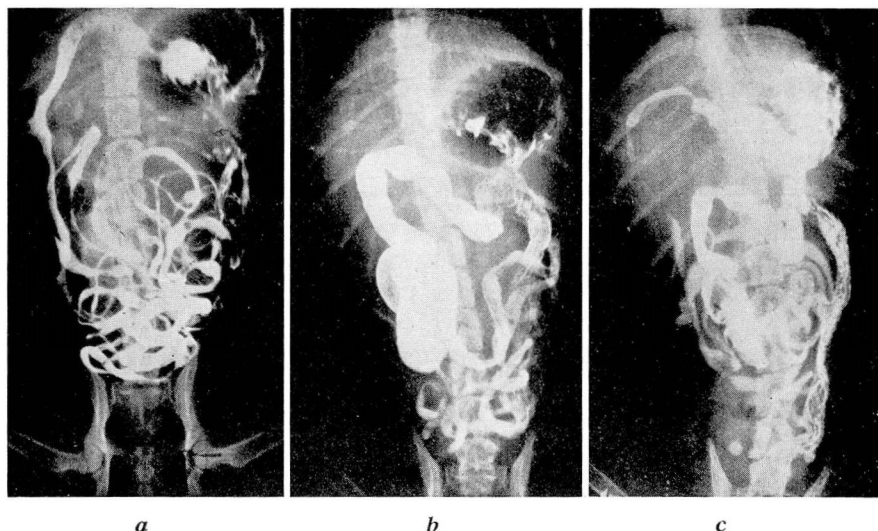


FIG. 4. Flow of barium meal in dog with gastrocolic anastomosis 4 cm. in diameter. (a) Fifteen minutes after meal. Barium is passing through pylorus. Duodenum is well-filled, and barium is scattered through normal small intestine. (b) One and one-half hours after meal. Head of meal is in transverse colon, but large amount remains in small intestine. Fistula is faintly outlined, and small amount of barium dimly outlines descending colon. Stomach is almost empty. (c) Three and one-half hours after meal. Considerable barium remains in small intestine, but portion of colon shown filled in 4(b) is partly empty, and the stomach contains much more barium. Colonic contents have been regurgitated into stomach.

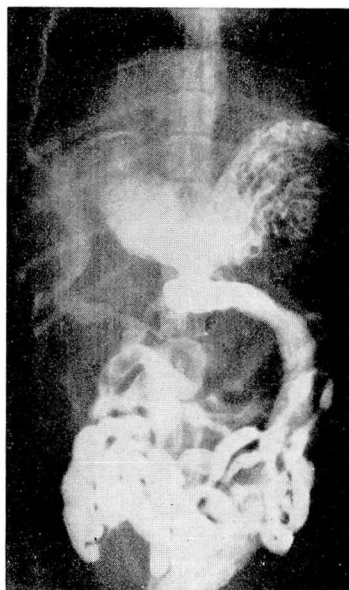


FIG. 5. Flow of barium meal in dog with gastrocolic fistula 4 cm. in diameter. Much of meal has passed directly into colon, although at the same time considerable amount has passed through pylorus.

All but 2 dogs had ravenous appetites throughout their illness. The measured amount of food ingested by the 2 dogs without ravenous appetites was still adequate to maintain normal nutrition. Yet in the third and fourth stages of the syndrome all dogs developed malnutrition, loss of weight, dehydration, conjunctivitis, xerophthalmia, glossitis, dry atrophic tongue, and roughing of coat with patchy loss of hair. Thus the dogs developed a syndrome comparable to that in human beings with gastrocolic fistula.

Roentgenologic studies revealed that orally administered barium always passed through the pylorus or stoma into the upper small intestine and from the small intestine through the ileocecal valve into the cecum (fig. 4). However, the amount which went this way was variable. In 3 dogs the entire barium meal left the stomach through the pylorus. In 4 dogs the barium entered the small and large intestine simultaneously through the pylorus and the fistula. However, in 3 of these 4 dogs almost the entire meal passed through the pylorus, while in only 1 dog did the amount leaving through the fistula equal that going through the pylorus. The latter dog passed a stool containing barium one-half hour after administration of the meal, but considerable barium remained in the small intestine two and one-half hours later (fig. 5). Another examination of this same dog at a later date revealed that the entire meal advanced into the small intestine, and none entered the colon through the fistula.

Regurgitation of orally administered barium from the colon into the stomach was observed in 2 dogs. In one instance it was observed during fluoroscopy (fig. 4) and once during gastroscopy.

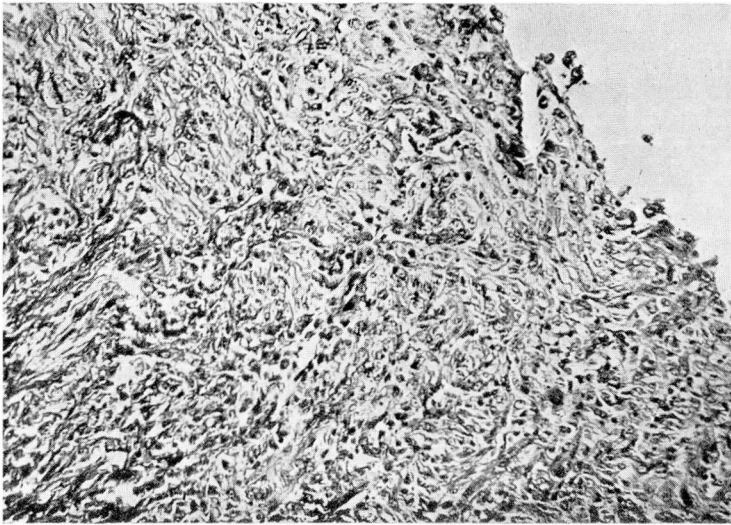
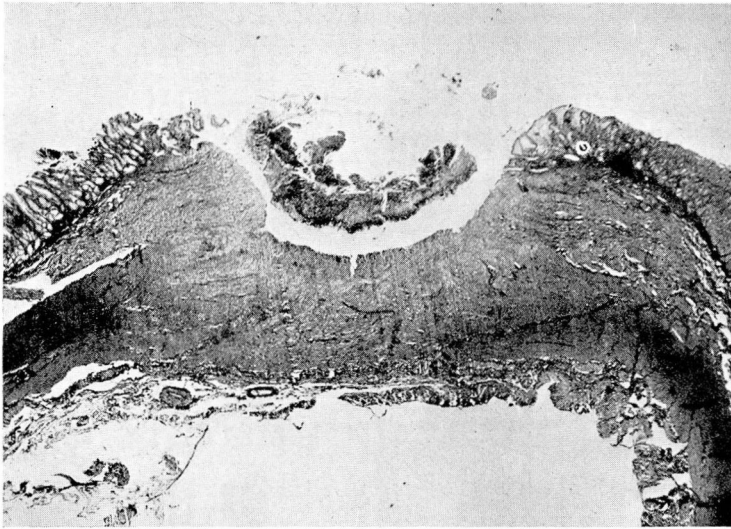
Fourteen dogs were studied to observe the "normal" small bowel pattern. After operation the only change associated with malnutrition and hypoproteinemia which we could observe was dilatation of the intestine. Segmentation, "puddling" of barium, and other signs observed in human patients and described as "deficiency patterns" were not seen in the dogs. There was suggestive evidence of hypomotility in these animals.

Two dogs were observed by gastroscopy. In both animals there was catarrhal inflammation of the stomach. In 1 dog, stool coming through the fistula into the stomach was observed.

Pathology

Six dogs had postmortem studies. In 5 instances the gastroenteric or gastrocolic stoma measured 3 to 4 cm. in diameter, the other one measuring only 1 cm. and having a valve-like flap of tissue covering

a



b

FIG. 6. Gastric ulcer in dog with gastrocolic anastomosis. (a) Low power. (b) High power shows evidence of chronicity and organization.

the stoma. The changes in the stomach of those animals which died or were killed in the early phase of their illness varied from normal to mild catarrhal or such superficial inflammation. Two dogs whose illness was more prolonged developed gastric ulcers (fig. 6). The surface layer of

the ulceration consisted of necrotic tissue and exudate. The latter consisted of lymphocytes, polymorphonuclear leukocytes, and occasional plasma cells. Under the surface layer there was a layer of organization showing fibroblastic proliferation with young blood vessels and infiltrated with lymphocytes and a few polymorphonuclear leukocytes. The inflammatory changes extended into and partly involved the muscularis. The rest of the stomach showed little change.

In the small intestine there was diffuse patchy hyperemia of the small intestine. It was more marked in the duodenum and upper jejunum, becoming less severe in the lower portion of the small intestine. The colon showed no change. In the small intestine the changes were limited to the papillae where there was a striking increase in the cellular elements (fig. 7). The inflammatory infiltration consisted of lymphocytes and plasma cells, a subacute to chronic type of change limited almost exclusively to the mucosa. There was some fibrosis of the tunica propria of the mucosa in the papillae.

Summary

1. A review of the literature reveals conflicting opinions regarding the mechanism which produces the syndrome following development of gastrocolic fistula.

2. The outstanding symptom was diarrhea, although 1 of 20 patients had constipation. Diarrhea might be intermittent, especially in the early stages of illness.

3. Steatorrhea roughly paralleled diarrhea in frequency and intensity.

4. Weight loss, polyavitaminosis, and malnutrition developed after diarrhea and steatorrhea had become fairly constant.

5. Eleven of 20 patients had roentgenologic studies sufficient for detailed study. In all 11 patients barium passed from the stomach into the upper small intestine, but in only 2 instances did barium pass from the stomach into the colon through the fistula.

6. In all 11 patients the fistula was demonstrated roentgenologically by administration of a barium enema.

7. The *head* of the barium meal passed rapidly through the small intestine, but for long periods after administration barium remained scattered through the small intestine. Similarly, barium which regurgitated into the stomach after being administered by enema remained scattered throughout the small intestine for long periods afterward.

8. In 1 patient with gastrojejunocolic fistula the barium meal passed through the pylorus and the fistula. Twenty-four hours later most of the barium was still scattered through the small intestine and colon.

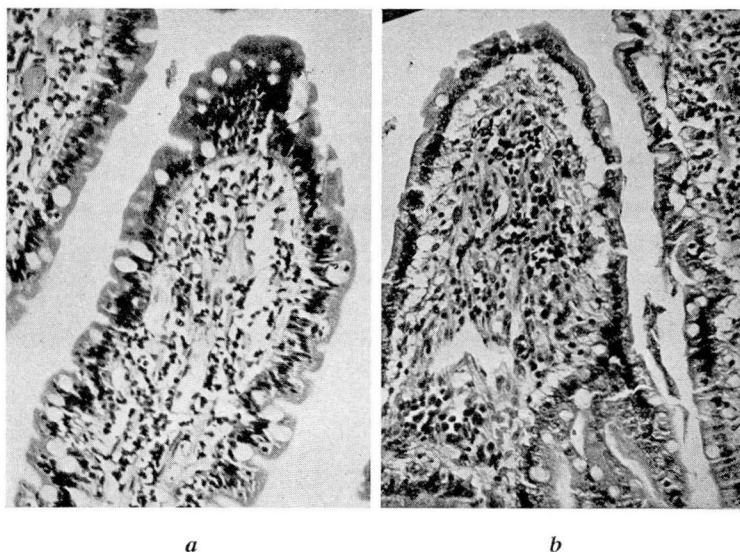


FIG. 7. Small intestine of dog with gastrocolic anastomosis 4 cm. in diameter. (a) Typical normal papilla before making gastrocolic anastomosis. (b) After anastomosis and after development of syndrome there is a striking increase in cellular elements. The inflammatory reaction is a subacute to chronic type limited almost exclusively to mucosa.

The stomach contained more barium at the end of twenty-four hours than at the end of five hours, indicating regurgitation through the fistula into the stomach.

9. Five dogs which were killed during the course of the syndrome, or which died as a result of the syndrome, showed inflammatory changes in the stomach. Two dogs showed gastric ulceration with evidence of organization and some degree of chronicity. In the small intestine, especially the upper third, there was a striking subacute to chronic type of inflammatory infiltration limited almost exclusively to the mucosa of the papillae.

10. The development of anemia presented an interesting observation and warrants further study. It is suggested, although our studies were inadequate, that the development of anemia follows a definite pattern. The first change is to hypochromic microcytic anemia in the earlier phases of illness. If the animal is not too sick and survives long enough, the anemia tends to become macrocytic hyperchromic.

Conclusions

Tentative conclusions based on the above evidence and observations of others are: ^{2,6,7,8,11}

1. Sufficient aliment to maintain adequate nutrition passes from the stomach into the upper small intestine.
2. Passage of aliment directly from the stomach into the colon is not frequent enough nor in large enough amounts to cause the syndrome.
3. Deranged digestive and absorptive functions of the small intestine cause the syndrome.
4. Colonic contents regurgitate through the fistula into the stomach.
5. Derangement of small intestine function is probably the result of damage to the intestinal mucosa caused by the passage of colonic contents through the small intestine.

References

1. Bolton, C., and Trotter, W.: Jejuno-colic fistula following gastrojejunostomy. *Brit. M. J.* **1**:757-762 (June 5) 1920.
2. Pfeiffer, D. B., and Kent, E. M.: Value of preliminary colostomy in correction of gastrojejunocolic fistula. *Ann. Surg.* **110**:659-668 (Oct.) 1939.
3. Baker, J. W.: Ileostomy preliminary to resections of gastrojejunocolic fistula. *North-west Med.* **39**:398-403 (Nov.) 1940.
4. Best, C. H., and Taylor, N. B.: *The Physiological Basis of Medical Practice*, ed. 4 (Baltimore: The Williams & Wilkins Co., 1945).
5. Mathewson, C., Jr.: Preliminary colostomy in management of gastrocolic and gastrojejunocolic fistulae. *Ann. Surg.* **114**:1104-1110 (Dec.) 1941.
6. Haller, A.: *Opuscula Pathologica*. 1755.
7. Czerny, V.: Zur Behandlung der Fissur und des Vorfalls, des Mastdarms. *Beitr. z. klin. Chir.* **37**:765-769. 1903.
8. Voorhoeve, N.: Die klinische und radiologische Diagnose der Fistula gastro-colica. *Deutsches Arch. f. klin. Med.* **106**:294-308. 1912.
9. Atwater, J. S., Butt, H. R., and Priestley, J. T.: Gastrojejunocolic fistulae, with special reference to associated nutritional deficiencies and certain surgical aspects. *Ann. Surg.* **117**:414-426 (March) 1943.
10. Riegel, F.: *Die Erkrankungen des Magens*. *Nothnagels Handbuch der speziellen Pathologie und Therapie*. **16**:500. 1897.
11. Ransom, H. K.: Gastrojejunocolic fistula. *Surgery* **18**:177-190 (Aug.) 1945.
12. Collier, F. A.: Discussion of ref. 2. *Ann. Surg.* **110**:666-667 (Oct.) 1939.
13. Lahey, F. H., and Swinton, N. W.: Gastrojejunal ulcer and gastrojejunocolic fistula. *Surg., Gynec. & Obst.* **61**:599-612 (Nov.) 1935.
14. Lahey, F. H., and Marshall, S. N.: Surgical management of some of the more complicated problems of peptic ulcer. *Surg., Gynec. & Obst.* **76**:641-648 (June) 1943.
15. Strauss, H.: Fat stools as symptoms of gastrocolic fistula. *Berl. klin. Wchnschr.* **58**:661-662 (June 20) 1921.
16. Faber, K.: Achylia gastrica mit Anämie. *Med. Klin.* **5**:1310. 1909.
17. Meulengracht, E.: Stenosis of intestine and pernicious anemia. *Acta med. Scandinav.* **56**:432-442 (April) 1922.
18. Meulengracht, E.: Stricture and pernicious anemia. *Arch. f. Verdauungskr.* **28**:216 (Sept.) 1921.
19. Seyderhelm, R., Lehman, W., and Wichels, P.: Intestinale perniziöse Anämie beim Hund durch experimentelle Dünndarmstriktur. *Krankheitsforschung* **4**:263-279 (May) 1927.
20. Colp, R.: Gastro-jejuno-colic fistula; preliminary colostomy with spontaneous healing of transverse colonic fistula. *J. Mt. Sinai Hosp.* **7**:194-198 (Nov.-Dec.) 1940.
21. Hollander, F., and Mage, S.: Statistical method for evaluating results of treatment for peptic ulcer. *Surg., Gynec. & Obst.* **76**:533-546 (May) 1943.