

GIANT URETHRAL CALCULUS

C. C. HIGGINS, M.D., and K. F. HAUSFELD, M.D.

Department of Urology

THE occurrence of calculi within the male urethra is uncommon. LeComte¹ encountered this condition seven times in a series of 2900 urologic cases. Debenham² reported 40 cases of urethral calculi admitted to the London Hospital from 1910 to 1930, 3 patients being women and 37 men. Kini³ found only 1 case of calculi among 102 patients with stricture of the male urethra.

Urethral calculi are classified as primary or autochthonous and secondary or migratory calculi, depending on their site of origin. Autochthonous calculi occur more rarely and are usually formed in the urethra behind some obstruction or diverticulum. Secondary calculi are formed in other parts of the urinary tract and migrate to the urethra. Differentiation between autochthonous and secondary calculi may be difficult. According to Culver,⁴ Legueu believed that every urethral calculus originated in the kidney or bladder and became urethral secondarily. Stevens⁵ admits that autochthonous calculi are less common than secondary calculi and that their formation depends upon certain abnormal local conditions such as stricture, congenital or acquired dilations, diverticula, and prostatic hypertrophy. The recent work of Wilson, Benjamin, and Leahy⁶ demonstrating the production of urethral calculi in newborn rats by injection of estradiol raises the question of endocrine influence upon urethral calculi.

Most authors agree that migratory stones have a nucleus of uric acid or calcium oxalate, while autochthonous stones are phosphatic in composition and uniform in structure, being formed in infected urine.^{7,8,9}

Case Report

A man, aged 66, was admitted to the Cleveland Clinic on August 11, 1947, complaining of frequency of urination for one year. Past history revealed that in 1911 he had fallen from a crane into some steel castings and had sustained a fractured pelvis with rupture of the urethra. He was treated with a suprapubic cystotomy and an indwelling urethral catheter. No postoperative treatment was instituted, and in 1915 he had developed a urethral stricture, had had a perineal urethrotomy, which was followed by formation of stricture, and a second perineal urethrotomy in 1930. Since July, 1946, he had had hourly frequency of urination. The family physician had been unable to introduce a catheter into the bladder and had made a diagnosis of carcinoma of the prostate.

Physical examination revealed a well developed and fairly well nourished obese white man, 69 inches in height and weighing 198 pounds. He walked with a limp to the right. The chest and heart were normal, and the blood pressure was 130 systolic, 80 diastolic. On abdominal examination a mass was palpated from the symphysis pubis to just below the umbilicus. Anterior to the mass a well-healed scar was present. The left testicle was absent. Rectal examination revealed a few external thrombotic hemorrhoids. There was a grade II enlargement of the prostate which seemed to be stony hard, fixed, and nodular, yet slightly tender to palpation. Multiple scars were present in the midperineum.

A filiform was introduced into the bladder but a number 8 follower could not be admitted because of obstruction in the prostatic area.

Examination of the urine showed a specific gravity of 1.012, alkaline reaction, a trace of albumin but no sugar. Microscopic examination demonstrated numerous red and white

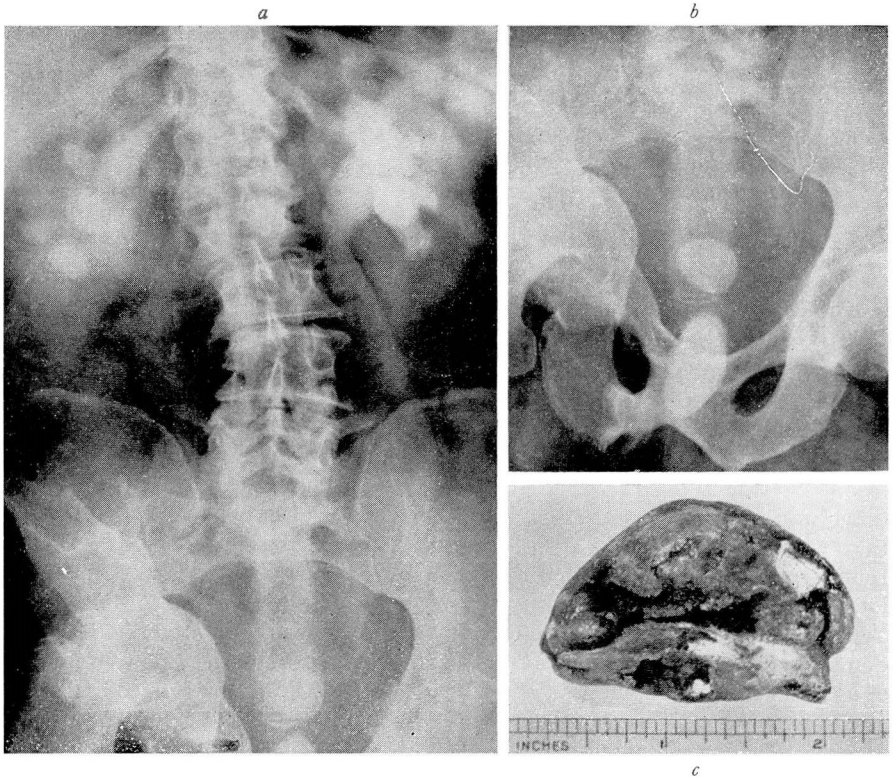


FIG. 1. (a) Bilateral hydronephrosis with calculus in bladder and urethra; (b) Calculus in bladder and large calculus in urethra; (c) Photograph of urethral calculus.

blood cells per high power field. *Bacillus coli* and *Streptococcus faecalis* were cultured from the urine. The blood count disclosed 4,720,000 red cells, 6050 white cells, and 12.5 Gm. of hemoglobin. Blood urea was 42 and sugar 110 mg. per cent three hours postprandially. The Wassermann and Kahn reactions were negative. Acid phosphatase was .8, and alkaline phosphatase was 1.8 Bodansky units.

Roentgenologic examination of the kidneys, ureters, and bladder showed no disease process in the kidneys or ureters. There were pronounced hypertrophic arthritic changes throughout the lumbar region of the spine and partial protrusion of the right femoral head into the pelvis. There was evidence of an old healed fracture of the right pelvic bone. A large calculus was present in the bladder and a second large calcification overlying the symphysis, partially in the bladder or urethra, was seen (fig. 1 a & b). An intravenous pyelogram showed prompt function from both kidneys, but both kidneys were hydronephrotic. The left ureter was dilated throughout its entire course.

The patient was admitted to the hospital, and on August 18, 1947, an internal urethrotomy was performed, severing strictures from the bulbous urethra to the meatus. Convalescence was uneventful, and on August 20, 1947, a suprapubic cystolithotomy was performed. After the bladder was opened and the calculus removed the internal meatus was dilated. A calculus was then palpated in the urethra. The anterior aspect of the vesical neck was incised, and a large calculus lying in the prostatic bed was extracted (fig. 1c). A number 18 soft rubber catheter was then easily introduced into the bladder. Convalescence was uneventful, and the patient was discharged from the hospital on September 10, 1947. At the

time of discharge he was voiding normally, but some pyuria was still present. Rectal examination revealed a grade I enlargement of the prostate. The stony hard area had disappeared.

Upon laboratory analysis of the calculus the specimen consisted of one tan and brown stone measuring 5 x 3 x 2.5 cm. The surface was smooth, the contour irregular. The interior was cream colored and striated, showing several darker tan striations. It was positive for nitrogen, ammonium, and phosphates.

Comment

Although the patient was referred to the Clinic with a diagnosis of carcinoma of the prostate, this error in diagnosis was understandable. Because of the anterior urethral strictures, no instrument could be passed into the bladder and the diagnostic "metal click" could not be elicited with the filiform. Rectal examination was not diagnostic, as the mass was not movable and no crepitus could be elicited. The history of trauma, previous perineal surgery, normal acid and alkaline phosphatase units, and positive roentgenologic findings led to the presumptive diagnosis of urethral calculus, which was confirmed at operation.

From reports of similar cases in the literature, it is apparent that trauma to the urethra followed by stricture formation is a salient point in the etiology of posterior urethral calculi. This is exemplified by case reports of Bertin,¹⁰ Miller,¹¹ and others.^{12,13}

References

1. LeComte, R. M.: Urethral stones. *Ann. Surg.* **89**:400-403 (March) 1929.
2. Debenham, R. K.: Urethral calculi. *Brit. J. Urol.* **2**:113-121 (June) 1930.
3. Kini, M. G.: Urethral pouch with multiple calculi. *Brit. J. Urol.* **11**:155-157 (June) 1939.
4. Legueu; cited by Culver, H.: Primary posterior urethral calculi. *Tr. Am. A. Genito-Urin. Surgeons* **32**:337-346, 1939.
5. Stevens; cited by Culver, H.⁴
6. Wilson, J. G., Benjamin, J. A., and Leahy, A. D.: Study of experimental urinary calculi; methods for producing and preventing calculous formation in bladder and urethra of albino rats. *J. Urol.* **54**:503-515 (Dec.) 1945.
7. Beilin, L. M., and Grueneberg, J.: Giant urethral calculus. *J. Urol.* **52**:596-598 (Dec.) 1944.
8. D'Offay, T. M. J.: Large calculus of urethra. *Brit. M. J.* **2**:911 (Nov. 4) 1939.
9. Graham, J.: Autochthonous urethral calculus. *Brit. M. J.* **2**:1085 (Nov. 26) 1938.
10. Bertin, E. J.: Unusual urinary calculi; brief review of literature and report of 6 cases. *Am. J. Roentgenol.* **55**:181-188 (Feb.) 1946.
11. Miller, A.: Large calculi in posterior urethra; report of 2 cases. *Lancet* **1**:1263-1264 (June 3) 1939.
12. Brooksher, W. R.: Urethral calculi. *Am. J. Roentgenol.* **28**:801-802 (Dec.) 1932.
13. Thomas, W. H.: Unique example of urethral calculus. *Aug. & Cutan. Rev.* **43**:542-543 (Aug.) 1939.