

# CONTACT X-RAY THERAPY FOR SUPERFICIAL LESIONS

U. V. PORTMANN, M.D.

Department of Therapeutic Radiology

**B**IRTHMARKS, keratoses, keloids, warts, local recurrences from cancer of the breast, superficial epitheliomas, and many similar accessible lesions can be quickly and successfully treated with "contact" x-ray apparatus. These conditions also have been treated with caustic chemical agents, surgical procedures with cautery or scalpel, radium, and higher voltage x-rays. During the past eight years contact x-ray therapy has been preferred at the Cleveland Clinic because of several advantages over these methods.

The apparatus (fig. 1) employed was developed by Chaoul in Berlin primarily as a substitute for radium in the treatment of accessible lesions. Its effectiveness depends upon the design of the x-ray tube. The tube is constructed so that the source of the rays (focal spot) is near (2.0 cm.) the opening through which the rays are emitted. Because of this a large quantity of rays is produced (8500 r per minute, no filter), and since the apparatus is operated at low voltage (50 K.V.) the rays have minimal penetrability (20 per cent at 1.0 cm. depth).

The advantages of this method of treatment over others are:

1. The quantity of rays produced is so great that treatment can be given in a few seconds or a minute or two. This is particularly helpful when treating children.




FIG. 1. Contact x-ray apparatus. The apparatus is mobile. The nozzle-like x-ray tube can be fixed on brackets or removed to hold in hands. Cones fit over end of tube.

2. As penetrability of the rays is minimal there is no serious damage to underlying tissues, therefore there is little scar formation. This is particularly beneficial when treating lesions on the face, about the eyes, over cartilages of the nose or ear, and epiphyses, which may be damaged by radium or higher voltage x-rays.

3. The rays can be localized with cones having openings of various sizes and shapes so that tissues adjacent to the lesions are not damaged.

4. Treatment is painless as compared with caustic agents or surgical procedures.

5. This method eliminates the necessity of handling radium, prolonged or careless use of which may cause damage to the radiologist.

6. Treatments can be given at low cost.

### Birthmarks

Birthmarks, or hemangiomas, have been classified by dermatologists as nevus flammeus, nevus vasculosus, and angioma cavernosum.

**Nevus flammeus**, or "portwine" mark (fig. 2), usually occurs on the face and neck but may develop on any part of the body. These nevi vary in color from bluish-red to purple and in size from a few millimeters to 6 or more centimeters in diameter. They are not elevated above the surface of the skin. Some may fade, but most persist. Unlike other vascular nevi, the vessels of which they are composed are mature, consequently they do not respond to irradiation. Small ones in children may respond to irradiation, but those in adults do not, in which case we advise the use of a covering cosmetic.

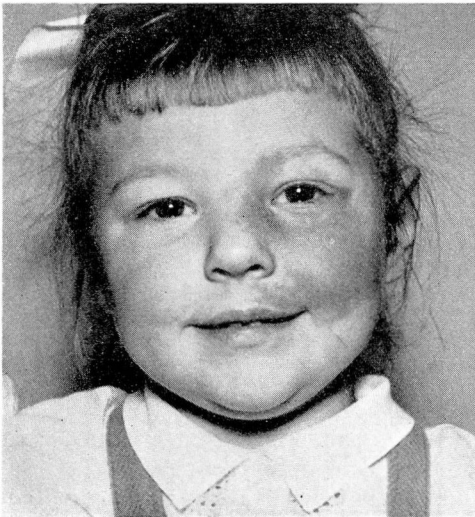

FIG. 2. Nevus flammeus. Does not respond to treatment.

**Nevus vasculosus**, or “strawberry mark” (fig. 3), is a red or mottled soft mass of small immature vessels. The nevi are elevated above the level of surrounding skin. They vary in size from a few millimeters to 8 or more centimeters in diameter.

**Angioma**, or **nevus cavernosum** (fig. 4), is composed of somewhat larger and deeper vessels than nevus vasculosus. These are soft tumors over which the skin may be normal in color or have a bluish tinge from vessels beneath. Nevus vasculosus is frequently present also in the skin over the tumors. The mass of angioma cavernosum is usually only slightly elevated above the level of surrounding skin. These tumors may not be manifest until several months after birth, and they rarely develop after adolescence. They occur most frequently on the cheeks, scalp, chest, and back and occasionally involve the tongue and other mucous membrane areas. Some undergo spontaneous regression, but deep ones may persist.

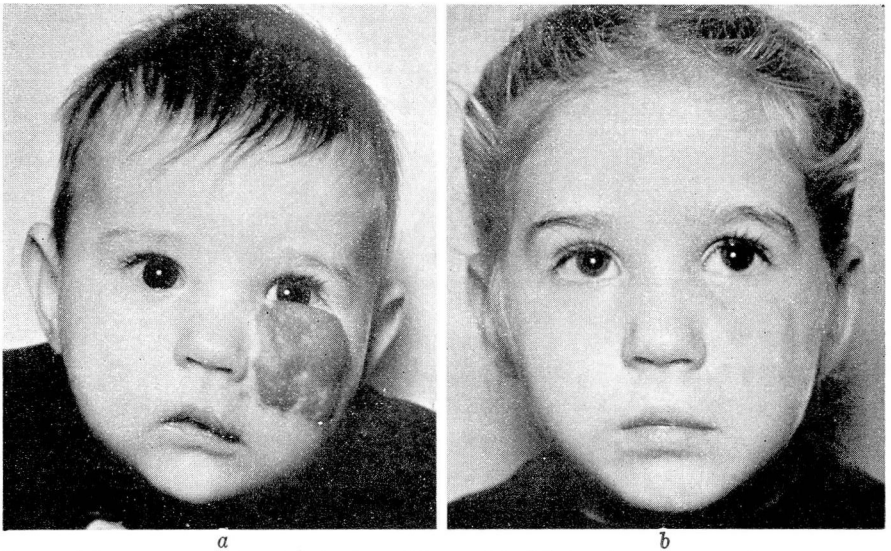

FIG. 3. (a) Nevus vasculosus of cheek and lower lid. (b) Result two years after treatment. No damage to eye or epilation of lid.

Treatment is indicated for both nevus vasculosus and cavernosum because some may not undergo complete involution, traces persisting to adult life. It is also indicated because of the psychologic effect of the unsightly lesions on parents and others.

Gratifying results have been obtained with contact x-ray therapy. There is no necessity for surgical operations. A treatment with contact x-ray can be given in a few seconds, is painless, and there is no damage to underlying or neighboring structures and no subsequent reaction. It is particularly advantageous for angiomas involving eyelids (fig. 5) because the rays usually can be directed away from the eye so that it is seldom necessary to cover the eyeball with lead shields. The anterior chamber of the eye of children is sensitive to irra-



diation, and opacities of the lens may be produced from relatively small quantities, as may result from radium therapy. Also, epiphyses may be damaged by radium or higher voltage x-ray so that bone growth is delayed when such methods are used to treat lesions overlying them. This result is unlikely with contact x-ray therapy because of the low penetrability of the rays and minimal quantity reaching to the depth of the epiphyses.

Treatments may be started when a child is a few months old and are usually given at monthly intervals until improvement or blanching is noticeable. Improvement is generally evident after about four applications, although some cases require a few subsequent treatments every two to four months. We prefer this method of prolonged treatment with relatively small doses, as we formerly used with radium, because there is no danger of ulceration or scar. The usual dose is 300 r with 1.0 mm. A1 filter at 2.1 cm. distance. For deeper



FIG. 4. (a) Angioma cavernosa of orbit and upper eyelid. (b) Result three years after treatment. No damage to eye or epilation of lid.

lesions thicker filter (2.5 mm. A1) and greater distance (4.0 cm.) may be necessary.

**Senile keratoses and seborrheic keratoses** may be single or multiple, gray or brown, flat or slightly raised, horny, crusted lesions developing on exposed skin surfaces or lips, especially in individuals susceptible to actinic rays. Such lesions are dangerous, as they tend to become epitheliomas. Contact x-ray therapy is ideal for treatment. We usually give 2000 to 4000 r unfiltered rays at one treatment, which takes fifteen to thirty seconds. Erythema reaction develops in about eight days, followed by scab formation and healing in about four weeks.

**Keloids** may develop spontaneously (idiopathic) or in scars (hypertrophy).

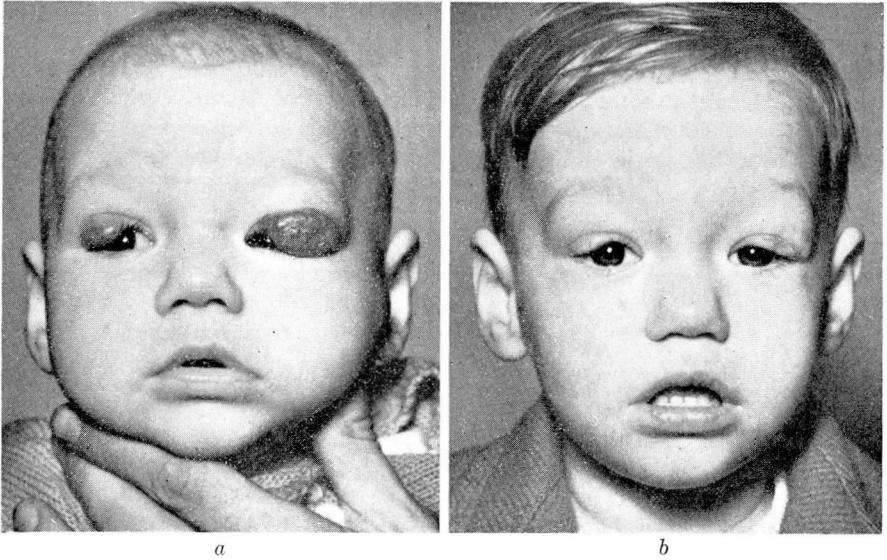


FIG. 5. Hemangioma of both eyelids and result after one year of contact x-ray therapy without damage to eyes.

Some persons, especially of the colored race, are prone to develop keloids following wounds or on the scars of acne. They are occasionally seen following operations for goiter in patients who do not otherwise develop them. Keloids may be painful. Surgical removal is seldom successful because keloid formation usually recurs. In treatment with contact x-ray, the surrounding skin is protected by lead and the lesions given 300 to 400 r (filter 1.0 mm. A1) at monthly intervals. The number of treatments necessary depends upon the size of the keloid. The cosmetic results are satisfactory, and there is no recurrence. Prophylactic irradiation is indicated following operations on persons with a tendency to develop keloids.

**Warts** (*verruca vulgaris*), usually occurring on the hands, and plantar warts (*verruca plantar*), occurring on the feet, are due to a virus infection. They have been reproduced experimentally by subcutaneous injection of material from the base of warts. Those that appear on the hands yield most satisfactorily to contact x-ray therapy. One treatment of 1500 to 3000 r without filtration at one sitting is usually adequate. Each lesion is individualized and surrounding skin protected by a cone of suitable size. Reaction occurs in about eight days, and the warts disappear in about three weeks. Those about the finger nails seem to be more resistant, and, if possible, the nailbed should be protected because reaction may cause deformity of the nail.

The treatment of deep plantar warts by irradiation is not so simple. The reaction to the infection is a growth of callus that may invade in a tack-like extension to considerable depth below the skin surface, even to the plantar fascia (fig. 6). This accounts for the severe and often disabling pain associated with them, especially when they are located over the heads of the metatarsals.



Superficial plantar warts can be treated successfully with contact x-ray therapy. If there is considerable callous formation over them this is shaved off with a scalpel, the lesions localized by metal cones, and one treatment of 2000 to 3000 r unfiltered radiation given. The reaction is a line of cleavage beneath the skin over the wart. The wart can be removed painlessly with a scalpel about three weeks after treatment.

In many cases plantar warts have penetrated so deeply, often to the plantar fascia, that they cannot be successfully treated by irradiation. Most of those which we have seen have been treated previously with topical application of caustic agents, roentgen therapy, and surgical operations. They are secondarily infected, consequently they do not respond to irradiation. The most successful treatment for deep plantar warts, developed by Dr. James A. Dickson of the Department of Orthopedics,<sup>1</sup> is removal of the toe and the metatarsal bone underlying the lesion. Although this seems to be a radical procedure it causes very little deformity of the foot, and results are most gratifying and are superior to any other therapeutic procedure.



FIG. 6. Photomicrograph of sagittal section of deep plantar wart extending tack-like to plantar fascia.

**Local recurrences from carcinoma of the breast**, if not too numerous or coalescent, yield satisfactorily to contact x-ray therapy. These lesions occur most frequently after operations on patients with involvement of the skin or muscles which cannot be, or have not been, removed. They may appear near the scar as small hard nodules a few weeks, months, or even years after operation, and the skin over them may be normal in color or red. They can be individualized and localized with suitable-sized cones for contact x-ray therapy and about 4000 r given with or without filtration, depending upon the size and depth of the nodules. Although the recurrences so treated will not recur, others or metastases usually develop later.

**Superficial epitheliomas** have been classified into three main types as basal cell, squamous cell, and mixed basal-squamous cell. There are variations of these according to clinical and histologic differences. It is often difficult,

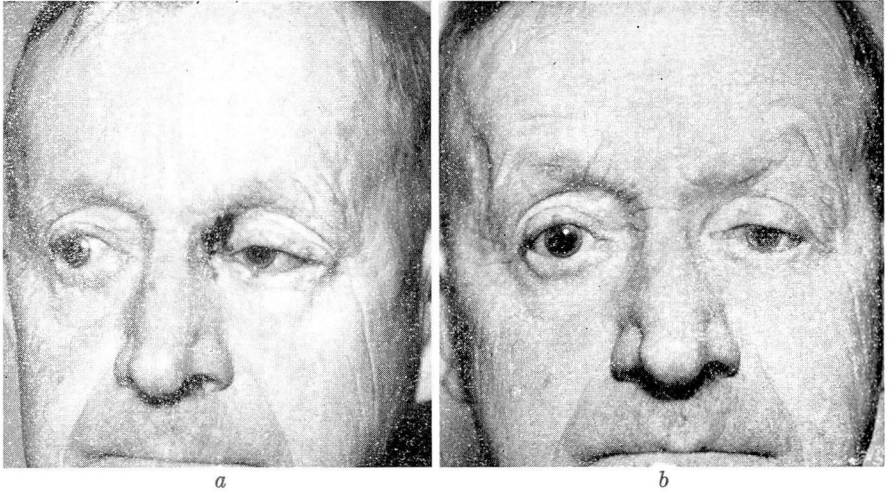


FIG. 7. (a) Epithelioma of skin of eyelid with involvement of lacrimal sac area. (b) Result after two years. No excessive lacrimation or recurrence.

if not impossible, to distinguish between different types of epitheliomas clinically.

Basal cell epitheliomas are the most common type. They usually occur in elderly people as single and occasionally multiple lesions on exposed skin of the face, ears, and hands, sometimes in relation to pre-existing keratoses. They start as painless, discrete, tiny, pearl-like papules which slowly enlarge and may ulcerate in the center. They are frequently thought to be "pimples." As the ulcer slowly enlarges the margins become elevated and rolled with pearly borders and covered by telangiectasia. Though they grow relatively slowly, if long standing or inadequately treated they will destroy underlying tissues, including cartilage and bone. Those that are extensive and ulcerative are called "rodent ulcers." They do not metastasize to adjacent lymph nodes.

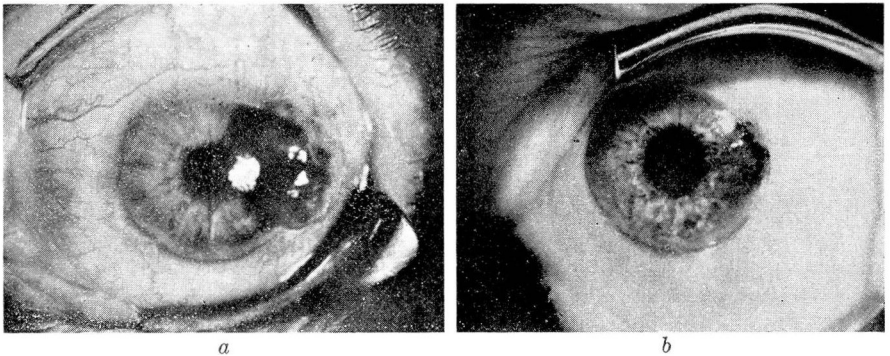


FIG. 8. (a) Squamous cell carcinoma of conjunctiva. (b) Result after two years. No recurrence or damage to eye. (Courtesy of DR. J. ROBERT ANDREWS.)

Squamous cell, or prickle-cell, epitheliomas also usually occur in elderly people on exposed surfaces and in relation to pre-existing keratoses. They are most common in people who are sensitive to actinic rays and who are constantly exposed to sunlight for many years, for example, farmers. Almost all epitheliomas occurring at mucocutaneous junctions about the mouth, anus, male urethra, and vulva are of the squamous cell type. The lesions may be papillary or sessile in growth characteristics and when sessile may simulate the basal cell type. The papillary type is less malignant than the sessile and does not tend to metastasize so early. These lesions begin as superficial ulcerations with crater formation, with or without a rolled pearly border, and considerably more induration is present than in basal cell epitheliomas. Some of the papillary type are cauliflower growths.

Small superficial basal and squamous cell epitheliomas without metastases can be easily and effectively treated with contact x-ray therapy. They are cancers, and therapy must be adequate. It is especially necessary to irradiate normal tissue well beyond the apparent borders of the lesions, because many have cutaneous or subcutaneous extension greater than can be detected clinically. The dose used is never less than 4000 r, and in many cases considerably more may be required, depending upon the depth of involvement. Filtration or increased distance and several fields may often be necessary.

The contact x-ray therapy is particularly useful for epitheliomas involving the eyelids (fig. 7), the conjunctiva (fig. 8), or lesions over bone or cartilage of the nose and ears because there is so little damage to underlying tissues. For deep, bulky, or extensive epitheliomas higher voltage x-ray therapy is preferable.

#### Reference

1. Dickson, J. A.: Surgical treatment of intractable plantar warts. *Cleveland Clin. Quart.* 13:92-95 (April) 1946.