

TRANSORBITAL INTRACRANIAL STAB WOUNDS

C. C. McCLURE, Jr., M.D. and W. JAMES GARDNER, M.D.

Department of Neurosurgery

FOUR cases of transorbital intracranial stab wounds are presented, each one illustrating a different clinical picture and demonstrating the vulnerability of the brain when approached through the thin-walled, funnel-shaped orbit.

Although much has been written concerning the incidence of wounds of the cranial contents as well as numerous articles pertaining to wounds of the orbital contents, relatively little has appeared about wounds which involve the intracranial structures by way of the orbits. This is difficult to understand since this is one of the most accessible modes of entry to the brain for stabbing instruments. Possibly it is due to the fact that most such serious wounds are rapidly fatal while some of the milder cases are undiagnosed because they exhibit few intracranial symptoms. These 4 cases serve to illustrate several of the possibilities which may be encountered in such wounds.

A group of war wounds involving the orbit and adjacent brain structures is discussed by Webster, Schneider and Lofstrom.¹ These were often injuries caused by high explosives and significant in the damage produced. The mortality in their series was 12.5 per cent as compared with a mortality rate of 6.4 per cent in penetrating wounds of the cranium generally. According to Courville and Schillinger,² Kuntzman reports the case of a patient who stuck a pencil through the roof of the orbit into the brain, developed meningitis and died. Evatt³ reports a case of an ice pick stab in the orbit which was first seen three hours after admission and which was so firmly embedded that it required the efforts of two men to pull it from the wound. This patient suffered no impairment of the eyesight.

Anatomical Considerations

The orbit is a pyramidal, cone or funnel-shaped cavity which is formed by various bones of the cranium and face. It contains the eyeball and structures relating thereto. The eyeball itself is a tough, elastic globe which is readily movable in its bed of fat making it less liable to injury from penetrating wounds. The superior wall of the orbit is formed by the frontal and sphenoid bones. The medial wall is made up of the lacrimal, ethmoid and sphenoid bones and the lateral wall is made up of the zygomatic, sphenoid and frontal bones. There are several openings in the orbit. The largest is the aditus which is the opening to the exterior. The optic foramen, which transmits the optic nerve and the ophthalmic artery, is situated at the back of the orbit. The sphenoidal fissure is located on the superolateral surface of the orbit and transmits the third, fourth, the ophthalmic division of the fifth and the sixth nerves; also

some filaments from the cavernous plexus of the sympathetic and the orbital branches of the middle meningeal artery. Passing out through the fissure are the ophthalmic vein and the recurrent branch from the lacrimal artery to the dura. On the inferolateral surface is the inferior orbital fissure which transmits the maxillary nerve and its zygomatic branch, the infra-orbital vessels and the ascending branches from the sphenopalatine ganglion. In the fronto-ethmoidal suture are the anterior and the posterior ethmoidal nerve and the ethmoidal vessel. These comprise the more important of the openings of the orbit. Thus, the orbit is a funnel-shaped cavity which would tend to deflect penetrations posteriorly through one of the numerous openings and thence into the brain which lies above and behind it. Freeman⁴ has pointed out the ease with which the roof of the orbit may be penetrated to reach the frontal lobes of the brain in the performance of a transorbital prefrontal leucotomy.

High speed projectiles entering the orbit are apt to lacerate or rupture the eyeball. Conversely, a slower moving stabbing instrument is not so likely to damage the globe because the blinking reflex covers the eyeball with tough skin which, in effect, blunts the stabbing instrument. At the same time, the slower velocity of the stabbing instrument enables it to overcome the inertia of the tough globe which is shoved to one side in its puddle of fat.*

**This is analogous to the stab wounds of the peritoneal cavity. Such wounds tend to push aside the intestines rather than to penetrate them, as is seen in gunshot wounds.*

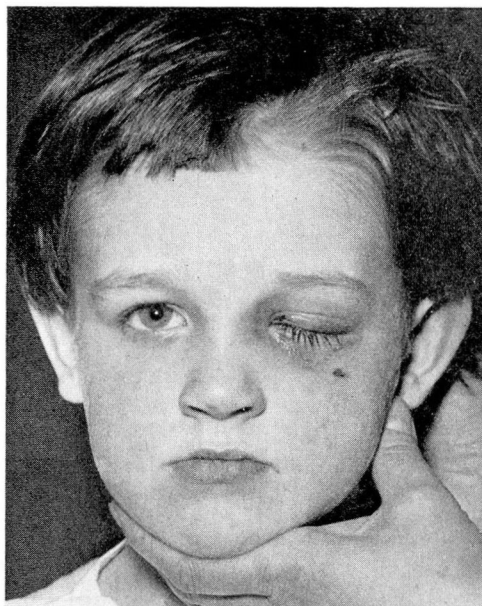

FIG. 1. Case 1. Four days after injury.

Case Reports

Case 1. A four-year-old boy was admitted to the Cleveland Clinic Hospital. At ten o'clock on the morning of admission, the patient had fallen on a pitch-fork blade which was driven through the inner part of his left upper eyelid. He was taken to his local doctor who sent him to an eye specialist. Here it was found that there was leakage of spinal fluid from the wound. He was given 100,000 units of penicillin intramuscularly, and sent into the hospital by ambulance. By the time he arrived, he had vomited two or three times, and was complaining of pain in the back of his neck. There had been no other symptoms.

Physical examination showed the temperature to be 98.6 F. and the pulse 116. He did not appear acutely ill. Examination of the eyes showed that the left eyelid was blue and swollen completely closed. There was an irregular wound $\frac{1}{2}$ inch in length on the inner aspect of the upper lid which was draining slightly blood-tinged cerebrospinal fluid. When the eyelids were forced apart the globe appeared normal. Examination of the cranial nerves revealed them to be intact. The reflexes were all normal and there were no pathologic reflexes. There were no motor or sensory paralyses.

X-rays showed a variation of the appearance of the superior orbital wall on the left side; this wall appeared thickened and there was a questionable translucent line extending through the superior orbital wall. The impression was "Localized changes involving superior orbital wall on left—old trauma?"

The diagnosis at the time of admission was "Penetrating wound, brain, transorbital route with cerebrospinal fluid leak." The patient was placed on penicillin, 30,000 units every three hours for five days and was given a dose of tetanus and gas gangrene antitoxin.

The leakage of cerebrospinal fluid stopped two days after admission. The edema of the lid gradually diminished during the hospital stay and at the time of the patient's discharge on the eighth hospital day, the eye was open, the pupillary and extraocular movements were normal and there was no evidence of injury to the globe.

Because of the absence of cerebral symptoms in this case, the intracranial wound might

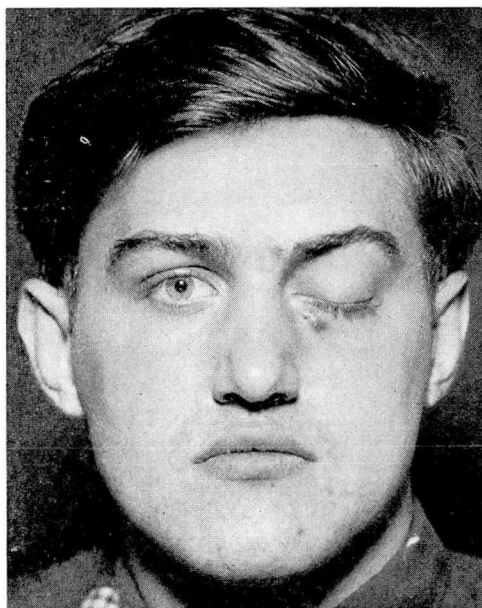


FIG. 2. Case 2. Eleven days after injury.

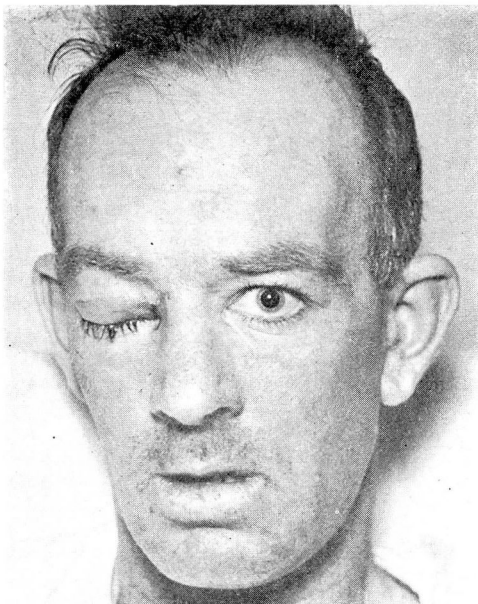

FIG. 3. Case 3. Twenty-one days after injury.

not have been suspected if there had not been leakage of the cerebral fluid from the wound (fig. 1).

Case 2. An 18-year-old boy was observed with a chief complaint of being unable to open the left eye. Nine days before, while playing football in a stubble field, he was tackled and thrown face down. He immediately experienced an excruciating flash of pain about the left eye and the forehead and on arising was unable to open his left eye. He was told that he had a "scratch" on the left lower eyelid.

On examination, the patient exhibited a complete paralysis of the left third, fourth and sixth cranial nerves and the ophthalmic division of the fifth. There was a small, partially healed laceration on the lower lid. There was no tenderness, ecchymosis, audible bruit or pulsation. Vision in the eye was good and funduscopic examination was satisfactory. X-rays of the skull and orbits were reported as normal.

Diagnosis at that time was "Stab wound of left orbit through the sphenoidal fissure resulting in interruption of the cranial nerves transmitted through the latter."

Three days later, the laceration on the lower lid became swollen. The margins of the wound were separated and, with a hemostat, two pieces of grass stubble were removed from deep within the orbit. The wound was treated with sulfa powder locally and diathermia to the orbit, and rapidly healed. The neurologic aspects slowly improved, and the patient was discharged on the ninth hospital day. When last seen, he had partial return of eye motion and could open the eye.

In this case we have an example of a wound which might well have injured the eyeball but, instead, pushed it aside and it escaped injury. This case also serves to illustrate that even an insignificant external wound may be the cause of a complete and possibly permanent external ophthalmoplegia (fig. 2).

Case 3. A 37-year-old man entered the Cleveland Clinic Hospital with a history of having been struck with a large wooden splinter which had entered the right upper eyelid, and the orbital cavity into the brain. This had occurred twelve days prior to admission. The patient had been sawing lumber into strips with a rotary saw when a broken piece.

thrown forcibly, struck him with the irregular end. The splinter, three feet long, was removed by fellow workmen before admission to his local hospital. When first seen by his local doctor, profound shock was present with loss of consciousness and bleeding from the nose. The patient was put to bed and treated for shock. Intravenous fluids were administered, and the patient vomited some "coffee grounds" material. After about twelve hours the patient recovered from shock and was able to talk coherently in about twenty-four hours. It was then noticed that he had a paralysis of the left arm and leg and there was incontinence of urine and feces. The right eyeball appeared intact, but there was no vision in the right eye.

Physical examination on admission to the Cleveland Clinic Hospital showed a temperature of 99.6 F., pulse rate of 46, and blood pressure of 100/80. The patient brought with him the stick which was three feet long and roughly a half an inch in diameter. The jagged end was bloody for three inches indicating that this portion had penetrated. There was a granulating wound of the right eyelid above the inner canthus with ptosis of this lid. The right pupil was dilated and did not react to light or accommodation. There was no light perception, and no extraocular movements in this eye. Funduscopic examination was negative except for some retinal edema. The patient had spells of involuntary crying. There was complete, flaccid left hemiplegia. The deep reflexes were normal, but the abdominal reflexes on the left were absent. The Babinski was negative but there was a positive Kernig's sign.

Lumbar puncture on admission disclosed a pressure of 190 mm. with normal dynamics. The fluid was clear but a deep orange in color. It showed a trace of globulin and the total protein was 50 mg. The cell count was 1. Spinal fluid culture was satisfactory as was the urine. Examination of the blood showed a hemoglobin of 14.5 Gm. and a white blood cell count of 11,350. X-rays showed a normal skull and normal orbits with no evidence of foreign bodies.

The diagnosis was "Penetrating wound of the brain through the right orbit with internal and external ophthalmoplegia."

Because of the possibility that hemiplegia might be due to laceration of the right internal carotid artery rather than the brain wound, a right carotid arteriogram was made. There was no visualization of the right anterior cerebral artery.

The patient was given 50,000 units of penicillin every three hours for ten days and became afebrile in twenty-four hours. He was discharged after eleven days in the hospital, with the paralysis still present. About one week after discharge his right eye began to open and he became able to walk with a cane. In about three months he could move the eye in all directions but there was no return of vision and only slight return of motion in the arm.

This illustrates a case of a violent wound of the orbit which penetrated the brain to a depth sufficient to produce hemiplegia in addition to the local ocular paralysis but in which the eyeball was not damaged (fig. 3).

Case 4. A colored man, 22 years of age, was picked up by police from the gutter outside a tavern. He was taken to a hospital where he was seen to be literally covered with blood. He could at no time give an account of events leading up to injury.

On entry, physical examination revealed a patient in coma, with Cheyne-Stokes respiration. The blood pressure was 120/80. There was severe rigidity of the neck. The right pupil was fixed and did not react to light. There were no hemorrhages in either fundus. There was swelling of the left eyelid. There was a stab wound on the left side of the neck which was probed and found to be .5 cm. deep. There was no hematoma. Convulsive-like movements were noted involving the right arm. The left arm was motionless although the other extremities thrashed about. The deep reflexes were found to be somewhat hypoactive but were bilaterally equal. There was a positive Babinski on the right.

A lumbar puncture upon admission showed bloody spinal fluid, but this was thought to be due to trauma of the puncture. A diagnosis of stab wound of the neck and cerebral contusion with acute alcoholism was made. He rapidly developed swelling of the contents of both orbits. By the third hospital day, he became rational and neurologic findings cleared. The blood count at this time revealed 58 per cent hemoglobin, 2,830,000 red blood cells, and 6,400 white blood cells. The urine was negative. The temperature ranged from 99 to 102 F. throughout the course of the illness. On the ninth hospital day, he had a severe

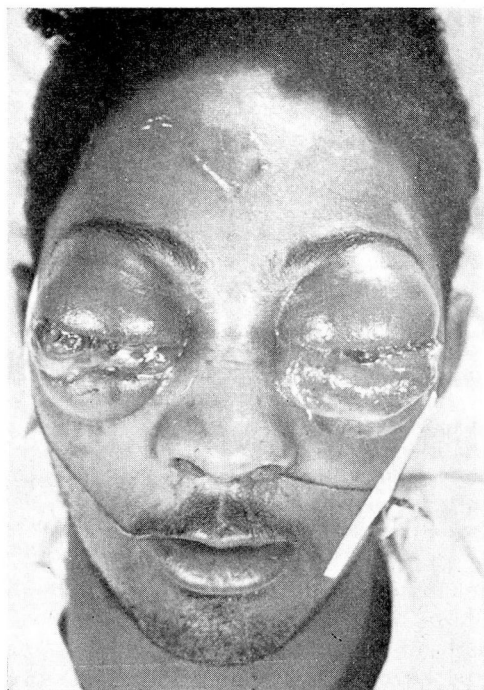

FIG. 4. Case 4. Twelve days after injury. (Nasal packs were inserted to control nasal hemorrhage.)

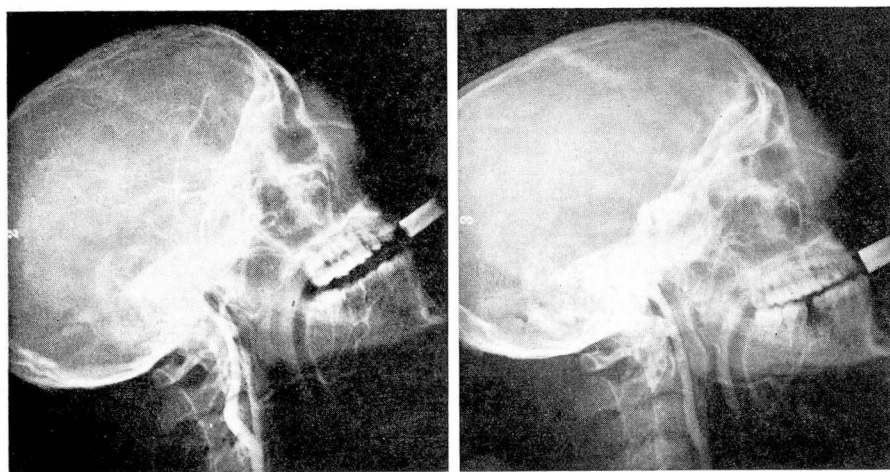


FIG. 5. (a) Case 4. Left carotid arteriogram, showing normal filling of arterial system. (b) Case 4. Right carotid arteriogram, showing carotid-cavernous sinus arteriovenous fistula.

hemorrhage from the nose and almost bled to death. It was finally controlled with postnasal packs. About the same time he lost all light perception in both eyes. Three days later, he had a recurrence of the nasal hemorrhage. On the fourteenth hospital day, a neurosurgical consultation was obtained. At this time the patient's orbital contents were in a state of extreme protrusion due presumably to posterior orbital hematomas (fig. 4). A small wound of the left lower eyelid was found at this time. This finding together with the clinical course led the examiner to suspect that the patient had sustained a stab wound through the left orbit into the base of the skull with laceration of one of the internal carotid arteries, probably the right, in view of the dilated, fixed right pupil and paresis of the left arm. Carotid arteriograms were advised. The patient received a blood transfusion and on the sixteenth day arteriograms were made. The left arteriogram was performed first and showed normal findings so the right arteriogram was made. This disclosed the typical picture of a carotid cavernous arteriovenous fistula (fig. 5a and 5b). During the procedure, the patient's respiration ceased, but by the use of stimulants and artificial respiration, it was again established. Ligatures were applied to the right external, internal and carotid arteries and the latter vessel was divided between the ligatures. The patient's condition did not permit intracranial ligation.

The patient failed to rally following the procedure and died forty-eight hours later. Postmortem examination was performed by the coroner and disclosed a laceration of the right carotid artery and cavernous sinus. There was an old hematoma at the base of the right temporal lobe. There was also a subdural hematoma on the convex side of both hemispheres and hematomas of both orbits. The diagnosis was not suspected for two weeks because attention had been directed to the neck while the actual wound of entry was overlooked.

Case 4 serves to illustrate that no matter how trivial a wound may be, its possibilities should be thoroughly explored in the light of developing symptoms even if they implicate the opposite side of the brain. Also, in arteriovenous fistulae involving the internal carotid artery and the cavernous sinus, the carotid artery should be ligated above the cavernous sinus before ligating it in the neck. This has been emphasized by Sweet and Bennett⁵ who found that in carotid cavernous sinus arteriovenous fistulae, the affected carotid maintains an intravascular pressure which, in effect, plugs up the defect there by allowing blood from the opposite carotid to circulate through both sides of the brain. When the affected carotid is ligated in the neck this cuts off the counter pressure and allows blood from the unaffected carotid to pass from the homolateral hemisphere out through the defect thus depriving the brain circulation of a corresponding amount of blood.

Summary and Conclusions

1. Four cases of transorbital stab wounds are presented each of which serves to illustrate a different type of intracranial damage.
2. In stab wounds of the orbit, the eyeball frequently escapes injury.
3. The possibility of an intracranial wound should be considered in all cases of stab wounds of the eyelids.
4. In cases of carotid cavernous sinus fistulae, the carotid artery should be ligated intracranially before ligation in the neck.

References

1. Webster, J. E., Schneider, R. C., and Lofstrom, J. E.: Observation upon management of orbito-cranial wounds. *J. Neurosurg.* 3:329-336 (July) 1946.

STAB WOUNDS

2. Courville, C. B., and Schillinger, R. J.: Intracranial complication of disease of eye and orbit. Bull. Los Angeles Neurological Soc. **11**:120-110 (Sept.) 1946.
3. Evatt, C. W.: Ice-pick through orbit; case report. J. South Carolina M. A. **43**:236 (Aug.) 1947.
4. Freeman, W.: Transorbital leucotomy. Lancet, p. 371 (Sept. 4) 1948.
5. Sweet, W. H., and Bennett, H. S.: Changes in internal carotid pressure during carotid and jugular occlusion and clinical significance. J. Neurosurg. **5**:178-195 (March) 1948.