

INTESTINAL OBSTRUCTION

Gallstone Impaction

JOSEPH C. ROOT, M.D.

Department of Roentgenology

ACUTE intestinal obstruction is a medical emergency requiring prompt diagnosis and treatment. Time is an important factor in this condition and without relief, ileus, with its vicious cycle, may develop. With the advent of the roentgen examination and its subsequent improvement in technic for visualization of the gastrointestinal tract, extensive strides have been made in the diagnosis of intestinal obstruction. This procedure may be employed, not only as a means of diagnosis, but also for localization of the site of the lesion and its possible cause. Having ascertained the approximate location, the surgeon may better plan his approach for alleviation of the condition.

There are, of course numerous causes for an acute obstruction, the most common comprising peritoneal adhesions from previous inflammatory disease or operation. Among other causes, in diminishing frequency, are neoplasm, intussusception, volvulus and impaction of gallstones. The latter is somewhat uncommon and found to be present in less than 2 per cent of all acute intestinal obstructions. History of previous biliary disease is suggestive but definite diagnosis and localization may be made in most instances by the roentgen examination.

Case Report

A 67 year old widow entered the Cleveland Clinic March 8, 1948, complaining of vomiting and inability to eat. The patient had been well until July 1947 when she suddenly contracted severe pain in the right upper abdomen and flank which seemed to travel downward toward the right hip and was accompanied by vomiting. This condition persisted for two days with additional symptoms of weakness and poor appetite.

In October 1947 she became jaundiced and large gallstones were discovered upon examination. Operation was attempted but the patient became unconscious on anaesthetic administration, whereupon surgery was postponed and she returned to her home.

No untoward symptoms presented themselves until about two weeks prior to her present admission when she again experienced nausea, loss of appetite and extreme weakness. Gripping transabdominal pain occurred prior to vomiting. The patient suffered from chronic constipation. She had recently emitted black vomitus.

Her personal history was essentially satisfactory except for having experienced malaria in childhood and jaundice at the age of 24.

Physical examination divulged extreme tenderness over the right hypochondrium, the right half of the epigastrium and the lumbar area. The muscles were splinted and the liver showed indications of enlargement. Some suggestion of a mass was evident in the epigastrium.

The roentgen examination disclosed a normal chest. A film taken for the kidneys, ureter and bladder revealed minimal hypertrophic changes of the lumbar vertebrae. A large, somewhat circular, faintly calcified shadow was present in the left upper quadrant. This shadow was suggestive of a "signet-ring" gallstone. No calcifications were found in the urinary tract.

Opaque shadows were not seen in a plain film of the gallbladder. The stomach and esophagus were normal with no organic lesion demonstrated in the former, although a considerable amount of fluid was present at the time of fluoroscopic examination. The duodenum was normal except for minimal dilatation and for this reason a six hour retention

film was ordered. In the roentgenograms of the stomach and duodenum there was suggestion of a small amount of gas in the hepatic radicles. The six hour retention film demonstrates obstruction in the distal portion of the jejunum with moderate dilatation proximal to that point. Just proximal to the site of obstruction is a rounded, nonopaque shadow. Barium is visualized in the hepatic radicles.

The operation, a transintestinal removal of impacted gallstone, was performed by Dr. George Crile, Jr. At a level of approximately two feet from the duodeno-jejunal junction, was a hard, oval stone measuring about 4 cm. by 6 cm. This was impacted and produced complete obstruction of the intestine. The duodenum and pyloric portion of the stomach were firmly attached to the liver in the region of the gallbladder and it was assumed that a spontaneous cholecystoduodenostomy had occurred. Further exploration of this area appeared inadvisable.

The patient made an uneventful recovery and left the hospital on the sixteenth post-operative day.

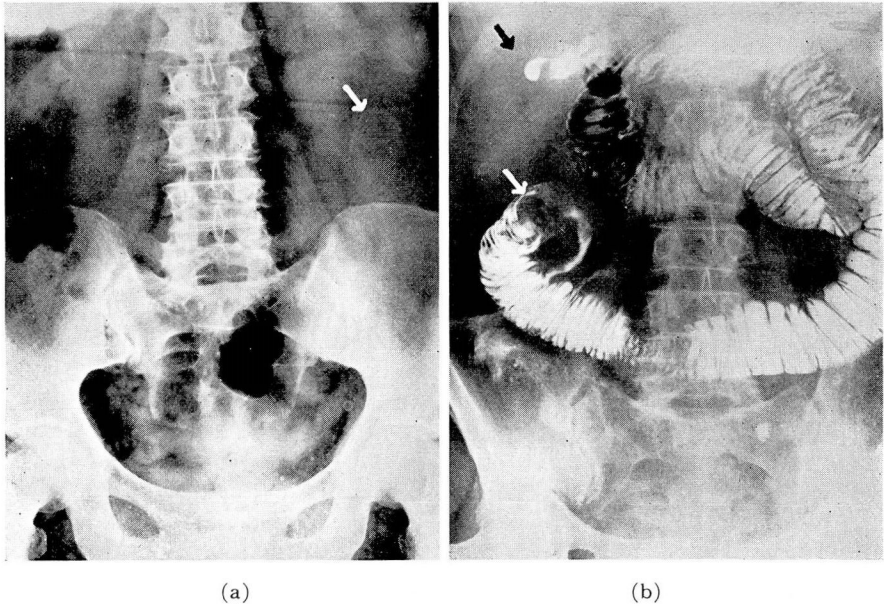


FIG. 1. (a) Plain film of abdomen. Faintly visualized "signet-ring" shadow in left upper abdomen suggestive of gallstone; (b) obstruction of jejunum with dilatation proximal to site of obstruction. Large gallstone shown (white arrow). Black arrow designates barium in hepatic radicles.

Discussion

Obstruction of the intestine, partial or complete, may be due to any local pathologic condition which prevents the flow of intestinal contents. It may exist without ileus although the latter will ensue if the block is not relieved, and can exist without a mechanical obstruction; for that reason this term should not be considered synonymous with obstruction. Ileus, then, can be defined as a dilatation of the intestine, either a portion or its entirety, with excessive gas or fluid within the lumen. Disturbances of the physiology of the intestine contribute to, as well as result from ileus.

The small intestine has the inherent ability to cope with obstruction. Eventually, however, dilatation occurs due to fatigue of the musculature and an anoxemia of the muscle fibers from a disturbed blood supply. Compensation may be re-established at intervals by the intestine but the process frequently progresses into the terminal stage of tissue necrosis if the obstruction is not relieved by intubation or surgery.

The fluid contained in the dilated bowel is caused by ingested fluid as well as an increased secretion and diminished absorption. The small intestine performs both of these functions, secretion from the upper portion and absorption from the distal portion. With dilatation the actions are disturbed due to interference with the circulation from compression of the capillaries within the intestinal wall. The gas may result from swallowed air, diffusion of blood gasses into the lumen or the decompensation of intestinal contents, the latter probably the most important source. However, with the onset of dilatation a vicious cycle is set up with production of more fluid and gas which in turn increases the degree of dilatation.

The term paralytic or dynamic refers to an ileus in which there is no intrinsic obstructing cause within the intestine. Such a condition may result from peritonitis or even distant infection from the lungs or kidneys. Neurogenic disturbances such as spine injury may contribute to this condition. Vascular occlusion in mesenteric thrombosis is an important etiologic factor of a localized ileus which may rapidly progress to the terminal stage of tissue necrosis. In general, paralytic ileus follows much the same course as ileus from an intrinsic obstruction. The distention in the paralytic type is more likely to involve all of the intestinal tract in contrast to segmental dilatation usually observed with an early obstructive ileus.

The roentgen examination is of undisputed value in the diagnosis of such cases. Many times localization is possible so that the surgeon may be guided in his approach to the lesion. Plain roentgenogram films of the abdomen in both right and left lateral decubitus, supine and upright positions are important for the preliminary examination when obstruction is suspected. These roentgenograms should be made without prior cleansing preparation since a laxative may produce disastrous consequences and enemas tend to introduce confusing air or fluid shadows. A single film taken with the patient supine (fig. 1a) will frequently give evidence of the causative factor. When ileus has developed the roentgen examination shows a more or less set pattern regardless of the cause. This is characterized by the distended gas-filled loop or loops of intestine and the fluid levels which may be visualized in the decubitus and upright positions. Gas, as a rule, is not present in the normal small intestine although it may be seen at times in somewhat large quantity as with ureteral colic. In such instances, however, there is little or no distention of the lumen. Localization in the plain films depends upon the location and appearance of the gas-filled loops in the abdomen. The mucosal folds in the jejunum are rather high but tend to become smaller as the distal portion of the ileum is reached. The high folds are not easily obliterated when the bowel is distended so that cross striations or a "herring-bone" pattern in a high obstruction can be

visualized. A dilated distal ileum shows smooth walls and may be confused with the colon if the distention is pronounced. With caution a thin barium mixture may be given, either orally or through a Miller-Abbott tube for better localization of the site of obstruction (fig. 1b). By use of the barium the nature of the obstruction may be observed, whether caused by peritoneal adhesion, neoplasm or foreign body. No complications following administration of thin barium mixture have occurred and this procedure is employed even with existence of ileus. In such a case a small amount, approximately 20 to 30 cc. is injected through the Miller-Abbott tube and under fluoroscopic control. Survey films and additional fluoroscopic examinations are then made at appropriate intervals until adequate visualization of the intestine is obtained.