

DIAGNOSIS AND TREATMENT OF THE CARDIAC ARRHYTHMIAS

A. CARLTON ERNSTENE, M.D.
Division of Medicine

DISTURBANCES of the rhythm of the heart comprise one of the most common problems in clinical cardiology. They may occur as a complication of organic cardiac disease or in the entire absence of a structural abnormality of the heart. Certain arrhythmias are of no significance although they often cause disagreeable symptoms. Others result in an important reduction in the mechanical efficiency of the heart and may precipitate congestive myocardial failure or intensify pre-existing decompensation. Still others, among the more uncommon disorders, constitute a direct threat to life. Accurate diagnosis is essential not only for appropriate treatment but also for correct estimation of the clinical importance of the condition. Fortunately, most of the arrhythmias can be recognized by physical examination alone. Electrocardiographic corroboration of the diagnosis is always desirable, however, and a few of the disturbances can be identified only by instrumental means.

Premature Beats

Premature beats, the most common type of cardiac arrhythmia, may arise from the auricles, ventricles, auriculoventricular node or main stem of the bundle of His. They are of clinical significance only in exceptional instances although they not infrequently cause uncomfortable symptoms due either to the pause which follows the premature beat or to the unusual force of the next normal ventricular contraction. Patients frequently report a sensation that the heart has stopped momentarily or skipped a beat. Occasionally, in sensitive persons, there may be fleeting lightheadedness, a choking sensation in the throat, or transient pain in the precordial or substernal area.

Premature beats usually can be recognized without difficulty by auscultation of the heart. The dominant cardiac rhythm is regular but is disturbed, at frequent or infrequent intervals, by a beat which comes before its expected time and is followed by a pause. If the beat is exceptionally premature it may fail to cause a perceptible pulsation in the radial artery. Auricular and nodal premature beats disturb the basic rhythm of the sinoauricular node and because of this the pause which follows them is not completely compensatory. The interval between the normal beat preceding the early beat and the first normal response after the premature systole is less than the length of two normal cycles. In ventricular premature beats, on the other hand, the rhythm of the normal pacemaker is not disturbed, and the compensatory pause is complete. Although one may at times estimate the completeness of the compensatory pause with fair accuracy by auscultation, the electrocardiogram is necessary for positive differentiation of the various types of premature beats.

Auricular premature beats are characterized electrocardiographically (fig. 1) by P waves which differ in form from the P waves of the patient's normal beats and are often inverted or diphasic. The P-R interval is usually longer than 0.10 seconds. The QRS complexes generally are similar to the normal QRS complexes, but if the premature beat occurs before the bundle branches or ventricular musculature have recovered from their refractory period, distinctly aberrant complexes may result.

In nodal premature beats (fig. 2), the P waves also are of abnormal form but differ from the P waves of auricular premature beats in that they may occur after, during, or before the QRS complex. When they precede the QRS complex, the P-R interval is less than 0.12 seconds. The QRS complexes usually are similar to those of the normal beats.

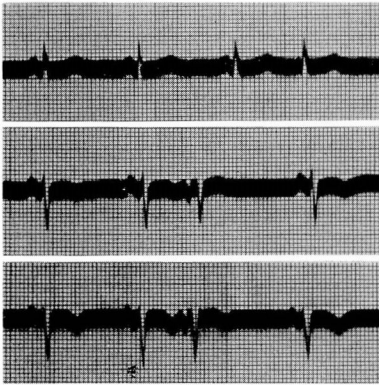


FIG. 1

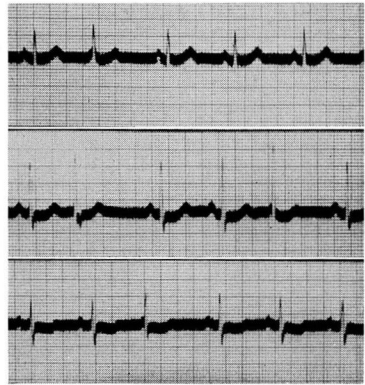


FIG. 2

FIG. 1. Auricular premature beats. The P waves of the premature beats differ in form from that of the normal beats, but the QRS complexes show only minor alterations. The compensatory pause is incomplete.

FIG. 2. Nodal premature beats. With the exception of the first premature beat in lead II, the P waves of the premature beats fuse with the beginning of the QRS complexes.

Ventricular premature beats (fig. 3) cause abnormal, widened, slurred or notched QRS complexes which are not preceded by a P wave. Occasionally they may be interpolated between two normal cardiac contractions, in which event they constitute a true extra systole.

Since premature beats rarely are of significance, they seldom require treatment. Inquiry should be made concerning nervous tension and the excessive consumption of tobacco or coffee because control of these factors may diminish the arrhythmia or correct it entirely. In patients who are experiencing annoying symptoms or who have become concerned about the heart, reassurance is important and mild sedatives often are helpful. If symptoms persist in spite of these measures, quinidine sulfate, 0.2 Gm. (gr. 3) two or three times a day may prove of value. Potassium chloride in doses of 1 or 2 Gm. three or four times a day may also be effective but must not be administered to indi-

viduals who have renal disease. The fact that premature beats so frequently occur while a person is at rest and can be eliminated by physical activity should be pointed out, especially to apprehensive patients.

Although premature beats are observed in many normal individuals, they occur even more commonly in patients who have organic heart disease and are at times of clinical importance. The arrhythmia, for instance, may be an early manifestation of digitalis intoxication. Myocardial insufficiency is accompanied occasionally by the appearance of frequent premature beats arising from one or more foci in the ventricular myocardium. Digitalis therapy and sodium restriction may then reduce their number or abolish them entirely. In acute myocardial infarction, frequent premature beats are a potential

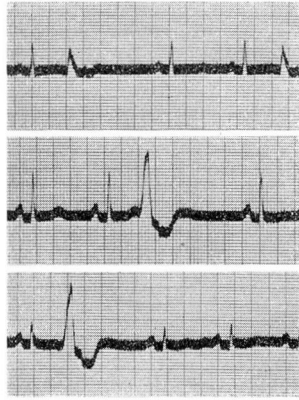


FIG. 3. Ventricular premature beats. The QRS complexes of the premature beats are wide, slurred and distinctly abnormal, and they are not preceded by a P wave. The compensatory pause is complete.

precursor of ventricular paroxysmal tachycardia, and in their presence the administration of quinidine sulfate as a prophylactic measure against the development of this more serious arrhythmia is indicated. Numerous auricular premature beats are at times a forerunner of auricular fibrillation, especially in patients who have mitral stenosis. Quinidine sulfate and sodium restriction may be of value in preventing this type of progression.

Auricular Paroxysmal Tachycardia

Auricular paroxysmal tachycardia consists fundamentally of a paroxysm of auricular premature beats and, next to premature beats, is the most common disturbance of cardiac rhythm. Characteristically, the attacks develop and end abruptly. They may last for a few beats only or for hours or days. The rhythm during the paroxysm is perfectly regular and the heart rate generally between 160 and 200 beats per minute. Although the condition occurs occasionally in persons who have organic heart disease, it is encountered most commonly in patients who present no abnormal cardiac findings.

In adults who have normal hearts, auricular paroxysmal tachycardia causes no cardiac embarrassment even if the attacks persist for days. The patient, however, is often considerably disturbed by weakness, faintness, dizziness or palpitation. In infants and in individuals who have organic heart disease, a prolonged paroxysm may result in the development of congestive heart failure, and in persons with coronary artery disease, an attack may be accompanied by substernal pain which persists until the tachycardia is controlled.

The electrocardiogram in auricular paroxysmal tachycardia (fig. 4) shows a rapid, regular succession of QRS complexes which are typically of normal contour. The ventricular rate seldom varies more than two or three beats per minute. The P waves usually are diphasic or inverted, and the P-R interval is prolonged. If no P waves are discernible, as is often the case, the condition cannot be distinguished from nodal paroxysmal tachycardia, and the term paroxysmal supraventricular tachycardia is then employed. Nodal paroxysmal tachycardia, however, is much less common than auricular paroxysmal tachycardia. The treatment of the two arrhythmias is the same.

There are a number of simple procedures which will abruptly terminate many attacks of auricular paroxysmal tachycardia. Among the most effective of these are holding a deep breath, pressure on the right or left carotid sinus, firm ocular pressure, and sudden flexion of the body at the hips. These measures either restore the heart rhythm to normal immediately or have no effect at all on the heart rate. If the tachycardia persists and the patient is in distress, drug therapy becomes advisable. The treatment of choice in such a circumstance is rapid digitalization, preferably by the intravenous route. Weisberger and Feil¹ have reported excellent results from the intravenous administration of lanatoside C in doses of 0.8 mg. (4.0 cc.) followed by a second dose of the same size when the tachycardia was still present after thirty minutes to one hour. One must, of course, be certain that persons who are to receive digitalis by intravenous injection have not received the drug in any form during the preceding two weeks.

Youmans, Goodman and Gould² recently reported that neosynephrin by rapid intravenous injection in doses of 0.5 mg. to 2.0 mg. will restore sinus rhythm in most cases of paroxysmal supraventricular tachycardia. The drug should not be administered to patients who have coronary artery disease or in whom hypertension is present during the tachycardia. Other preparations that often are effective are prostigmine methylsulfate, 0.5 to 1.0 mg., and mecholyl, 10 to 20 mg., repeated if necessary after thirty minutes. Both of these drugs are given by subcutaneous injection. Because of the frequency with which mecholyl causes symptoms of excessive parasympathetic stimulation, it is employed only rarely and only after a syringe containing atropine sulfate, 0.6 mg., has been prepared beforehand for intravenous use if necessary. Neither prostigmine nor mecholyl should be given to patients who have bronchial asthma, and the use of mecholyl is also contraindicated by the presence of coronary artery disease.

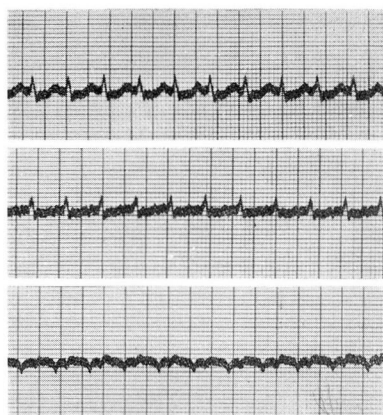


FIG. 4. Auricular paroxysmal tachycardia. There is a rapid succession of QRS complexes which are of normal contour. The rate is 188 per minute. The P waves are diphasic in leads 2 and 3, and the P-R interval is at least 0.16 seconds.

Ventricular Paroxysmal Tachycardia

Ventricular paroxysmal tachycardia is a relatively rare condition which usually is due to serious organic heart disease. It occurs most commonly as a complication of acute myocardial infarction, and in this situation it may be a forerunner of ventricular fibrillation. Occasionally, however, it is encountered in the entire absence of evidence of organic cardiac disease. As in the other types of paroxysmal tachycardia, the attacks usually are sudden in onset and termination, and the ventricular rate generally is in the range of 160 to 200 beats per minute. The electrocardiogram is necessary for certain identification of the arrhythmia, but Levine³ has pointed out that a reliable diagnosis can be made at times from the findings on physical examination alone. Although the rhythm in ventricular tachycardia at first impression appears to be regular, an occasional fleeting irregularity often can be detected by careful auscultation. This serves to distinguish the condition from auricular paroxysmal tachycardia. Furthermore, if one listens carefully over the cardiac apex, an occasional accentuation of the first sound for a single beat frequently can be heard. In ventricular paroxysmal tachycardia, the auricles and ventricles beat independently, and the accentuation of the first sound at intervals is due to simultaneous auricular and ventricular systole. In auricular paroxysmal tachycardia, the auricles and ventricles contract in normal sequence, and the intensity of the first sound, therefore, does not vary. As an additional point in differential diagnosis, pressure on the carotid sinus does not terminate the attack of ventricular tachycardia as it does so often in auricular tachycardia.

Electrocardiographically, ventricular paroxysmal tachycardia is characterized by an uninterrupted series of ventricular premature beats occurring at regular or almost regular intervals but frequently differing slightly in form from beat to beat (fig. 5). P waves occur at their normal rate but it may be

possible to recognize them only here and there. Unless P waves can be identified and the auricular rate estimated, a definite diagnosis of ventricular tachycardia cannot be made, for paroxysmal supraventricular tachycardia with aberrant QRS complexes and indiscernible P waves will produce a similar electrocardiogram.

Quinidine sulfate is the most valuable drug in the treatment of ventricular paroxysmal tachycardia. Although it can be given by intravenous injection, the oral route is used most commonly because of its greater safety. A number of different dosage schedules have been recommended. One that has proved satisfactory consists of the administration of 0.2 Gm. as a trial dose, followed by 0.4 Gm. every two hours until the ventricular rate slows to 120 per minute. Gold⁴ advises that, when the rate has been reduced to this level, the electrocardiogram be repeated in order to determine whether or not auricular activity is present. If it is, the administration of the drug is continued until normal rhythm is restored. If no P waves can be seen, on the other hand, the dose of quinidine is reduced and the interval between doses lengthened in such a manner as to maintain a rate of approximately 120 beats per minute. Electrocardiograms are made at intervals of two to four hours, and the original schedule of dosage is not resumed until P waves reappear in the tracings. This is done to avoid a period of complete cardiac asystole when the arrhythmia is brought to an end.

When quinidine sulfate fails to terminate a paroxysm of ventricular tachycardia, the intravenous administration of 10 cc. of a 20 per cent solution of magnesium sulfate may reestablish sinus rhythm.

Auricular Fibrillation

Although auricular fibrillation may occur in young individuals as a purely functional disorder, it usually is associated with organic cardiac disease, especially rheumatic heart disease with mitral stenosis. It is a not infrequent complication of thyrotoxicosis and may also develop during the course of pneumonia and certain other febrile illnesses. In it, there is complete incoordination of the contraction of the muscle fibers of the auricles. Auricular systole is abolished, and the auriculoventricular node is showered by a rapid, irregular succession of impulses from the auricles. Ventricular contractions occur in response to a variable number of these, and a completely irregular ventricular rhythm results. Ventricular responses which follow the preceding systole by a very brief interval often fail to cause a pulsation in the peripheral arteries, and a pulse deficit results. It is the absolute irregularity of the heart, however, and the entire absence of an underlying basic rhythm that constitute the pathognomonic features of the disturbance.

Auricular fibrillation can be recognized without difficulty as long as the ventricular rate is elevated, but when the rate has been reduced by digitalis or is naturally slow, careful auscultation may be necessary to distinguish the condition from the arrhythmia of premature beats. A helpful point in differential diagnosis consists of the fact that with premature beats a long pause is

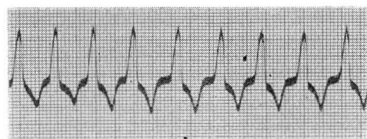


FIG. 5. Ventricular paroxysmal tachycardia. The QRS complexes are wide and slurred, and the rhythm is not quite regular. The ventricular rate is 140 per minute. Only a rare P wave can be identified.

always preceded by an early beat, but in auricular fibrillation such pauses often occur without shortening of the interval between the two preceding beats.

In the electrocardiogram of auricular fibrillation (fig. 6), the rhythm of the ventricles is completely irregular and the P waves are replaced by small, irregular, variable deflections, known as f waves, which usually have a rate of 400 to 450 per minute.

The presence of auricular fibrillation is always an indication for the administration of digitalis. When the ventricular rate is elevated, the drug is given in sufficient amounts to reduce the rate at rest to approximately 70 beats per minute. In the presence of hyperthyroidism, however, it is seldom possible to accomplish this degree of slowing before the appearance of symptoms of digitalis overdosage, and one should be content with ventricular rates between 90 and 100 per minute. Even when the ventricular rate is naturally slow in auricular fibrillation, digitalis is indicated in amounts sufficient to accomplish theoretical digitalization. This procedure usually does not cause further slowing of the ventricles but is recommended as a measure to prevent an undue rise in heart rate during physical activity or infections.

Digitalis does not possess the property of re-establishing normal rhythm in patients who have auricular fibrillation. Quinidine sulfate is employed for this purpose but the indications for its use are quite limited. It is of greatest value in cases in which the arrhythmia has developed as a complication of

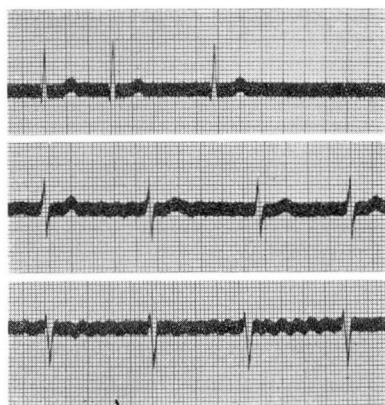


FIG. 6. Auricular fibrillation. The P waves are absent and have been replaced by small, irregular f waves. The ventricular rhythm is completely irregular.

hyperthyroidism and persists after the thyrotoxicosis has been controlled by thyroidectomy, propyl thiouracil or radioactive iodine. Quinidine can be employed also in cases of auricular fibrillation due to organic heart disease when the arrhythmia is known to be of recent origin and is not associated with mitral stenosis, congestive heart failure or more than slight cardiac enlargement. A history of an earlier embolic accident contraindicates its use. Administration of the drug should be preceded by complete digitalization, and maintenance amounts of digitalis should be given throughout the period of therapy. The patient must be kept under close observation and should remain in bed each day until two hours after the last dose of quinidine. The best results seem to be obtained when the drug is given with an interval of two hours between doses. On the first day, two doses of 0.2 Gm. are administered as a test for possible hypersensitivity. If no symptoms develop, five doses of 0.4 Gm. are given on each of the following days, but if auricular fibrillation is still present at the end of five days, the drug is discontinued.

Auricular Flutter

Auricular flutter is much less common than auricular fibrillation and rarely occurs in the absence of organic heart disease. It is due to essentially the same type of auricular disturbance as auricular fibrillation but with the difference that regular auricular contractions of limited extent occur at a rate in the neighborhood of 300 or 350 per minute (fig. 7). Because a certain degree of auriculoventricular block is almost always present, the ventricular rate is slower than the auricular. When the degree of block is constant, the ventricular rhythm is regular, but when the block varies, an irregular rhythm results. If the auriculoventricular block is constant and of such a degree as to give a ventricular rate within the usual limits of normal, the presence of auricular flutter may be overlooked and first discovered only when an electrocardiogram is taken because of associated organic heart disease. Occasionally, in cases of this kind, however, careful inspection of the venous pulsations in the neck may reveal three or four or even more auricular pulsations to each ventricular wave.

When auricular flutter is present with a regular rhythm and a ventricular rate of 120 to 180 beats per minute it must be differentiated from sinus tachycardia and auricular paroxysmal tachycardia. In auricular flutter the ventricular rate remains constant within narrow limits and is not affected appreciably by exercise. This is in contrast to the variability of the rate in sinus tachycardia but does not aid in distinguishing the condition from auricular paroxysmal tachycardia. In auricular flutter pressure on the right or left carotid sinus may cause transient slowing of the heart or abrupt standstill of short duration followed by resumption of the original rate. The first of these responses may also be obtained in patients with sinus tachycardia but the second does not occur. In auricular paroxysmal tachycardia, pressure upon the carotid sinus either causes an abrupt reversion to normal sinus rhythm or has no effect at all.

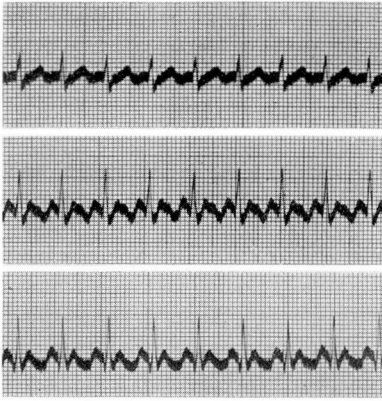

FIG. 7. Auricular flutter with 2:1 block. The ventricles respond to every second flutter wave. The flutter waves are triangular in shape, perfectly regular, and not separated by an isoelectric interval.

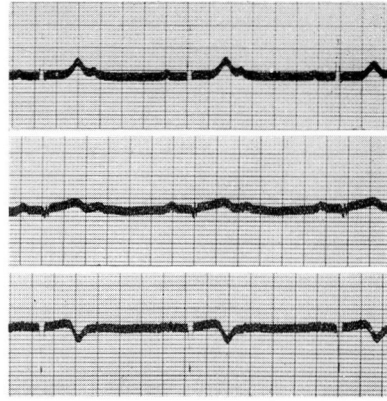


FIG. 8. 2:1 auriculoventricular block. Every second auricular impulse is blocked at the A-V node, and the corresponding ventricular beat fails to occur.

When the degree of auriculoventricular block in auricular flutter is variable, the ventricular rhythm is irregular and may suggest auricular fibrillation. Careful auscultation usually enables one to detect an underlying dominant rhythm, however, and this distinguishes the condition from auricular fibrillation. Furthermore, pressure upon the carotid sinus in auricular fibrillation has neither of the effects upon the rate of the ventricles which occur in auricular flutter.

Although the administration of quinidine sulfate may convert auricular flutter to sinus rhythm, the treatment of choice consists of rapid digitalization. In successful cases, digitalis converts auricular flutter to auricular fibrillation,

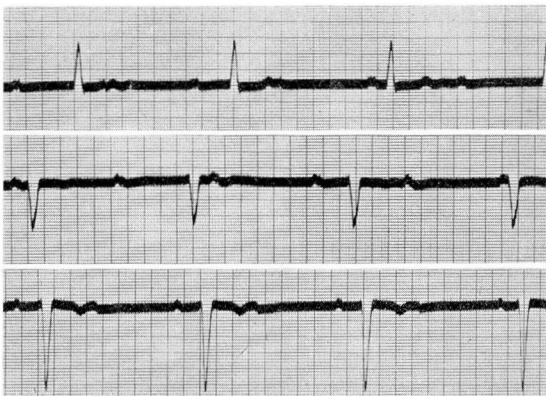


FIG. 9. Complete auriculoventricular block. All auricular impulses are blocked at the A-V node, and the activity of the ventricles is governed by an ectopic focus in the bundle of His.

and discontinuance of the drug may then be followed by spontaneous resumption of normal rhythm. If the flutter persists, digitalis is continued in the amount required to maintain sufficient auriculoventricular block to result in a ventricular rate of 100 beats per minute or less.

Auriculoventricular Block

Auriculoventricular block may be of any degree from simple lengthening of auriculoventricular conduction time to complete dissociation of the auricles and ventricles. Prolonged conduction between the auricles and ventricles, termed first degree auriculoventricular block, can be recognized with precision only by means of the electrocardiogram. The higher grades of block, namely second degree block with occasional or regularly recurring dropped beats and complete auriculoventricular dissociation, often can be diagnosed from the findings on auscultation of the heart. When there are occasional dropped beats, one must be sure that an early and faint premature beat is not being overlooked. In 2:1 block (fig. 8), the ventricular rate is slow, usually in the neighborhood of 40 per minute, and an extra heart sound may be audible shortly after the second sound. This results from those auricular contractions which are not followed by a ventricular response. In complete auriculoventricular block (fig. 9), the ventricular rate is usually less than 40 per minute. The extra sounds due to the auricular beats can be detected at times, and there usually is an occasional accentuation of the first sound at the apex due to the chance occurrence of practically simultaneous contraction of the dissociated auricles and ventricles.

Complete auriculoventricular block and second degree block with a slow ventricular rate must be distinguished from sinus bradycardia. This may not be possible by physical examination unless the auscultatory signs mentioned are present or unless one can detect extra auricular waves on inspection of the jugular pulse. Diagnostic help may be obtained, however, from the fact that in complete block exercise causes little or no change in the ventricular rate, but in sinus bradycardia a distinct increase in rate usually results.

In patients who have myocardial insufficiency, the presence of auriculoventricular block does not contraindicate the administration of digitalis. When the block is of first or second degree, digitalization should be accomplished gradually, and the effect of the drug should be observed by daily electrocardiograms. If the degree of block increases, it may be advisable to be satisfied with less than complete digitalization.

The higher grades of auriculoventricular block, and particularly complete auriculoventricular dissociation, may be complicated by the Adams-Stokes syndrome due to sudden slowing of the ventricular rate, temporary standstill of the ventricles, or the occurrence of ventricular paroxysmal tachycardia. The attacks are characterized by faintness, dizziness, syncope, or convulsions, depending on the extent to which cerebral circulation is diminished. Adams-Stokes seizures are rare, but individuals in whom they occur are liable to have repeated attacks. The actual seizures usually are of such short duration that they do not require treatment, but in rare instances ventricular standstill is of

sufficient duration to threaten life, and the intracardiac injection of epinephrine hydrochloride, 0.5 to 1.0 cc. of 1:1000 solution, is indicated. The most effective drugs for preventing recurrent attacks due to sudden ventricular slowing or ventricular asystole are epinephrine hydrochloride, 0.3 to 1.0 cc. of the 1:1000 solution, subcutaneously or intramuscularly every two to four hours, ephedrine sulfate by mouth in doses of 24 to 30 mg. every four to six hours, and paredrine by mouth in doses of 40 to 60 mg. three times a day.

Summary

The clinical features and treatment of the various types of cardiac arrhythmia have been discussed. The two most valuable drugs in treatment are digitalis and quinidine sulfate and the indications for their administration have been reviewed.

The clinical characteristics of the disturbances of cardiac rhythm have been so well established that it is possible to recognize most of them without mechanical aid. Premature beats, auricular paroxysmal tachycardia, ventricular paroxysmal tachycardia, auricular fibrillation, auricular flutter, and high grade or complete auriculoventricular block usually can be detected by careful physical examination alone. Electrocardiographic corroboration of the diagnosis is always desirable, but the electrocardiogram is of much greater value today in the detection of heart muscle damage and disturbances of intraventricular conduction than in the differentiation of the cardiac arrhythmias.

References

1. Weisberger, A. S., and Feil, H.: Lanatoside C in treatment of persistent paroxysmal auricular tachycardia. *Am. Heart J.* **34**:871-877 (Dec.) 1947.
2. Youmans, W. B., Goodman, M. J., and Gould, J.: Neosynephrine in treatment of paroxysmal supraventricular tachycardia. *Am. Heart J.* **37**:359-373 (March) 1949.
3. Levine, S. A.: Treatment of acute coronary thrombosis. *J.A.M.A.* **99**:1737-1740 (Nov.) 19, 1932.
4. Gold, H. et al: Management of disorders of cardiac rhythm. *Am. J. Med.* **5**:110-125 (July) 1948