

PIGMENTED TUMORS OF THE CENTRAL NERVOUS SYSTEM

JOHN T. BAKODY, M.D.*

Former Fellow in Neurosurgery

JOHN B. HAZARD, M.D.

Department of Pathology

and

W. JAMES GARDNER, M.D.

Department of Neurosurgery

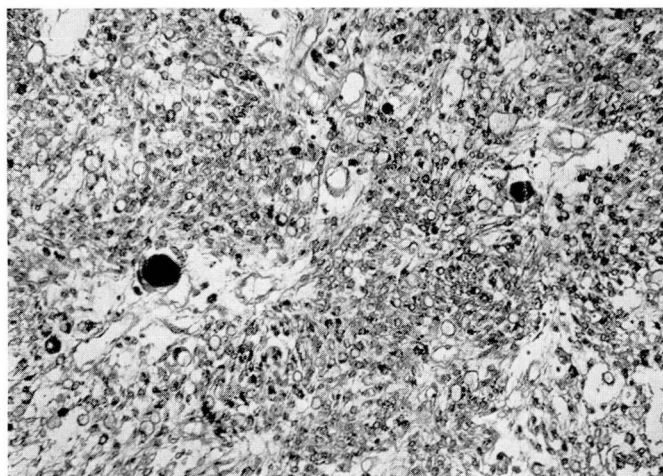
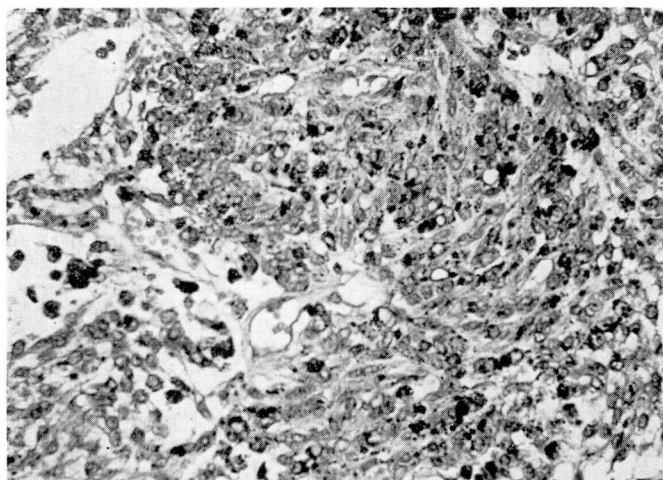
PIGMENTED tumors of the central nervous system include the pigmented meningioma, primary leptomeningeal melanoma, and secondary malignant melanoma. Although the last group is commonly recognized, the first two are not so well known. In 1940, Ray and Foot¹ reported two instances of primary melanotic tumors of the meninges resembling meningiomas. One case in this category will be presented. While there has been some controversy over the existence of primary leptomeningeal melanoma, several well-documented cases have been described^{2,3,4,5} and now appear in some texts.⁶ One instance will be described briefly, although it has already been reported in detail by Netherton.⁷ Secondary malignant melanoma of the central nervous system makes up the third group; this is by far the most common of the pigmented tumors and similar series have been reported by other authors.^{8,9,10,11,12,13} No attempt to debate the various theories of origin for the melanoma will be made, as this aspect of the problem has been extensively dealt with previously.^{14,15,16,17}

Pigmented Meningioma

Schnitker and Ayer¹¹ in 1938 described a case which they stated resembled an "atypical meningioma from examination of the surgical specimen alone", but which they designated malignant melanoma. Ray and Foot¹ reported a tumor of the spinal cord and a posterior fossa neoplasm, with surgical removals and 5 and 2 year survivals respectively at the time. Both tumors were said to resemble pigmented meningiomas and Foot¹⁸ later classified these two atypical growths as such. In the present case, the post-operative course and survival were characteristic of a benign neoplasm and the histologic configuration was in all ways compatible. So far as can be determined from a review of the literature, this represents the third reported instance of pigmented meningioma. The importance of recognition of this group of pigmented tumors is obvious.

*Now practicing in Des Moines, Iowa.

(a)



(b)

Fig. 1. (a) Pigmented meningioma, showing intracytoplasmic pigment in the meningeothelial cells. (b) Psammoma bodies in the pigmented meningioma.

Case Report

A white laborer, aged 45, entered the Cleveland Clinic complaining of low back pain and left sciatica. Two years previously he first noted pain down the left lower extremity and numbness along the outer aspect of the left lower leg and foot. The leg pain followed an injury to the back after having lifted a 100 pound sack of potatoes; at the time he felt something snap in his back. The leg pain was aggravated by coughing and sneezing. Shortly thereafter the patient developed numbness of the right foot, and some pain behind the right knee when he coughed or sneezed. The strength of the left lower extremity was impaired. There were no sphincter disturbances except for a short period of urinary retention following a novocain injection (caudal block?) given elsewhere for the relief of

pain. The weakness of the left leg had progressed so that he required crutches when walking.

The general physical examination was essentially normal. Blood pressure 150/90. There was a draining sinus above the thyroid gland which had been present since the opening of a cyst some time previously. Neurologic examination was normal except for the back and lower extremities. There was severe weakness and wasting of the left thigh, calf, and foot, absence of the left patellar reflex and of both Achilles reflexes. There were paresthesias radiating into both feet, and hyperesthesia of the anterolateral aspects of the left lower leg and foot. The pain in the leg was not intensified by compression of the jugular veins. Routine laboratory studies were entirely normal. The spinal fluid examination showed no cells, a trace of globulin, and 30 mg. per cent of protein. Lumbosacral x-rays were interpreted as normal.

The patient was admitted to the hospital and lumbar myelograms showed obstruction of the dye medium at the level of the joint space between the second and third lumbar vertebrae. With a working diagnosis of either protruded intervertebral disk, or spinal cord tumor such as neurofibroma, lumbar laminectomy was carried out. No extradural mass

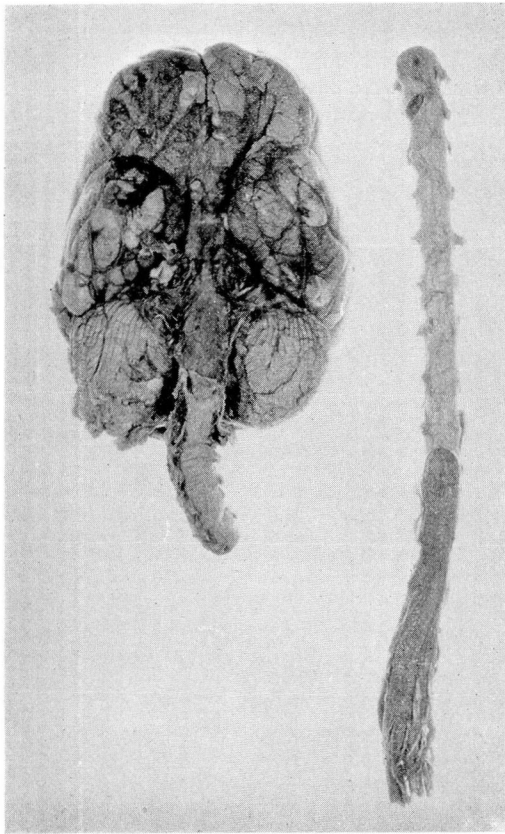


Fig. 2. Primary leptomeningeal melanoma, showing the diffuse leptomeningeal pigmentation of the brain, the subdural mantle of melanoma about the lower cord and cauda equina.

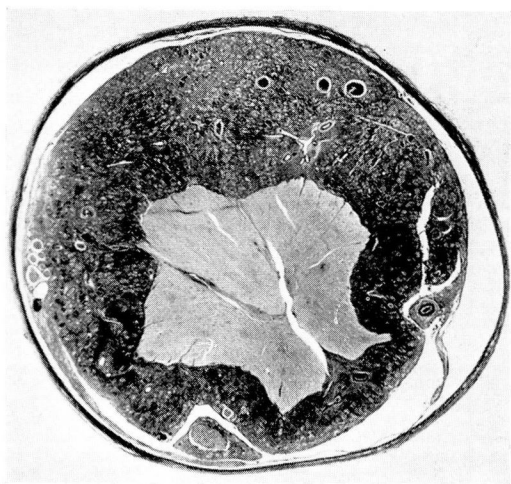


Fig. 3. Primary leptomeningeal melanoma. Cross section of the spinal cord, showing the annular subdural disposition of the melanoma.

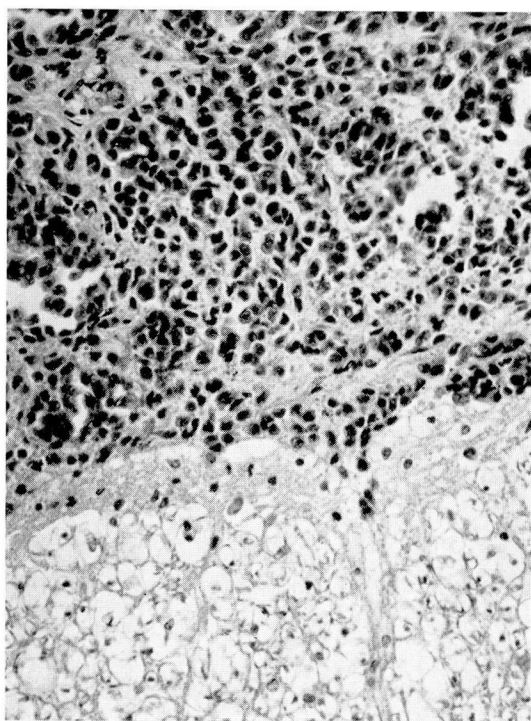


Fig. 4. Nevus-like cells densely infiltrating leptomeninges and sharply demarcated from the cord substance.

was found. The dura was opened to disclose a large, slate blue, rubbery tumor mass, filling the spinal canal from L-2 to L-4. The tumor appeared to be well-encapsulated, and about 5 cm. in length. To effect removal, the right third lumbar root was divided between silver clips, the tumor capsule was incised, the interior evacuated, and the capsule excised along with a circular area of dura. The tumor appeared to extend through the intervertebral foramen on the right, and to lie partly paravertebrally. Because frozen section study was reported as melanoma, the operation was abandoned at this point.

The postoperative convalescence was uneventful. There was a definite foot-drop on the left, and an orthopedic appliance was prescribed. When last heard from, 8 years after the operation, the patient's wife reported that he had gained 53 pounds over his previous best weight, and that his general condition was excellent. He had not completely regained the use of the left lower extremity but was free from pain.

In May 1947, 6 years after operation, one of us (J. B. H.) reviewed the microscopic sections to make a diagnosis of pigmented meningioma.

Pathology

The gross specimen consisted of multiple small portions of velvety, blackish-brown material, portions of which were covered by a tannish-brown fibrous capsule.

Microscopically the neoplasm was formed by cells of meningotheial type, polyhedral and spindle-shaped, 10 to 12 microns in width and up to approximately 40 microns in length, arranged as compact dark staining sheets with irregular pale staining zones (fig. 1a). The cell cytoplasm was moderately abundant, for the most part dark staining in the compact zones, and often containing fine granules or irregular, small clumps of brown, nonrefractile pigment. The cell nuclei were round or oval, well differentiated, generally without prominent nucleoli, and frequently pale or vesicular as if containing a large clear vacuole. No mitoses were apparent. The pigment retained its brown appearance after stains for iron. The vessels were rather evenly dispersed and of simple character. Scattered, small, round psamomma bodies were present (fig. 1b). There was a slight tendency to whorl formation. Architecturally, the neoplasm most typically resembled the type I, variant 4 meningioma of Cushing and Eisenhardt.¹⁹

Discussion

Differentiation between the pigmented meningioma and tumors of the melanoma group is relatively easy due to the rather typical meningotheial appearance of the cells, the uniform and sheet-like arrangement of the tumor, and the lack of nuclear dedifferentiation. Except for the presence of the intracellular pigment, the neoplasm is characteristically meningioma.

Primary Leptomeningeal Melanoma

Cases of primary leptomeningeal melanoma have been described by Ford,⁶ Akelaitis,²⁰ Shapiro and Kellert,⁴ Da Costa and Love,²¹ Wilcox,²² Winkelman, Gotten and Silverstein,¹⁷ Farnell and Globus,² and Kessler.³ The following case has been reported previously.⁷

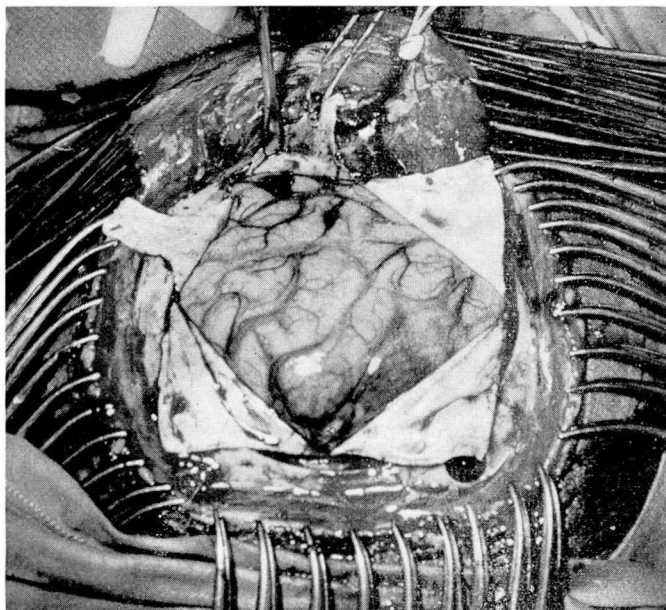


Fig. 5. Case 1. Secondary malignant melanoma. Gross appearance of cortical melanotic lesion at time of left parietal craniotomy.

A 17 year old white man reported to the Clinic complaining of blurring of vision, headache, poor memory, vomiting and occasional numbness of the right hand, all of 7 weeks' duration. Bilateral papilledema with xanthochromic spinal fluid under 700 mm. water pressure was found. He had a hairy mole which had been present since birth covering about one-third of the body surface. Observation of pneumoencephalograms indicated an obstructive hydrocephalus. Suboccipital craniotomy and cerebellar exploration were carried out (W. J. G.) and a bluish-gray mantle was found covering the posterior surface of the medulla, suggesting an angioma. One month later, cervical laminectomy revealed extension of the previously noted bluish-gray, subdural, extramedullary mass. Two weeks later the patient died and an autopsy was performed.

Pathology

The autopsy findings were briefly as follows:

Over the lower part of the face and the upper part of the chest, both anteriorly and posteriorly, there was a large, diffusely distributed and darkly pigmented nevus. There were many smaller, similar pigmented areas scattered over the body, varying in size from 1.0 to 5.0 cm. in diameter, and covered by an abundance of coarse, black hair. The brain weighed 1565 Gm. The dura was essentially normal. The pia arachnoid over the base of the brain was slightly thickened, opaque, and of brown appearance (fig. 2). From the optic chiasm back to the pons and medulla, the pia arachnoid was thickened and brown. The dura of the spinal cord was normal. On opening this a mantle of grayish-brown tissue was disclosed, apparently occupying the

site of the pia arachnoid, completely surrounding the cord from the level of the medulla to the cauda equina and varying in thickness from 1.0 to 5.0 mm. The greatest thickness was from the midcervical to the lumbar region. The dura stripped without difficulty from this tumor mantle and was not infiltrated at any point. The spinal nerves were surrounded by tumor tissue as they emerged from the cord, but otherwise were distinct from it. The cord was of fairly normal outline, and its anatomic markings were not unusual. There was no apparent reduction in the size of the spinal cord so far as the upper cervical region was concerned; the lower cervical region, however, presented some distortion of the cord with an irregularity of its shape (fig. 3) a diminution in the size, and some loss of the normal anatomic markings. Grossly, however, there was little or no infiltration by tumor.

Microscopic examination of sections from the cerebral cortex, olfactory bulb, thalamus, pons, medulla, and cerebellum showed small, round, or polyhedral cells occurring in groups or diffusely distributed in the leptomeninges. In some areas these cells were numerous, producing severe thicken-

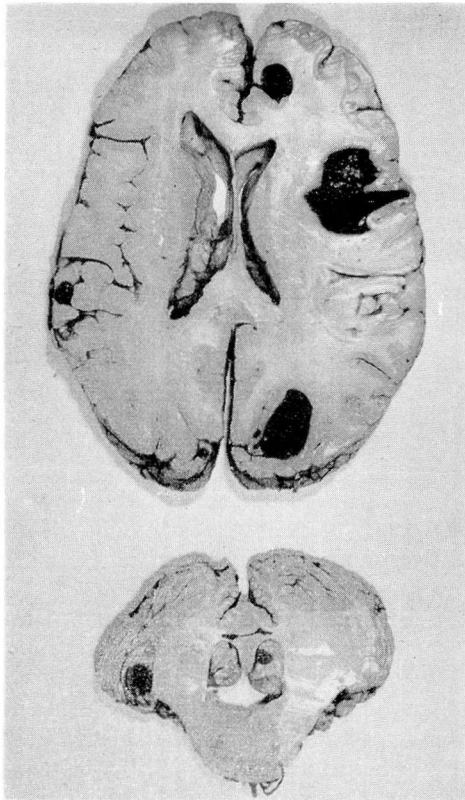


Fig. 6. Case 2. Secondary malignant melanoma, nodular metastases in brain.

ing of the leptomeninges and extending along pial vessels into the brain tissue but usually well delimited from this. The cells possessed little cytoplasm and the nuclei were of irregular configuration, dark staining and without prominent nucleoli or mitoses. The cells were separated in part by an increased connective tissue of the leptomeninges and in the connective tissue were occasional cells of chromatophore type laden with fine, brownish, nonrefractile pigment granules which gave a negative reaction for iron. Sections through the spinal cord presented similar but more intense infiltration of the leptomeninges by the nevus-like cells described above. These surrounded nerves but did not penetrate them, and the sheath of cells was generally well demarcated from the spinal cord substance (fig. 4).

The leptomeninges were sharply delimited from the subdural space and in no instance was the dura infiltrated. The cells forming the mantle about the spinal cord revealed variations in size and staining property and rarely there were mitoses. However, nuclear dedifferentiation was never severe. The anatomic diagnoses were: primary leptomeningeal melanoma, diffuse, of brain and spinal cord; pigmented nevus, diffuse, of face and chest; pigmented hairy nevi, multiple.

It is thought that a growth, such as was found in this case, arises from the leptomeningeal chromatophores. The usual clinical picture is that of increased intracranial pressure, stiff neck, sterile xanthochromic spinal fluid and mental clouding, i.e. a "tumor meningitis."

The cells almost exclusively infiltrate the leptomeninges with little or no penetration of brain or cord substance. Nuclear dedifferentiation is not that which is found in true malignant melanoma. In general, there is no indication of growth activity except for a rare mitosis. The aggressiveness of true malignant melanoma is not evident in any area.

A primary leptomeningeal origin cannot be accepted as such unless a careful search fails to disclose a primary malignant lesion in the eye, skin or visceral organs and even then, the presence of intracerebral melanotic nodules would challenge an interpretation of primary origin.

Secondary Malignant Melanoma

Grant¹² reported 7 cases of melanotic sarcoma from the neurosurgical service of Peter Bent Brigham Hospital occurring from 1914 to 1926. There were 49 metastatic intracranial lesions in the 13 year series, making a 14 per cent incidence for the melanotic tumors. In 1932, Dunlap¹³ reported on 95 metastatic tumors of the brain, citing only 2 cases of melanoma (2.1 per cent incidence). In 1939, Courville and Schillinger⁹ reviewed 18 cases of metastatic melanoma of their own. Fourteen were included from a series of 1060 cases of intracranial tumors registered in the Cajal Laboratory and as part of a group of 107 metastatic tumors (12 per cent incidence for melanomas in the group of metastatic neoplasms, and 1.3 per cent of intracranial tumors in general). In 1940, Moersch, Love, and Kernohan¹⁰ found 34 cases

(in 19 of which the diagnosis was verified by operation or necropsy) of metastatic involvement of the central nervous system in a general group of 500 melanomas seen from 1930 to 1939. Of those melanomas showing local recurrence or metastases, 10 per cent involved the central nervous system.

Fourteen cases of secondary malignant melanomas of the central nervous system were encountered at the Clinic in a group of 85 metastatic tumors occurring in 1294 intracranial neoplasms. Of these the following 3 cases are presented.

Case Reports

Case 1. A 40 year old white man was admitted to the hospital because of a progressive right spastic hemiplegia, aphasia, headache and mental changes of one month's duration. Air studies showed a ventricular shift to the right. A left parietal craniotomy disclosed a coal black melanoma in the cortex (fig. 5). Following surgery, the patient's wife gave the further history of the removal of an enlarging dark mole from the skin and the appearance 4 months previously of a pigmented spot on the nose. Death occurred on the second postoperative day. No autopsy was performed.

Case 2. A 64 year old white woman was seen at the Clinic with a 3 months' history of progressive mental deterioration, left lower facial weakness, dysphagia, and generalized weakness. She was arteriosclerotic, and this was thought to have etiologic implications until 4 days later when the patient became stuporous and lumbar puncture revealed xanthochromic fluid under increased pressure. By this time she had developed a left hemiparesis and left Jacksonian convulsions. A right parietal craniotomy disclosed a large right subcortical hematoma which was evacuated. She died with hyperthermia in 2 days. An autopsy revealed multiple cerebral (fig. 6) and extensive visceral metastatic lesions with extension of tumor about vessels adjoining neoplasm. The primary site could not be determined.

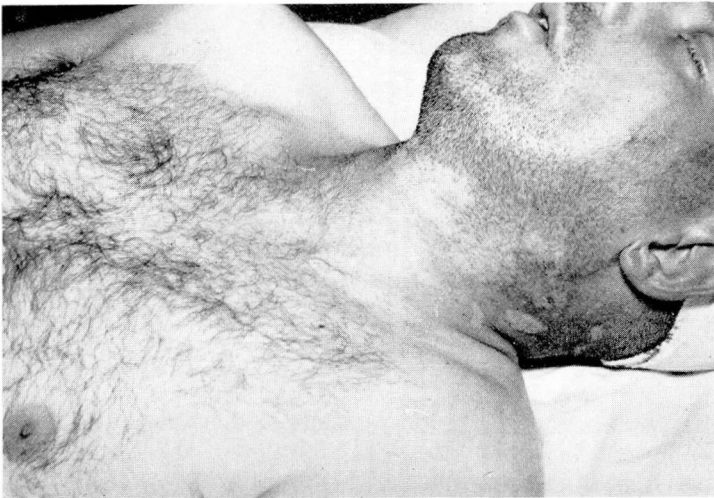

Fig. 7. Case 3. Secondary malignant melanoma. Vitiligo and patchy depigmentation of the hair of the chest and the eyelashes. Onset of vitiligo coincided with the development of central nervous system symptoms from metastatic melanoma.

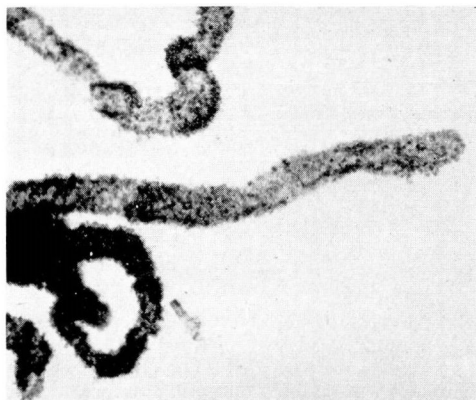


Fig. 8. Case 1. Secondary melanoma from brain. Teased preparation showing sheath-like formations about vessels.

Case 3. A 29 year old white man entered the hospital complaining of headache, left Jacksonian seizures, and progressive weakness of the left extremities of 3 months' duration. The examination showed a left hemiparesis with increased intracranial pressure. It was noted that the patient had vitiligo and depigmentation of the eyelashes and hair over the chest (fig. 7). There were no nevi in the skin lesions. This skin difficulty was coincident with the onset of headaches 3 months previously. The electroencephalogram showed right cerebral localization. The patient became less responsive, and a right frontal craniotomy was performed. A reddish brown, vascular subpial tumor was enucleated along with a recent subcortical clot. Pathologic examination revealed malignant melanoma showing extensive necrosis and zones of hemorrhage. After surgery the family gave the information that 18 months before his examination here a pigmented nevus was surgically excised from the back, and a diagnosis of melanotic sarcoma had been made. The patient was still living 3 months following surgery.

Discussion

In this present series the metastatic lesions to the brain occurred as multiple, circumscribed, though not encapsulated, nodular areas (figs. 5 and 6) of variable size and in most instances of brown or black coloration, but occasionally presenting a gray or white appearance. The tissue on section was soft, friable and often characterized by severe hemorrhage, both within the tumor and in the adjoining brain tissue, at times sufficient to grossly obscure the underlying neoplasm. Microscopically the tumor was typical of malignant melanomas found in other locations. The cells were rounded, polyhedral, or spindly-shaped, and varied in size from 10 or 12 microns to large cells 25 or 30 microns in diameter. The nuclei presented dedifferentiation, evidenced by the presence of prominent nucleoli, vesicularity of the nuclei, and mitoses which often were of atypical character. The cells were arranged in either broad sheets or in groups, the latter being most evident in the regions in which the connective tissue coverings of the brain were infiltrated. In one instance tumor cells were practically obscured by the presence of dense masses of brown, nonrefractile intracellular pigment. In

other instances there was a moderate to intense fine granular pigmentation of the individual cells and of chromatophores in connective tissue adjoining the tumor. Rarely the pigment was sparse, occurring in relatively few cells, broad areas of the tumor showed no pigmentation. Stains for iron were negative except in an occasional focus of old hemorrhage.

The brain tissue adjoining the tumor was infiltrated by solid tumor masses and did not show a diffuse single cell infiltration. A prominent feature in some cases was tumor extension along the vessels of adjoining brain tissue, the neoplastic cells forming a thin sheath encasing the vessel (figs. 8 and 9).

The clinical diagnosis of secondary malignant melanoma of the central nervous system is not easy, although it can be made more frequently if the possibility is kept in mind. A history indicating the presence of a malignant or suspiciously malignant mole or a tumor of the choroid is of course of paramount importance. The confirmation, or final diagnosis, is made either by surgical biopsy or autopsy examination.

The important clinical features of the 14 cases is summarized in the following:

The age incidence varied from 29 to 67 years, averaging 42 years. Sixty-four per cent were men, and all were of the white race. Eighty-five per cent had evidence of increased intracranial pressure, either papilledema, elevated spinal fluid pressure, or both; 8 of the patients had convulsive seizures, either focal or generalized, while in 1 case the history of convulsions was questionable. Either before or after operation the recent growth of a skin

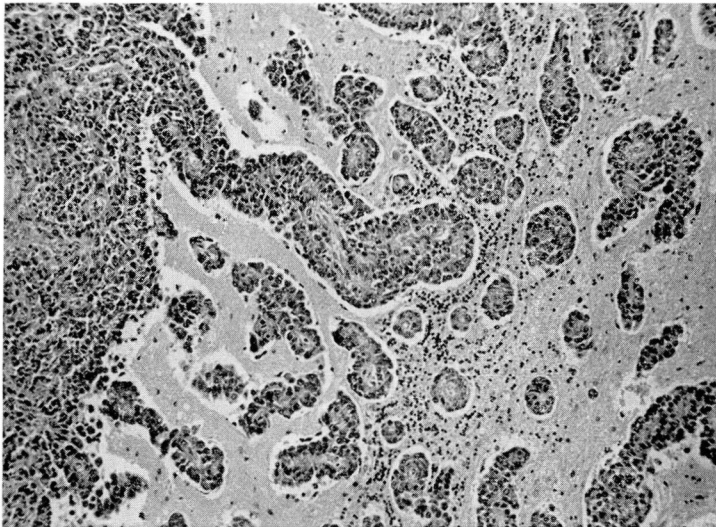


Fig. 9. Case 2. Secondary malignant melanoma. Perivascular cuffs of tumor cells about cerebral vessels near metastatic nodule.

mole was related in 9 of the group and 7 patients had previous excision or cauterization of a pigmented nevus. The skin was known to have been the primary site in 9 patients, the left eye in 2, and in 3 the site of the primary lesion was not known. The onset of vitiligo, with depigmentation of the eyelashes and hair over the chest (fig. 7) coincided with the onset of headaches in 1 case. Melanuria was found in 2 of the 3 cases in which attempts were made to identify melanin in the urine; the spinal fluid showed a negative test for this pigment in the 4 where it was sought. Xanthochromic spinal fluid was present in 5 of the patients. The spinal fluid protein was 50 mg. or greater in 8 of the 11 cases in which it was determined. Chest roentgenograms were reported normal in 8, one showed evidence of metastases, the diagnosis of metastasis was questionable in another, and there was one instance in which the chest was normal on first examination but showed metastatic lesions 4 months later; no record of chest x-ray examination was found for 3 patients.

Surgical therapy fails to cure the patient, and x-ray therapy is valueless.

Summary and Conclusions

Pigmented tumors of the central nervous system are presented as 3 entities; pigmented meningioma, primary leptomeningeal melanoma, and secondary malignant melanoma.

An example of a pigmented meningioma is described with the histologic diagnosis made on re-examination of the surgical specimen 6 years following the first and erroneous diagnosis of melanoma. If this unusual tumor had not been pigmented, it most likely would have been identified by the surgeon as a meningioma or neurilemmoma, but the inclusion of melanin pigment by the tumor cells made confusion with the melanomas certain.

A single example of primary leptomeningeal melanoma is briefly presented in which the patient had an associated extensive pigmented cutaneous nevus. Either the association of the cutaneous and neural lesions was a coincidence, or the cutaneous and neural lesions were related congenital malformations as part of a developmental ectodermal disturbance.

Fourteen cases of secondary malignant melanoma are discussed. Attention is called to the importance of melanotic neural metastases. This likelihood should constantly be considered in the differential diagnosis of cerebral neoplasm.

References

1. Ray, B. S., and Foot, N. C.: Primary melanotic tumors of meninges; resemblance to meningiomas; report of 2 cases in which operation was performed. *Arch. Neurol. and Psychiat.* 44:104 (July) 1940.
2. Farnell, F. J., and Globus, J. H.: Primary melanoblastosis of leptomeninges and brain. *Arch. Neurol. and Psychiat.* 25:803 (April) 1931.
3. Kessler, M. M.: Melanoblastosis and melanoblastoma; primary and secondary involvement of the brain; anatomic study. *Am. J. Cancer* 30:19 (May) 1937.

4. Shapiro, J., and Kellert, E.: Primary melanoblastosis of meninges. *New York State J. Med.* 37:2096 (Dec. 15) 1937.
5. Bailey, P., and Bucy, P. C.: Origin and nature of meningeal tumors. *Am. J. Cancer* 15:15 (Jan.) 1931.
6. Ford, F. R.: *Diseases of Nervous System in Infancy, Childhood, and Adolescence.* Springfield, Charles C Thomas, 1946, p. 821.
7. Netherton, E. W.: Extensive pigmented nevus associated with primary melanoblastosis of leptomeninges of brain and spinal cord; report of case. *Arch. Dermat. and Syph.* 33:238 (Feb.) 1936.
8. Wortis, H., and Wortis, S. B.: Metastatic melanoma involving central nervous system. *Arch. Neurol. and Psychiat.* 36:601 (Sept.) 1936.
9. Courville, C. B., and Schillinger, R. J.: Metastatic melanoblastomas of brain; review of literature and survey of 18 cases. *Bull. Los. Angeles Neurol. Soc.* 4:8 (March) 1939.
10. Moersch, F. P., Love, J. B., and Kernohan, J. W.: Melanoma of central nervous system; report of 34 cases, in 19 of which diagnosis was verified by operation or necropsy. *J. A. M. A.* 115: 2148 (Dec. 21) 1940.
11. Schnitker, M. T., and Ayer, D.: Primary melanomas of leptomeninges; clinico-pathologic study with review of literature and report of additional case. *J. Nerv. and Ment. Dis.* 87:45 (Jan.) 1938.
12. Grant, F. C.: Intracranial malignant metastases; their frequency and value of surgery in their treatment. *Ann. Surg.* 84:635 (Nov.) 1926.
13. Dunlap, H. F.: Metastatic malignant tumors of brain. *Ann. Int. Med.* 5:1274 (April) 1932.
14. Ewing, J.: *Neoplastic Diseases. A Treatise on Tumors*, ed.4. Philadelphia, W. B. Saunders Company, 1940, p. 948.
15. Dawson, J. W.: Melanomata; their morphology and histogenesis; study of cell origins and transformations with critical discussion on aspects of tumour growth and clinical review. *Edinburgh M. J.* 32:510 (Oct.) 1925.
16. MacLachlan, W. W. G.: Extensive pigmentation of brain associated with nevi pigmentosi of skin. *J. M. Research* 29:433 (Jan.) 1914.
17. Winkelman, N. W., Gotten, N., and Silverstein, A.: Primary melanoblastosis of meninges. *Arch. Neurol. and Psychiat.* 35:919 (April) 1936.
18. Foot, N. C.: *Pathology in Surgery.* Philadelphia, J. B. Lippincott, 1945, p. 431.
19. Cushing, H., and Eisenhardt, L.: *Meningiomas; Their Classification, Regional Behavior, Life History, and Surgical End Results.* Springfield, Charles C. Thomas, 1938, p. 37.
20. Akelaitis, A. J. E.: Primary melanosarcoma of leptomeninges. *Am. J. Path.* 11:594 (July) 1935.
21. Da Costa, D. G., and Love, J. G.: Primary melano-epithelioma of spinal cord. *Proc. Staff Meet. Mayo Clin.* 14:628 (Oct. 4) 1939.
22. Wilcox, J. C.: Melanomatosis of skin and central nervous system in infants; congenital neurocutaneous syndrome. *Am. J. Dis. Child.* 57:391 (Feb.) 1939.