

# MASSIVE UPPER GASTROINTESTINAL HEMORRHAGE

## *The Selection of Patients for Emergency Operation*

STANLEY O. HOERR, M.D.  
Department of General Surgery

**S**UDDEN massive hemorrhage from the upper gastrointestinal tract is an unwelcome emergency. It is no longer sound practice to treat every patient with this condition by conservative measures, and the physician therefore is taxed with a delicate question: Which patient will require an emergency operation to save his life? The problem is rendered no less difficult by the fact that it is only the occasional patient—less than one in ten—in whom such an operation will be necessary. The physician (and the term is used to include family physician, internist, gastroenterologist or surgeon) should adopt the view that emergency surgery is to be performed only upon that patient who he believes may die without operation.

How can this occasional patient be selected for emergency operation? The crux of the matter is the **rapidity of the bleeding**. Other factors such as the duration of the hemorrhage, the age of the patient and the number of previous hemorrhages, are of secondary importance. The reasoning behind this view is that in slow hemorrhage, no matter how persistent, the physician can keep abreast of the bleeding with blood transfusion, and sudden circulatory collapse with death from exsanguination is unlikely. Occasionally a slow but persistent bleeder will require surgery while the bleeding is in progress (Case 3) but a more leisurely decision is then possible. The most reliable guide to the rapidity of the hemorrhage is the state of the circulation; in rapid hemorrhage, peripheral vascular collapse is present or impending.

It is rarely possible to decide within the first few hours of observation whether or not an emergency operation will be necessary. Many patients will experience weakness or syncope at the onset of a moderate or even a mild hemorrhage, often coincident with the effort of vomiting or moving the bowels. Recovery is usually prompt, and this initial syncope is not evidence in itself of a massive hemorrhage. Other patients will be in a state of clinical shock upon arrival at the hospital, but a single transfusion of 500 cc. whole blood is sufficient to bring the blood pressure back to normal and slow the pulse rate. The patient may remain in a stable circulatory state from then on. An occasional patient of this type may need as much as 1000 to 1500 cc. of blood within the first few hours before his circulation is stabilized (Case 1); if more than this is required one must fear that rapid hemorrhage is continuing and may prove fatal without operative intervention (Case 2).

Once the initial shock has been successfully combated, the physician must be prepared to play a waiting game. Nine out of 10 patients will either cease

bleeding promptly, or will bleed at rates which are compensated easily by a reasonable number of blood transfusions. We have found it useful to set a limit to the number of transfusions which the patient should require on a conservative regime. We have set this limit arbitrarily at 500 cc. of blood for every 8 hour period, day and night. If the patient is losing blood so rapidly that transfusions at this rate do not make up the loss, operative intervention should be contemplated.

How may one determine the rate of bleeding in the patient who is under observation and is receiving conservative therapy? Operation is to be considered for dangerously rapid bleeding under the following circumstances:

1. **Recurrence of syncope or shock.** Patients in whom this occurs are almost invariably bleeding from a single large vessel which temporarily closes off only to start again at an alarming rate. There may be a latent period of several days between hemorrhages, and it is not unusual for the untreated patient to have several such episodes. Such patients are in a precarious state and operative intervention is advisable barring special contraindications.

2. **A drop in systolic blood pressure or rise in pulse rate, especially if sudden.** Although less dramatic than syncope or shock the meaning is the same, and it usually presages recurrence or persistence of rapid bleeding. The blood pressure and pulse rate should be determined frequently at intervals varying from every 15 minutes to every 2 hours, depending on the circumstances, in the patient who is under observation for a serious hemorrhage. If instability of the circulation is manifested on the chart of a patient receiving 500 cc. of blood every 8 hours, it may be assumed that spontaneous cessation of the hemorrhage is unlikely and surgery should be considered.

3. **A progressive drop in the red cell count, hemoglobin and hematocrit determinations.** Hemodilution may continue for a day or longer after bleeding has ceased, if the hemorrhage has been severe, but a continued fall in serial determination over a period of days is evidence that conservative measures have not checked the hemorrhage.

4. **Recurrent hematemesis or melena.** Hematemesis in particular (or fresh blood recovered from gastric syphonage) gives first hand evidence of persistent hemorrhage. It is easy to overestimate the total blood lost in this manner, since it is invariably diluted with gastric juices and sometimes with ingested fluids. Repeated hematemeses in a period of a few hours, particularly when coupled with evidence of an unstable circulation, indicate that conservative treatment is not succeeding. Melena is a far less reliable sign, unless the patient is having stools every few hours; the latter is likely to be the case if a rapid hemorrhage is in progress.

### Contraindications to Emergency Operation

1. **Unknown source of bleeding.** The principle objective of an operation is to eradicate a localized source of the hemorrhage; this will usually be a duodenal or gastric ulcer, and less frequently a gastric neoplasm. The suitable operation is almost always a gastric resection, with direct control of the bleed-

ing in a duodenal ulcer if it cannot be resected with the stomach. Emergency operation is of no value in bleeding from esophageal varices, and its usefulness in gastritis with severe hemorrhage is still debated. Since esophageal varices and gastritis together account for about 15 per cent of all massive upper gastrointestinal hemorrhage, it is generally unwise to operate unless the lesion has been previously localized and identified by x-ray. It is therefore sometimes advisable to precede an emergency operation by an emergency x-ray, to determine by barium study if esophageal varices are present; if present, they are the presumptive source of hemorrhage, and other measures such as esophageal tamponade are in order. Although some surgeons will operate with a clinical diagnosis of duodenal ulcer, even if x-ray evidence is lacking, this is a risky procedure; it is perhaps safer for the patient to be maintained on a conservative regimen with the rate of transfusion increased to keep pace with the bleeding.

2. **Advanced coexisting disease.** Not infrequently massive hemorrhage (even from a duodenal ulcer) is a more or less terminal event in patients suffering from such diseases as chronic nephritis, severe hypertension, or leukemia. Emergency operation in such patients is hopeless and meddlesome.

3. **Enormous obesity.** Every surgeon is familiar with the greatly increased technical difficulties encountered in the obese, and there is a widespread impression that operative risk is increased also. In rare instances one may be justified in refusing to operate for these reasons.

### Case Reports

#### Case 1. Hemorrhage from duodenal ulcer; recovery without operation.

A 53 year old Greek restaurant owner was admitted to the Clinic Hospital on February 6, 1950, for emergency treatment of severe bleeding from the upper gastrointestinal tract. Within a period of 12 hours preceding his admission he had vomited blood, passed a tarry stool and fainted twice. He had suffered from periodic epigastric distress for about 5 years, and for about 1 year he had been taking baking soda to relieve his discomfort. There had been no previous hemorrhages and there had been no gastrointestinal x-ray studies. At the time of admission the physical examination revealed a cheerful, moderately obese middle-aged white man whose general condition appeared to be good. The blood pressure was 110/70 and the pulse rate 100. The abdomen was soft and nontender, there were no masses, and the liver and spleen could not be palpated. Tarry feces were present in the rectum. The red cell count was 4,100,000, the white cell count was 10,550 and the hemoglobin was 10.5 Gm. per 100 cc.

The patient was given a single transfusion of 500 cc. whole blood shortly after his admission, largely on the basis of the history (fig. 1). He was started on an ulcer feeding regimen with gelusil. A few hours after his transfusion the patient had a copious hematemesis (measured at 1100 cc.), passed a small, dark stool, the pulse rate rose to 122 and the blood pressure dropped to 88/64. Within the next 6 hours he received an additional 1500 cc. of whole blood with a satisfactory clinical response. Recovery was steady without further evidence of bleeding. Barium x-ray studies showed a constant deformity of the duodenum. He was discharged 14 days after his admission on a strict ulcer regimen. The patient was doing well when last seen 6 weeks after operation.

**Comment.** The patient presented a typical problem. This was an initial hemorrhage in an obese patient past 50 years of age, severe enough to have

**MASSIVE HEMORRHAGE FROM DUODENAL ULCER**

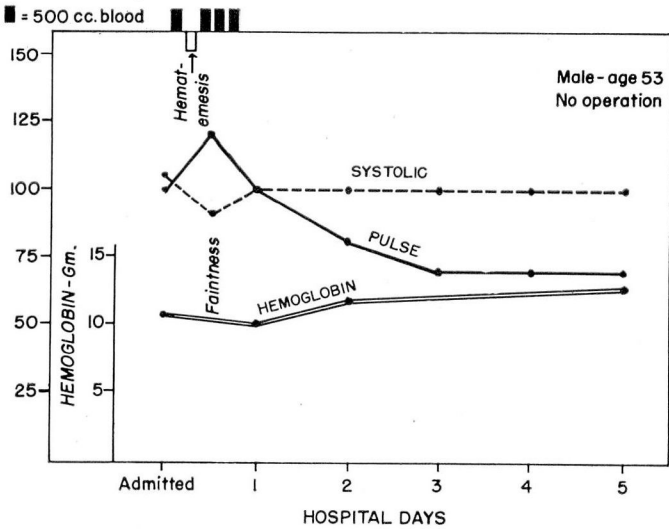


Fig. 1. Case 1. Schematic course of patient with sudden massive hemorrhage from duodenal ulcer. Conservative treatment.

**MASSIVE HEMORRHAGE FROM JEJUNAL ULCER**

**EMERGENCY GASTRIC RESECTION**

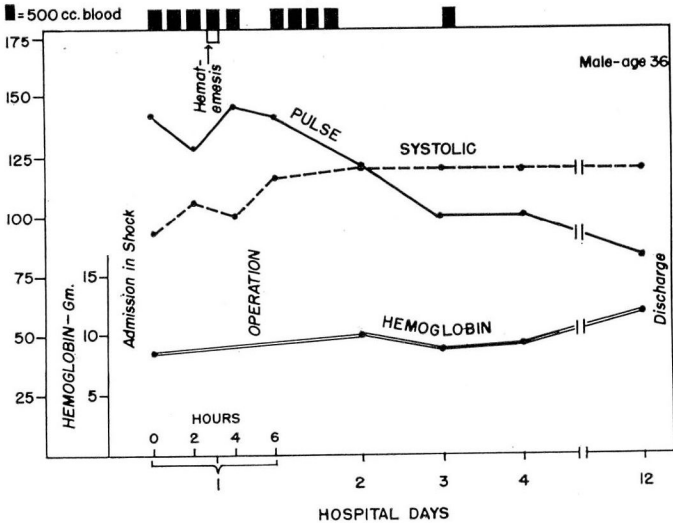


Fig. 2. Case 2. Schematic course of patient with sudden massive hemorrhage from jejunal ulcer. Emergency operation.

caused him to faint at home, and to reduce his blood pressure to shock levels shortly after he had been admitted. The source of the bleeding was not known, although the history suggested a duodenal ulcer. He needed 2 liters of blood to overcome the effects of the hemorrhage; this was given within the first 18 hours of his hospitalization. Had he required more blood that first day, or if he had bled again on ensuing days at a rate sufficiently rapid to compromise the stability of his circulation, an emergency operation would have been done, preceded by an emergency x-ray to rule out esophageal varicosities. As it was, the more desirable course could be followed—that of permitting the hemorrhage to cease spontaneously. Since this patient had never had systematic treatment for his duodenal ulcer, the gastroenterologist and surgeon agreed to follow his progress under ulcer management, and postpone surgical intervention indefinitely.

**Case 2. Hemorrhage from jejunal ulcer; recovery after emergency gastric resection.** A 36 year old single welder was admitted to the Clinic Hospital on January 3, 1950 for emergency treatment of a massive hemorrhage of 2 days' duration. He had had "stomach trouble" since the age of 18, and at the age of 30 a gastroenterostomy had been performed elsewhere for pyloric obstruction. For 2 weeks prior to admission he had been so weak that he had been unable to work. For 2 days he had been vomiting blood and the previous day had passed several tarry stools. He had been given a single blood transfusion at another hospital. Examination on admission revealed a pale, perspiring, apprehensive white man with a pulse rate of 144 and a blood pressure of 86/40. The abdomen had the scar of previous surgery, but was otherwise normal and showed no masses or tenderness when lightly palpated. The red cell count was 2,900,000, the white cell count was 16,800 and the hemoglobin 8 Gm. per 100 cc.

Whole blood transfusions were started promptly and the patient received 2000 cc. within the next 4 hours (fig. 2). The pulse rate dropped to 108 and the blood pressure rose to 118/68. Shortly after this, however, he vomited 400 cc. of bloody material, the pulse rate rose again to 144 and the blood pressure dropped to 100/70. An additional 500 cc. of whole blood was started and the patient was taken to the operating room. Under general anesthesia the abdomen was opened and a large, actively bleeding vessel in a jejunal ulcer promptly ligated. Immediately following the control of the bleeding he was given 2000 cc. of blood by arterial transfusion, and a subtotal gastric resection was carried out, with a jejunostomy for feeding purposes. His condition at the conclusion of the operation was better than it had been at the start. The patient received one more blood transfusion on his second postoperative day (making a total of 5000 cc.) and was discharged on the eleventh postoperative day with a red cell count of 4,200,000 and a hemoglobin of 12 Gm. per 100 cc.

When last seen 2 months after the operation his weight had increased 21 pounds and he was symptom-free.

**Comment.** This patient, in the opinion of all the physicians who examined him, would have died from exsanguination had there been no surgical intervention. It was a safe assumption, based upon the previous surgery, that the source of the bleeding was a jejunal ulcer, even though there was no direct x-ray evidence. Despite his comparative youth, there is little likelihood that the bleeding from a large branch of the middle colic artery (involved in the jejunal ulcer) would have stopped spontaneously. Although he was desperately ill at the time of operation, once the bleeding had been surgically arrested and his

blood volume restored by arterial transfusion, he easily withstood a complicated procedure rendered more difficult by the previous gastroenterostomy.

**Case 3. Chronic and acute hemorrhage from duodenal ulcer; recovery after emergency gastric resection.** A 59 year old Italian carpenter was admitted to the Clinic Hospital on January 20, 1950 for treatment of periarthrits of the left shoulder. He had had a known duodenal ulcer for at least 6 years, and passed occasional black stools. While undergoing hospital treatment for his shoulder he developed an exacerbation of his ulcer symptoms, and it was found that the red cell count was 2,200,000 and the hemoglobin 4 Gm. per 100 cc. A strict ulcer regimen was instituted and between January 26 and January 30 the patient received a total of 2750 cc. whole blood transfusions. This raised his hemoglobin level to 9.5 Gm. per 100 cc. On January 30, however, he passed a grossly bloody stool, the pulse rate rose to 120 and the blood pressure dropped temporarily to 80/50. He was taken to the operating room several hours later, and a subtotal gastric resection was carried out. A catheter duodenostomy was also

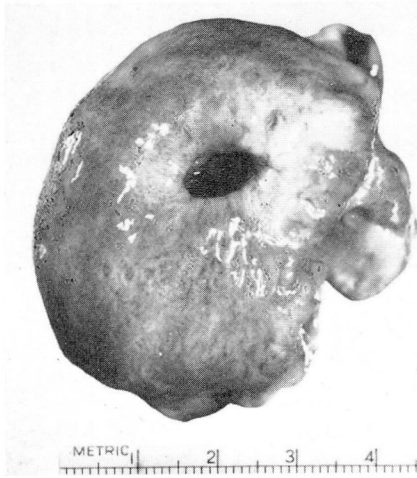

FIG. 3. Case 4. Leiomyoma of stomach which produced massive hemorrhage. Local resection spared the stomach.

performed (as advocated by Welch when the closure of the duodenal stump is difficult). Vessels in the ulcer bed were ligated, although there was no active bleeding at the time the ulcer was exposed. He received 1000 cc. of whole blood during the operation and a single transfusion of 500 cc. of blood on the third postoperative day. Recovery was entirely uneventful. It was possible to re-institute active treatment for the shoulder on the seventh postoperative day, and he was discharged asymptomatic on the thirteenth postoperative day with a hemoglobin of 10.8 Gm. per 100 cc. When last seen 2 months after the operation he had no gastrointestinal complaints.

**Comment.** This patient had a slow but persistent hemorrhage from a known duodenal ulcer which failed to respond to intensive treatment under hospital conditions. A single episode of weakness with a drop in blood pressure following the passage of a grossly bloody stool 4 days after treatment had been

instituted was sufficient indication for surgery. While the bleeding was not as dramatic as that in the 2 preceding cases, and while it is conceivable that it might have stopped after a few more days of treatment, it seemed wise to arrest the hemorrhage and perform a definitive operation for the ulcer rather than run the risk of further bleeding and possible death. This case further demonstrates the fact that under modern conditions one may operate safely long after 48 hours of bleeding (a procedure once frowned upon by surgeons generally) and that in some instances it may be advisable to do so.

**Case 4. Hemorrhage from gastric leiomyoma; spontaneous arrest; elective resection.** A 49 year old white machinist was admitted to the Clinic Hospital on January 21, 1950 for emergency treatment of a painless gastrointestinal hemorrhage. For 5 days he had been passing tarry stools and feeling progressively weaker. Although "indigestion" had been present for 20 years, he had never before experienced bleeding. On admission the patient was pale and apprehensive, the pulse rate was 100 and the blood pressure 110/64. General examination was otherwise normal. He received 1500 cc. of whole blood transfusions in the next 36 hours following which his hemoglobin was 8.2 Gm. per 100 cc. Bleeding appeared to have ceased. An additional 2500 cc. of blood in the next 8 days raised the hemoglobin to 14 Gm. per 100 cc. Gastroscopic study showed the source of the bleeding to be a large and presumably benign neoplasm in the proximal third of the stomach, and this was confirmed by the roentgenogram. The patient was discharged to attend to some personal business, and readmitted on February 6, 1950. A local resection of a benign gastric leiomyoma was performed on the following day (fig. 3). Recovery was uneventful, and he was discharged on the ninth postoperative day. When last seen, 2 months after operation, the patient was asymptomatic.

**Comment.** This patient had a slow but persistent hemorrhage from a lesion undiagnosed at the time of admission. The hemorrhage responded to blood transfusion and the usual conservative measures. Delay permitted an accurate localizing diagnosis, and a carefully planned interval operation which could be executed with a minimum of risk.

### Summary and Conclusions

Although it is desirable to permit a massive hemorrhage from the upper gastrointestinal tract to subside spontaneously if possible, an occasional patient will require an emergency operation to arrest the bleeding. Satisfactory management of patients with massive hemorrhage requires the liberal use of blood transfusions. Close cooperation between internist and surgeon is needed to insure prompt recognition of the few requiring surgical intervention.

### References

1. Allen, Arthur, W.: Acute massive hemorrhage from upper gastrointestinal tract; with special reference to peptic ulcer. *Surgery* 2:713 (Nov.) 1937.
2. Amendola, F. H.: Management of massive gastroduodenal hemorrhage. *Ann. Surg.* 129:47 (Jan.) 1949.
3. Fraser, R. W., and West, J. P.: Management of bleeding duodenal ulcers. *Ann. Surg.* 129:299 (March) 1949.

S. O. HOERR

4. Heuer, G. J.: Surgical aspects of hemorrhage from peptic ulcer. *New England J. Med.* **235**:777 (Nov. 28) 1946.
5. Hoerr, S. O., Dunphy, J. E., and Gray, S. T.: Place of surgery in emergency treatment of acute massive upper gastrointestinal hemorrhage. *Surg., Gynec., and Obst.* **87**:338 (Sept.) 1948.
6. Schatzki, R.: Roentgenologic examination in patients with bleeding from the gastrointestinal tract. *New England J. Med.* **239**:983 (Nov. 28) 1946.
7. Stewart, J. E., et al: Massive hemorrhage from gastroduodenal ulcer. *Surgery* **24**:239 (July) 1948.
8. Warren, R., and Lanman, T. H.: Surgery in bleeding peptic ulcer; urgent operation and the principle of exclusion. *Surg., Gynec., and Obst.* **87**:291 (Sept.) 1948.
9. Welch, C. E.: Treatment of acute massive gastroduodenal hemorrhage. *J.A.M.A.* **141**:1113 (Dec. 17) 1949.