

CARCINOMA OF THE CARDIAC PORTION OF STOMACH

Treatment by Use of the Thoraco-Abdominal Approach

GEORGE CRILE, JR., M.D.

Department of General Surgery

DONALD B. EFFLER, M.D.

Department of Thoracic Surgery

and

J. E. SCHEID, M.D.

Fellow in Surgery

SUCCESSFUL treatment of cancer arising in the cardiac portion of the stomach demands total extirpation of the cancer-bearing tissue within and adjacent to the stomach including the spleen, the tail of the pancreas, the lesser peritoneal sac, the great omentum, and the lymph nodes in the gastro-hepatic ligament and in the infraduodenal area. Incomplete removal of these structures diminishes the chance of cure.

The need for more adequate exposure of the cardiac portion of the stomach prompted Von Miku'icz¹ to attempt transthoracic resection in 1896. The patient died. In 1916 Brunn² performed the first successful cardiectomy and esophagogastrostomy. The combined thoraco-abdominal approach was suggested by Janeway and Green³ in 1910 but it was not until after 1933 that the feasibility of the combined thoraco-abdominal approach to the upper stomach and its adjacent structures was demonstrated by Oshawa.⁴

The development of the thoraco-abdominal incision has depended less upon the boldness of the surgeon than it has upon evolution of safe anesthesia. Management of the open thorax has become a commonplace procedure and in qualified hands does not increase the risk of operation.

Technic

The series of cases to be presented represents the combined experience of the authors in 22 operable cases of gastric carcinoma involving the cardiac end of the stomach. In each case the thoraco-abdominal approach was employed and some form of gastric resection was performed. As might be expected there was considerable variation in the operative procedures, some of which were essentially palliative. Increased familiarity with this approach has led to the simplification of what appeared to be a formidable procedure.

The patient's left side is tilted upward at an angle of about 45 degrees. The table may be tilted in the reverse direction during the exploration of the abdomen. The abdominal component of the incision should be made first and

the abdominal cavity explored to determine operability.^{5,6} The laparotomy may be performed by various technics, using midline, left rectus, transverse, or oblique incisions. The simplest incision is the oblique type that begins near the midline and traverses the left rectus muscle to the costal margin in the same direction as the ribs (fig. 1). This small incision allows adequate exploration of the upper abdomen and may be extended in either direction without altering the position or the draping of the patient. If the thoraco-abdominal approach is indicated, the lateral aspect of the abdominal incision is continued through the costal arch and along the seventh or eighth interspace. Should the thoracic component of the incision prove unnecessary, the

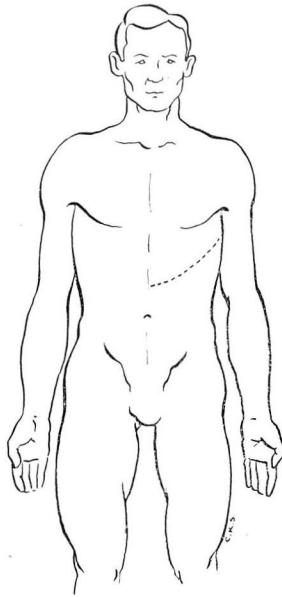


FIG. 1. Thoraco-abdominal incision.

medial limb may be continued across the midline to transect the right rectus muscle.

The determination of operability is based on inspection and palpation through the initial laparotomy incision. Particular attention is paid to the mobility of the tumor, and to the presence of metastases in the liver or on the peritoneum including that of the pelvis. Those patients who have numerous hepatic metastases, and those who have intra-abdominal fluid with peritoneal seeding, are considered to be beyond hope of cure or palliation. In these hopeless cases the exploratory procedure has been minimal and is associated with little morbidity.

After operability has been determined, the surgeon may elect to convert the incision into a combined thoraco-abdominal approach. The skin incision

is continued over the costal margin and through the appropriate interspace. There is wide variation in the configuration of thoracic cages and for this reason the selection of interspace must be individualized. We have usually employed the sixth, seventh, or eighth interspaces and resection of a rib has not been necessary. Following the skin incision the cartilaginous costal arch is incised; at least one pair of vessels parallels the arch and will require ligation. The intercostal muscles are divided and the pleural space entered. The wound edges are protected with drapes and the ribs are spread to aid exposure of the left upper quadrant and subdiaphragmatic area. If the terminal esophagus is to be resected the diaphragm is cut directly to the esophageal hiatus; if the esophagus is not involved, the diaphragm may be left intact or transected in part. The incision and subsequent repair of the diaphragm may be unnecessary in certain cases; if it can be avoided there is appreciable reduction in the operating time.

The excellent exposure afforded by the thoraco-abdominal approach allows the surgeon to evaluate the problem fully and to deal with it accurately. In the 22 cases presented several types of resection and anastomosis were employed.

Table 1

Surgical Procedures in 22 Cases Where the Thoraco-Abdominal Approach Was Employed

| Number of Cases | Subtotal Resections | Total Resections | Excision of Polypoid Tumor |
|--------------------|------------------------|---------------------|-------------------------------|
| 22 | 15 | 6 | 1 |

When the operation for a high gastric carcinoma is done not merely for the palliation, but with the hope of effecting a cure, it should include splen-

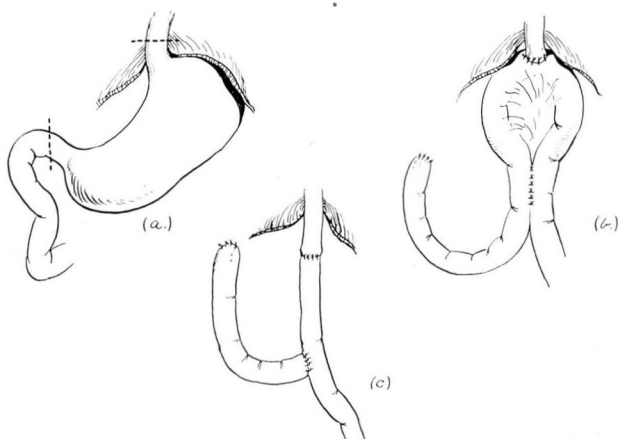


FIG. 2. (a) Total gastrectomy, indicating sites of transection. (b) Esophagojejunostomy, entero-enterostomy below. (c) Roux en Y type esophagojejunostomy.

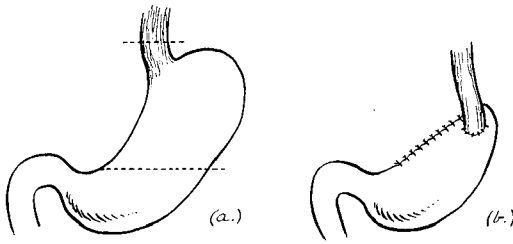


FIG. 3. Partial gastrectomy, indicating sites of transection. (b) Esophagogastrostomy, completed.

ectomy, resection of the tail of the pancreas, removal of a generous segment of the gastrocolic and gastrohepatic ligaments, removal of the great omentum, and resection of a portion of the terminal esophagus, in addition to extirpation of the cancer-bearing stomach. With proper exposure the dangers of blind dissection and uncontrollable hemorrhage are removed and the morbidity and mortality rates are lowered.

It is usually easiest to begin the resection by delivering the spleen and incising the peritoneum at its lateral border. The spleen, the splenic vessels, the stomach, the tail and body of the pancreas, are then mobilized from left to right in block, along with the great omentum and the peritoneum of the lesser sac. The operation is essentially a retroperitoneal one, the peritoneum being removed with the viscera of the upper abdomen. The pancreas is transected at the desired level and its stump closed with mattress sutures. The splenic vessels and the left gastric artery are ligated retroperitoneally when they appear in the field. The stomach is either removed completely or transected well below the lesion, taking care to remove as much as possible of the node-bearing tissue along its curvatures, in the gastroheptic omentum and below the duodenum.

Re-establishment of continuity following gastric and esophageal resection has been performed in two ways. If total gastrectomy is indicated, a loop of jejunum is brought through the left transverse mesocolon and esophagojejunostomy performed with complimentary entero-enterostomy below the mesocolon. In one case, an end-to-end esophagojejunostomy was made with a Roux type jejunojejunostomy (fig. 2). When a partial resection has been performed the greater curvature of the pyloric antrum has been preserved and the lesser curvature resected; this creates a tube-like remnant of stomach. The esophagus is then anastomosed to a slit wound on the anterior wall of the greater curvature (fig. 3). In all cases an intestinal suction tube is left in place beyond the anastomosis.

Closure of the thoraco-abdominal wound is accomplished easily. The costal arch is re-established by two chromic catgut sutures through the severed cartilage and one or two catgut pericostal sutures. The chest incision may be closed with catgut, silk, wire, or cotton; the abdominal wound is closed with interrupted wire figure-of-eight sutures. It is not always necessary to employ water-seal suction drainage in the chest; thoracentesis during the early post-

operative period usually will suffice. A sump drain may be used in the upper abdomen, particularly when there has been a partial resection of the pancreas. Early ambulation is advised in all cases.

Discussion

Much has been written about the necessity for total gastrectomy as against subtotal resection in cancer of the stomach. It is not our purpose to discuss this controversial subject. Six of the 22 cases were treated by total gastrectomy because of the location and nature of the lesion. Perhaps more important than total resection is the removal of the areas of lymphatic extension with excision of potentially involved extragastric tissue in addition to a wide margin of clearance within the stomach itself.

Of the 2 deaths in the group of 22 patients, 1 was due to cerebral thrombosis on the seventh postoperative day, the other was attributed to leakage through a tiny hole in the esophagus nearly 2 cm. above the line of anastomosis. The cause of this hole could not be determined. Other complications are listed in Table 2. All were of comparatively minor importance and exerted little influence on the ultimate course.

Table 2

| Complications | | |
|---|--------|---------|
| Type | Number | Result |
| Cerebral vascular accident | 1 | Fatal |
| Leakage through perforation above anastomosis | 1 | Fatal |
| Empyema | 2 | Healed |
| Stricture of anastomosis | 1 | Healed* |

Sufficient time has not elapsed to evaluate the end results of treatment. We believe, however, that the thoraco-abdominal approach has increased the resectability of high gastric cancer and has enabled us to afford palliation, at least, to a group of patients we would have considered inoperable heretofore. Time alone will tell whether more patients with cancer of the stomach will be cured by these radical gastric resections. In any event the increased exposure afforded by the thoraco-abdominal approach may be an important factor in reaching this goal.

Summary

1. Twenty-two patients with carcinoma of the cardiac end of the stomach treated by thoraco-abdominal resection of the stomach are reported.
2. There have been 2 hospital deaths in this series.
3. The immediate results have been good and the morbidity of operation is low.
4. Sufficient time has not elapsed to evaluate the end results.

*Required secondary surgical procedure; patient recovered.

References

1. Von Mikulicz, cited by Pack, G. T., and McNeer, G.: Surgical treatment of cancers of gastric cardia. *Surgery* 23:976 (June) 1948.
2. Brunn, cited by Carter, B. N.: Combined thoracico-abdominal approach with particular reference to its employment in splenectomy. *Surg., Gynec., and Obst.* 84:1019 (June) 1947.
3. Janeway and Green, cited by Pack and McNeer.¹
4. Oshawa, cited by Carter.²
5. Garlock, J. H.: Radical surgical treatment for carcinoma of cardiac end of stomach. *Surg., Gynec., and Obst.* 74:555 (Feb.) 1942.
6. Humphrey, G. H.: Approach to resections of esophagus and gastric cardia. *Ann. Surg.* 124:288 (Aug.) 1946.