

# TREATMENT OF PHARYNGO-ESOPHAGEAL DIVERTICULUM BY INVERSION OF THE SAC\*

GEORGE CRILE, JR., M.D. and A. H. ROBNETT, M.D.  
Department of General Surgery

IN 1895 Girard<sup>1</sup> of France first reported treatment of pharyngo esophageal diverticulum by simple inversion. Subsequently Halstead<sup>2</sup> and Bevan<sup>3</sup> independently utilized the procedure and reported its success. Since that time, except for an occasional report such as that made by Ross,<sup>4</sup> the technic has not been described in the literature and generally has been replaced by the technics of excision of the diverticulum as reviewed by Lahey,<sup>5</sup> Harrington,<sup>6</sup> and others.

A pharyngo-esophageal diverticulum is composed of mucosa and submucosa herniating through the zone of the junction of the pharynx and esophagus and through the triangular space bounded by the fibers of the cricopharyngeal muscle and the inferior constrictor of the pharynx. The position of the sac may be in the midline or usually to the left between the two muscles (fig. 1). The structure and relationship of the sac renders it possible to reduce the herniation by inversion of the sac and closure of the muscular defect. This procedure has been performed in a series of 11 consecutive cases of pharyngo-esophageal diverticula by the following technic:

## Technic

1. Unless the roentgenographic investigation demonstrates clearly that the diverticulum originates on the right side (which is rare) an incision is made through skin and platysma over the anterior edge of the left sternocleidomastoid muscle from the level of the hyoid bone to the suprasternal notch.
2. The sternocleidomastoid and prethyroid muscles are retracted laterally and the lobe of the thyroid medially. To provide adequate exposure, it usually is necessary to ligate and divide the lateral thyroid vein and inferior thyroid artery.
3. The recurrent laryngeal nerve is identified and its upper portion clearly exposed so that inadvertent injury of the nerve will be avoided.
4. The diverticulum is identified lying directly behind the lobe of the thyroid and is carefully grasped with smooth thumb forceps. The sac is dissected away from the muscle fibers of the inferior constrictor and cricopharyngeal muscles until its neck is well mobilized.
5. An Ewald tube is passed by the anesthetist through the mouth and down the esophagus to outline the esophagus and aid in identifying the true neck of the sac.
6. A purse string suture of catgut is placed through the submucosa of the neck of the sac and the sac is inverted into the esophagus (fig. 2a).

7. The purse string suture then is tied and the Ewald tube passed through again to demonstrate the absence of esophageal stricture (fig. 2b).

8. With the Ewald tube resting in the esophagus and the sac inverted, the defect between the muscle fibers of the cricopharyngeus and inferior constrictor muscles is closed transversely with interrupted Number 60 cotton sutures.

9. The subplatysmal structures of the neck are allowed to fall together, platysma and fascia are closed without drainage with Number 60 cotton sutures, and skin edges are approximated with clips.

10. The Ewald tube is withdrawn.

### Postoperative Care

The patient is allowed to be ambulatory on the day of operation, permitted clear liquids for the first 2 postoperative days, and on the third day a soft diet is given. Skin clips are removed on the third or fourth postoperative day, and the patient is discharged on the fifth to seventh day on an unrestricted diet with instructions to chew his food thoroughly.

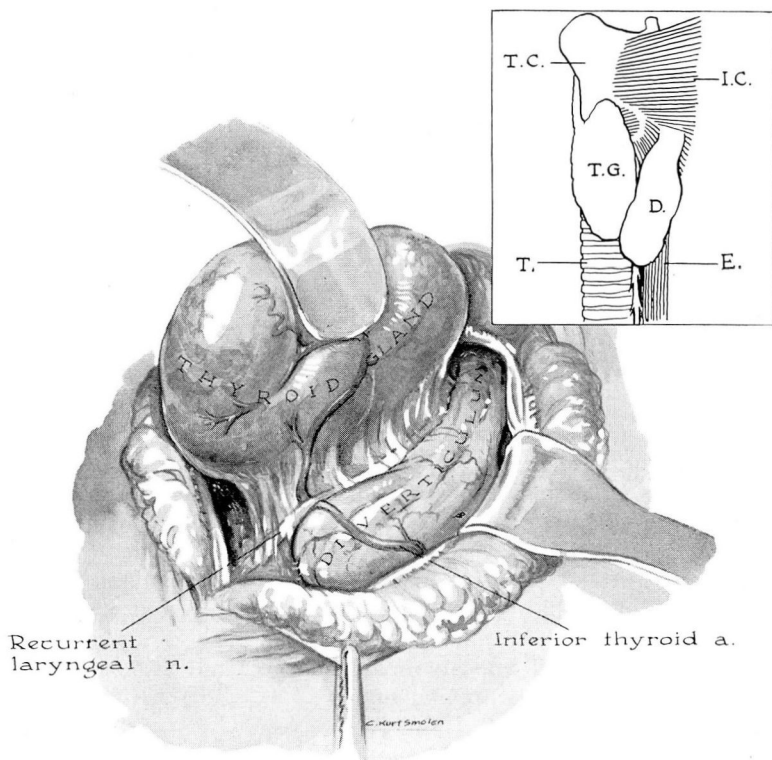


FIG. 1 inset. T.C. (thyroid cartilage), I.C. (inferior constrictor muscle), T.G. (thyroid gland), D. (diverticulum), T. (trachea), E. (esophagus).

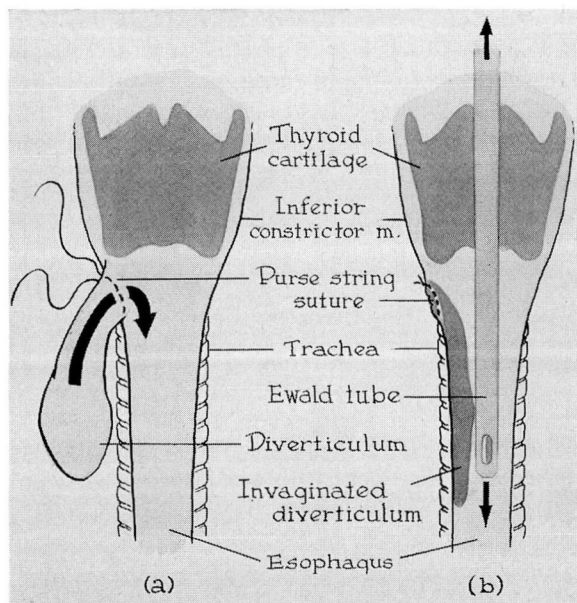


FIG. 2. (a) Diverticulum mobilized; purse-string suture in place. (b) Diverticulum inverted; purse-string suture tied; Ewald tube in esophagus.

Penicillin was used prophylactically for a few postoperative days in the first patients in the series, but has not been used in the later cases.

### Comment

When the diverticulum is exceptionally large (as in case 3 which measured 11 by 7 cm.), inversion is dangerous without partial resection. If the entire diverticulum were inverted the patient might belch it into the pharynx, thereby occluding the larynx. In order to avoid this contingency a tie may be placed around the diverticulum and its distal two-thirds resected prior to inversion. The stump is handled aseptically, but since the possibility of contamination is present it is best to insert a Penrose drain which should be left in place for 2 or 3 days.

For the first 2 or 3 days after operation some of the patients with larger diverticula have stated that upon belching, they are conscious of the presence of the sac in the pharynx. Atrophy of the sac takes place so rapidly, however, that at the end of 2 weeks it appears roentgenographically to be a small polyp, and is difficult to visualize by esophagoscopy.

### Results (See Table)

The 11 patients treated by the technic described, have done well. In a single case a second small bulge appeared on the opposite side, but has not caused

PHARYNGO-ESOPHAGEAL DIVERTICULUM

Case No. *	Size of Diverticulum (X-ray Measurement)	Restricted Diet	Postop. Complication	Postop. Day of Discharge	Postop. X-ray	Postop. Esoph.	Follow-up Mo. Postop.	Results
1	5.5 x 9 cm.	1 week	0	6 days	No recurrence	No diverticulum	2 mo. **	Cured
2	3.5 cm.	4 days	0	5 days	No recurrence	.....	48 mo.	Cured
3	11 x 7 cm. left post. wall	4 days	0	5 days	Small diverticulum, rt. post. wall	.....	20 mo.	Cured - Small new diverticulum, on other side
4	Large	6 days	0	6 days	.....	.....	38 mo.	Cured
5	4 x 2 x 4.5 cm.	4 days	0	7 days	Small filling defect at site of diverticulum, no recurrence	.....	24 mo.	Cured
6	3.5 x 2.5 cm.	6 days	0	8 days	No recurrence	No diverticulum	24 mo.	Cured
7	4 x 5 cm.	3 days	0	3 days	.....	.....	14 mo.	Cured
8	3 x 2 x 3 cm.	5 days	0	5 days	.....	.....	17 mo.	Cured
9	4 cm.	5 days	0	7 days	Small filling defect at site of diverticulum	.....	19 mo.	Cured
10	3 x 6 cm.	5 days	0	10 days	No recurrence	.....	20 mo.	Cured
11	.....	4 days	Infection requiring drainage	4 days	No recurrence	.....	15 mo.	Cured

\*Five of these patients were operated upon by the late Dr. T. E. Jones.

\*\*Unable to trace.

symptoms of sufficient significance to require treatment. The patients have been followed from 2 to 38 months since operation and there have been no recurrences, strictures, or late complications (fig. 3). In one case a patient who had had an uneventful postoperative course in the hospital, and who was discharged on the fourth postoperative day, developed a deep cellulitis of the neck several days afterwards. The cellulitis responded to treatment with antibiotics but ultimately required drainage. There was no fistula and there has been no recurrence of the diverticulum.

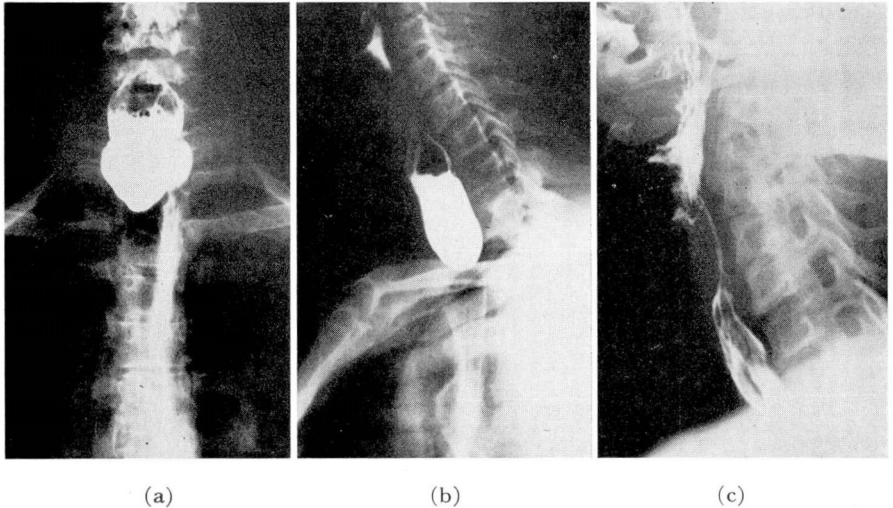


FIG. 3. (a and b) Case 1. Preoperative x-rays revealing large pharyngo-esophageal diverticulum. (c) Postoperative x-ray. No evidence of recurrence.

### Advantages

1. The esophagus is not opened, so that danger of infection is minimized.
2. The period of hospitalization has been shortened so that the majority of patients are ready for discharge on the fourth or fifth postoperative day.
3. There is no necessity for tube feeding.
4. Liquids are given from the time of operation and a normal unrestricted diet can be resumed on the fourth postoperative day.
5. The incidence of recurrence is low because of the absence of infection.

### Conclusions

1. A technic of repairing pharyngo-esophageal diverticula by inversion of the sac and repair of the overlying musculature is described.
2. The operation is simple, safe, and aseptic.
3. The end results in our 11 cases have been entirely satisfactory.



**References**

1. Girard, C., cited by Halstead.<sup>2</sup>
2. Halstead, A. E.: Diverticula of esophagus with report of case. *Ann. Surg.* **39**:171 (Feb.) 1904.
3. Bevan, A. D.: Diverticula of esophagus. *J.A.M.A.* **176**:285 (Jan. 29) 1921.
4. Ross, D. E.: Invagination operation for esophageal diverticulum. *Am. J. Surg.* **63**:3 (Jan.) 1944.
5. Lahey, F. H.: Pharyngo-esophageal diverticulum; its management and complications. *Ann. Surg.* **124**:617 (Oct.) 1946.
6. Harrington, S. W.: Pulsion diverticulum of hypopharynx at pharyngo-esophageal junction. *Surgery* **18**:66 (July) 1945.