

ELECTROPHORETIC AND ULTRACENTRIFUGAL ANALYSIS OF SERUM PROTEINS IN MULTIPLE MYELOMA*

LENA A. LEWIS, Ph.D.

Research Division

DONALD W. BORTZ, M.D. and JOHN D. BATTLE, JR., M.D.

Department of General Medicine

WHILE many studies have been made on the serum proteins in multiple myeloma, the application of both electrophoretic and ultracentrifugal analysis to the same sera has been limited. This report summarizes the results of electrophoretic and ultracentrifugal analyses of the serum or plasma proteins of 10 patients with multiple myeloma. Seventeen additional cases had electrophoretic analyses of the sera.

Electrophoresis was carried out by the method of Tiselius as modified by Longsworth,¹ using either phosphate buffer pH 7.8, ionic strength 0.16 μ , or barbiturate buffer, pH 8.6, ionic strength 0.1 μ . Ultracentrifuge studies were made in a cell holding 0.9 ml. of solution; a speed of 59,780 r.p.m. exerting a force equivalent to 254,500 times gravity was employed. The serum was dialyzed against 0.9 per cent sodium chloride, and the protein concentration adjusted to approximately 1 per cent, before centrifugation.

The diagnosis of multiple myeloma was, in all cases, established by blood and bone marrow studies and physical examination. Clinical notes on 4 of the cases are included because of unusual findings in the protein studies or difficulty in the establishment of diagnosis.

Results

The electrophoretic serum protein pattern in multiple myeloma can be divided into four groups (table 1). In the first, which represented 7 of the 27 cases, there was a definite increase in the serum protein component with mobility similar to that of normal β -globulin. One serum showed only a slightly elevated β -globulin concentration, but 90 per cent of the urinary protein had a mobility similar to that of serum β -globulin.

The second group which included 13 cases, showed a large serum component with the mobility of normal γ -globulin (fig. 1, appendix cases, 18 and 19). The serum of the third group (6 cases) had a component with a mobility between that of normal β and normal γ -globulin (fig. 1, appendix cases 24 and 26). The fourth group, 1 case, showed no characteristic change in the serum electrophoretic pattern.

Studies were made on the serum of one patient in group 3 on four occasions in a period of 2 years (fig. 1, appendix case 25). In all four samples, the component with a mobility of $1.9 \mu \times 10^5 \text{ cm.}^2 \text{ volt}^{-1} \text{ sec.}^{-1}$, represented between

*This investigation was supported in part by a research grant from the National Heart Institute of the National Institutes of Health, U. S. Public Health Service.

50 and 60 per cent of the total protein (fig. 1). The abnormal component precipitated with the proteins which came down during dialysis of the serum against tap water, was precipitated by ammonium sulfate at pH 5.4 when the concentration was increased from 25 to 33 per cent, and had 0.408 mg. polysaccharide per mg. of nitrogen.

The electrophoretic pattern of one sera in group 2 was particularly interesting, as the large component with mobility in the γ -globulin range showed four distinct peaks (fig. 1, table 1—appendix case 19). In all other myeloma sera studied, the abnormal component was resolved by electrophoresis as one large clear-cut peak. The ultracentrifuge pattern of this sera was also different from that of the others in this group, as a much larger proportion of the protein was found in the more rapidly sedimenting fractions.

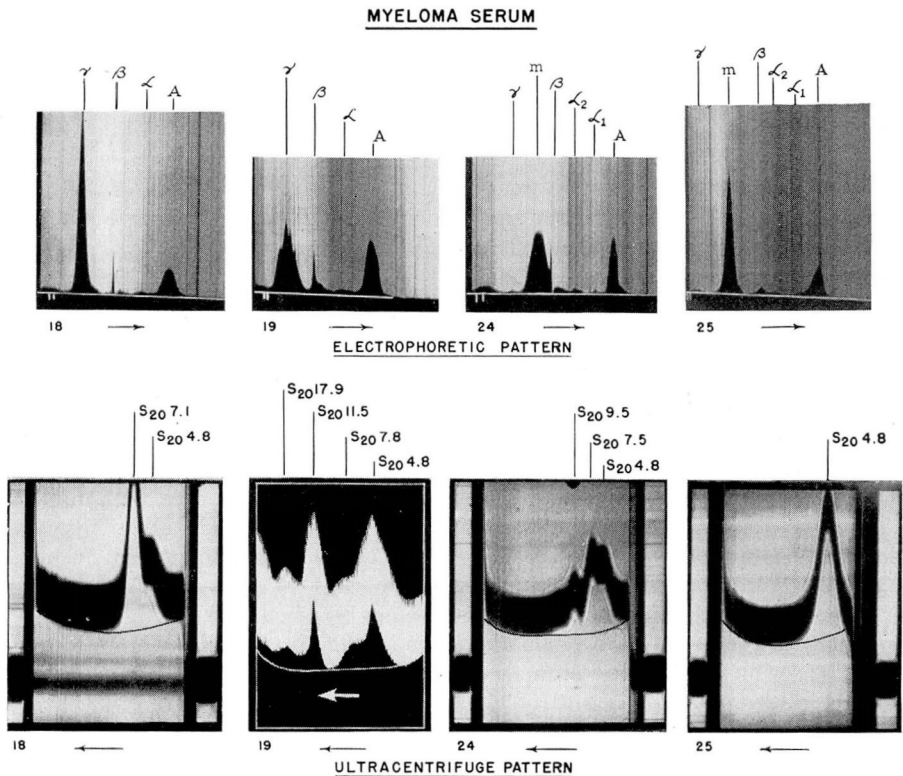


FIG. 1. Electrophoretic patterns of serum No. 18 and No. 19 were obtained using phosphate buffer pH 7.8, μ 0.16, of No. 24 and No. 25 using barbiturate buffer pH 8.6, μ 0.10, time 82.5 minutes. Ultracentrifuge patterns were obtained after dialysis of the serum against 0.9 per cent sodium chloride, centrifuge rate 59,780 r.p.m., time 44 minutes for No. 24 and No. 25, 48 minutes for No. 18 and 75 minutes for No. 19.

The ultracentrifuge patterns of the myeloma sera were of three types. The first observed in the serum of electrophoretic group 1 showed a poor resolution of the globulin from the albumin (table 1). Since the β -globulin contains a large percentage of lipoprotein, greater resolution might have been obtained with use of a higher density salt solution.

The sera of case 26 also showed no separation of the globulin from albumin when 0.9 per cent sodium chloride solution was used as solvent. The β -lipoprotein pattern using 9.4 per cent sodium chloride as solvent was not remarkable, indicating that the abnormal globulin component was not lipoprotein.

The second type of pattern, which was found on study of the sera of electrophoretic group 2, showed a noticeable increase in the concentration of the globulin component with a sedimentation rate of about 7. Case 19 was an exception to this, but the electrophoretic pattern was also atypical.

The third type of ultracentrifuge pattern was characterized by an increase in the globulin concentration of 2 or more peaks, with a sedimentation rate between 11 and 6. The patterns of this type were observed in electrophoretic group 3.

Discussion

Clinically, the diagnosis of multiple myeloma may be suspected in any case of an elderly patient who presents himself with a pathologic fracture, an obscure anemia, tumor formation, or vague rheumatic pains. The diagnosis may be established by confirming the presence of clinically suspected anemia, hyperproteinemia with an exceedingly high globulin fraction, proteinuria with development of the Bence-Jones protein, and evidence of nitrogen retention. An elevated sedimentation rate is also invariably present. X-ray evidences, either of a diffuse osteoporosis or of localized osteolytic lesions, frequently may be found. Diagnosis usually has been confirmed by bone marrow studies, and the finding either of an increased number of mature plasma cells or plasmablasts. The studies by electrophoretic and ultracentrifugal methods generally have been used as confirmatory tests of the diagnosis arrived at clinically and in the routine laboratory procedures, but in 2 patients (cases 24 and 25), such studies were of definite value in establishing the exact diagnosis.

The ultracentrifuge patterns obtained on the sera of 5 patients with multiple myeloma had been noted by Kekwick² to be of two types: the first with a normal number of components but increased percentage of globulin (type 2 in our results), and the second revealing several components not present normally. The ultracentrifuge pattern of the serum in this group was similar to that of our case 19, group 2 and of group 3. The electrophoretic pattern, however, showed a large single peak with the mobility of β -globulin.

The lack of correlation between the relative concentration of the different fractions resolved by electrophoresis and ultracentrifugation indicates the complex and varied nature of the proteins in myelomatous sera. Similar conclusions were reached by Moore et al³ by use of salting out, electrophoretic, ultracentrifugal and immunologic methods. The electrophoretic and ultracentrifugal patterns obtained on case 19 both indicate the complex nature of

Table 1

Group 1

ELECTROPHORETIC PATTERN

Case No.	Material Analyzed	Total Protein Gm/100 ml.	Albumin %	alpha ₁ globulin %	alpha ₂ globulin %	beta-globulin %
			Mobility	Mobility	Mobility	Mobility
1.	Serum *	11.6	28.0	5.9	3.7	4.4
2.	Plasma *	7.5	29.3	6.2	8.7	4.9
3.	Serum *	12.5	26.3	6.2	5.7	4.6
4.	Serum **	6.2	66.1	6.2	3.9	5.4
	Urine **	10.0	6.0
5.	Plasma *	8.1	31.5	5.8	4.7	4.9
6.	Serum *	7.8	39.5	5.9	5.5	4.6
7.	Plasma *	6.6	55.1	5.9	7.2	4.3

Group 2

8.	Plasma **	14.9	13.7	6.5	1.4	5.5	1.7	4.9	4.5	3.7
	Urine **	2.1	7.8	6.2
9.	Plasma *	9.9	36.1	5.9	7.1	4.5	11.8	3.5
10.	Serum *	9.8	26.5	6.0	5.0	4.5	8.8	3.4
11.	Serum *	10.1	38.6	5.7	8.1	4.2	10.1	2.8
12.	Serum *	14.7	20.4	5.9	4.1	4.8	6.1	3.5
13.	Serum *	10.4	24.5	6.0	3.9	4.6	11.6	3.4
14.	Plasma *	11.4	18.0	5.9	7.7	4.8	7.8	3.5
15.	Plasma *	17.6	11.3	6.2	2.3	4.7	3.3	3.3
16.	Serum *	10.0	34.6	6.2	4.4	4.6	10.8	3.3
17.	Plasma *	8.8	30.2	4.7	8.1
18.	Serum *	14.0	19.7	6.4	3.1	5.0	3.9	3.9
	Urine *	2.0	17.0	6.8
19.	Serum *	11.5	33.5	6.1	4.8	4.4	12.4	3.1

Group 3

20.	Serum **	12.7	20.1	6.0	2.0	5.0	3.9	4.0	18.6	3.1
	Urine **	13.0	5.8
21.	Serum *	9.1	41.8	6.4	5.1	5.0	8.8	3.8
22.	Serum **	11.1	17.8	5.6	3.2	4.7	1.7	3.9	10.3	2.9
23.	Serum *	11.9	33.3	6.2	5.0	4.7	15.3	3.3
24.	Serum **	11.3	28.9	5.9	1.2	5.0	2.6	4.4	11.0	3.4
25.	Serum *	11.5	24.1	6.2	5.1	5.0	8.2	3.5
26.	Serum *	8.1	37.8	6.0	12.9	4.6	12.9	3.5

Group 4

27.	Serum **	6.5	54.5	6.0	7.9	5.5	14.2	4.9	19.5	3.1
-----	----------	-----	------	-----	-----	-----	------	-----	------	-----

*PO₄ buffer used.

**Barbiturate buffer.

MULTIPLE MYELOMA

Table 1 (Continued)

ULTRACENTRIFUGE PATTERN^a

α ₂ -globulin		γ ₁ -globulin		γ ₂ -globulin		S ₂₀	β ₁		S ₂₀	β ₂		S ₂₀	%
%	Mobility	%	Mobility	%	Mobility		%	S ₂₀		%	S ₂₀	%	
.....	4.7	0.9
6.4	2.5	9.0	0.9
.....	9.3	1.1
.....	4.5	0.9	4.5	90	15.2	<2
(polydisperse material between 2 peaks)													
12.4	2.0	4.0	0.8
.....	8.2	0.6
6.9	2.2	4.8	0.9
5.1	2.9	4.5	1.8	69.1	0.7
.....	92.2	0.8
6.6	2.2	38.4	0.9
1.1	2.0	33.4	0.9
.....	43.2	1.5
.....	68.4	1.1	4.3	21	7.7	75	9.8	2	16.8	2
.....	60.0	1.0
6.3	2.2	60.5	1.1
2.7	2.5	80.4	1.5
.....	50.2	1.4	4.8	47	7.1	53
3.5	53.5
.....	73.3	1.8	4.8	25	7.1	75
.....	83.0	1.6
.....	{ 11.7	1.8	14.6	1.2	4.8	47.2	7.8	12.5	11.5	29.3	17.9	11.0
.....	{ 9.5	1.5	13.5	0.8								
7.2	2.0	8.2	0.9	4.48	37.1	6.1	52.7	9.2	10.2
7.0	2.0	4.9	90.0	6.2	10.0
0.3	2.8	4.0	0.9
1.7	2.1	5.3	1.3	4.3	15.8	7.5	77.2	10.8	5.0	17.0	2
5.0	2.1	1.4	1.0
4.9	2.2	1.4	0.9	4.8	42.5	8.3	45	9.5	10.5	16.7	2
9.1	2.0	3.5	0.9	4.8	98	16.5	2
0.0	2.4	16.4	0.9	4.8	44.5	7.5	48	9.2	5.5	17.2	20
.....	3.9	1.0

the hyperglobulinemia present, and further substantiate the preceding conclusions.

The lack of resolution noted in the ultracentrifuge pattern of case 4, as already noted, was probably due to the lipoprotein nature of the abnormal component. Isolation and analysis of the lipoprotein from the plasma of a patient with plasma cell myeloma⁴ showed a large amount of cholesterol ester which separated from the plasma as needle-like crystals.

Case Reports

Case 18. A 69 year old housewife observed the gradual onset of recurrent episodes of nausea, vomiting and syncope 8 months prior to observation at the Cleveland Clinic in November 1948. The patient was admitted to a local hospital in August 1950 due to these symptoms and lower abdominal pain. Examination disclosed a severe anemia of undetermined cause which responded temporarily to blood transfusions. Anti-anemic therapy of liver injections and oral iron was ineffective. The past history was noncontributory except for the presence of "high blood pressure" for a period of at least 8 years.

Physical examination revealed profound pallor without jaundice. The patient was afebrile; pulse 80; blood pressure 190/100. Large, venous, flame-shaped hemorrhages were apparent in both retinae. There was neither localized nor generalized lymphadenopathy. Examinations of the heart, chest, lungs, and abdomen disclosed no remarkable findings.

Albuminuria was present but Bence-Jones proteins were absent. The hemoglobin was 4.7 Gm. per 100 ml., red blood cell count 1,790,000, white blood cell count 7250 per cu. mm. The differential count of the white blood cells was normal with the exception of 1 per cent plasma cells. The reticulocytes were 8.8 per cent and icteric index 4. Study of the stained blood films revealed anisocytosis, poikilocytosis, rouleaux formation, and basophilia of the background. The sedimentation rate was unusually rapid. The blood sugar and blood urea were within the normal range. The blood Wassermann and Kahn reactions were negative. The sternal marrow aspiration revealed 22 per cent mature and immature plasma cells, confirming the diagnosis of multiple myeloma. Roentgen examination of the chest was normal, although lateral films of the skull showed extensive osteoporosis.

The patient was given supportive and symptomatic treatment.

Case 19. The complaints of this 65 year old white woman were particularly referable to an injury which she had experienced in 1937 as the result of a fall from a stepladder; since that time generalized backaches had persisted and had become aggravated greatly 3 months prior to admission. An undiscovered degree of anemia apparently had been reported previously by her family physician. The systemic review was noncontributory, and the complete general physical examination failed to reveal any significant alterations other than evidences of some restriction in motion of the spine.

Her initial laboratory studies showed an entirely normal urinalysis with a normal Sulkowitch test. The Wassermann and Kahn reactions were negative as were the Bence-Jones proteins. An achlorhydria following alcohol stimulation was present with a total acid of only 14 units. The blood sugar was 227 mg. per cent 1½ hours postprandially. The blood count was 3,050,000 red blood cells, 55 per cent hemoglobin, with a hematocrit of 62 per cent. The white blood count revealed 2,600 white blood cells per cu. mm., with a differential blood count of 39 per cent neutrophils, 46 per cent lymphocytes, 1 per cent eosinophils, 13 per cent monocytes, and 1 per cent nonfilamented neutrophils. The examination of the peripheral blood film revealed a bluish background

to the preparation with definite evidences of rouleaux formation. The x-ray examination of the chest was normal. Evidences of narrowing of the lumbar vertebrae were suggestive of metastatic malignancy. A complete gastrointestinal examination, including the esophagus, stomach, duodenum, colon and gallbladder, was normal. A single lateral film of the skull was reported as showing a mottled appearance of the bones of the calvarium with multiple areas of radiolucency. A sternal marrow aspiration revealed a pronounced increase in the number of plasma cells with the differential study of the marrow preparation revealing 44 per cent mature plasma cells and 4 per cent plasmablasts.

Case 24. A 49 year old white farmer had experienced pain over the right lower costal margin with some degree of puffiness for approximately 2 years. However, 6 weeks prior to admission, following an apparent minor degree of trauma to the right costal margin, the roentgen examination showed the fracture of a rib; further x-ray study by his family physician was reported as revealing evidences of a "rare bone disease." The rest of his history and systemic review was entirely irrelevant. Physical examination likewise failed to disclose any significant alterations with the exception of some degree of puffiness of the right lower rib margins, and tenderness over the ninth and tenth ribs on the right side.

Upon admission to the hospital, completed laboratory studies revealed a negative Wassermann and Kahn reaction; the sedimentation rate by the Rourke-Ernstene method was 1.6 mm. per minute, the blood sugar was 94 mg. per cent while the blood urea was 30 mg. per 100 ml., with a clearance the first hour of 62 per cent and of 66 per cent the second hour. The routine urinalysis was reported as showing a trace of albumin, but the Bence-Jones urinary proteins were negative. His blood count showed 2,870,000 red blood cells, hemoglobin 52 per cent with a hematocrit of 56 per cent. The white blood count showed 2,900 white blood cells with 66 per cent neutrophils, 21 per cent lymphocytes, 12 per cent monocytes, 1 per cent nonfilamented neutrophils. Pronounced rouleaux formation with a bluish background to the stained blood film was noted. An increase in plasma cells in the sternal marrow aspiration was found. A review of accompanying x-rays revealed multiple areas of decreased density throughout the ribs, pelvis, spine and skull.

Case 26. A 55 year old brakeman was referred to the Department of Dentistry for the extraction of his remaining teeth and treatment of pyorrhea in July 1947. He stated, however, that he had "nearly bled to death" following dental extraction in 1945. Direct inquiry revealed a history of gingival bleeding, profound epistaxis, and excessive bleeding from trivial injuries since 1943. He denied systemic symptoms such as fever, pain, or loss of weight.

Examination disclosed moderate pallor, gingival bleeding and pyorrhea. The Rumpel-Leede tourniquet test was negative. Neither petechiae nor purpuric lesions were present. Lymphadenopathy, splenomegaly, and hepatomegaly were absent. The remainder of the physical examination was normal.

Moderate albuminuria was present and Bence-Jones proteinuria was demonstrated. Hematologic studies on initial examination revealed a normocytic hypochromic anemia as follows: hemoglobin 6.3 Gm. per 100 ml., red blood cell count 2,730,000 per cu. mm.; white blood cell count 5,650 with a normal differential. The icteric index was 2; platelets 320,000; bleeding time (Ivy method) 8½ minutes; coagulation time (Lee-White method) 21 minutes; clot retraction was incomplete in 24 hours. Pronounced rouleaux formation and basophilia of the background were noted on stained blood smears.

The serum albumin was 3.2 Gm. and serum globulin 8.4 Gm. per 100 ml. Liver function tests, blood urea and blood sugar were normal.

The initial sternal marrow aspiration was cellular but presented no increase of plasma cells nor "myeloma" cells. Repeated aspirations from the sternum and iliac crests revealed no significant deviations from normal.

The patient remained under periodic observation without appreciable change in his clinical condition, anemia, serum proteins or hemorrhagic diathesis. The remaining teeth were extracted in June 1949, multiple transfusions of whole fresh blood having been employed to control bleeding.

In March 1950, the patient developed left axillary lymphadenopathy and splenic enlargement. Biopsy of a lymph node revealed plasma cell infiltration, confirming definitely the clinical diagnosis of multiple myeloma.

Repeated x-ray examinations of the skeletal system showed only minimal osteoporosis.

Since March 1950, treatment with urethane has been maintained to the point of tolerance without appreciable change in the patient's condition or alteration of his serum proteins. During the long period of clinical observation he has not suffered any bone pain.

This patient is the only one in our experience who showed clinical and serum protein abnormalities typical of multiple myeloma in whom repeated marrow aspirations failed to reveal "myeloma" cells.

Summary

The electrophoretic and ultracentrifugal patterns obtained on the sera of patients with multiple myeloma may be divided into four types, depending on the electrophoretic fraction which is increased. The occurrence of four distinct peaks with an electrophoretic mobility in the γ -globulin range was observed in the sera of 1 patient. Ultracentrifugal analysis of the same sera showed three large globulin peaks with sedimentation S_{20} of 17.9, 11.5, and 7.8. The ultracentrifuge patterns, determined by using 0.9 per cent sodium chloride solution as solvent, were of 3 types: type 1 showed poor resolution of globulin from albumin; type 2 revealed a pronounced increase in the globulin component with sedimentation, S_{20} , around 7, and type 3, an increased concentration in more than one globulin peak.

References

1. Longworth, L. G.: Modification of schlieren method for use in electrophoretic analysis. *J. Am. Chem. Soc.* **61**:529, 1939.
2. Kekwick, R. A.: Serum proteins in multiple myelomatosis. *Biochem. J.* **34**:1248 (Sept.) 1940.
3. Moore, D. H., Kabat, E. A. and Gutman, A. B.: Bence-Jones proteinemia in multiple myeloma. *J. Clin. Investigation* **22**:67 (Jan.) 1943.
4. Hill, R. M. and Mulligan, R. M.: Plasma cell myeloma associated with high concentration of plasma lipoprotein. *Am. J. Path.* **24**:689, 1948.