

OCULAR FUNDUS FINDINGS IN 133 CASES OF DIABETES MELLITUS

ROSCOE J. KENNEDY, M.D. and FRANKLIN M. KRICHBAUM, M.D.*
Department of Ophthalmology

CHANGES in the ocular fundi of patients having diabetes mellitus have been described frequently since Jaeger's¹ reference to the subject in 1856. Duke-Elder¹ states that these changes, consisting mainly of hemorrhages and exudates and known as diabetic retinitis or diabetic retinopathy have been reported in from 2 per cent to 30 per cent of diabetic patients. More recent articles give an incidence of 92 per cent,² 100 per cent³ and 31 per cent.⁴ This wide variation has been partially due to lack of parallelism in the criteria of diagnosis of diabetic retinopathy and to differences in age, sex, severity, duration of diabetes, and presence of hypertension.

The prevalence of cataract in patients with diabetes mellitus has been apparent for a long time, the incidence varying greatly according to the criteria of cataractous change but generally higher than in the normal population. The association of retinitis proliferans with diabetes mellitus was cited by Fisher¹ in 1898. The occurrence of vitreous hemorrhage in diabetes mellitus is recognized as a complication of diabetic retinopathy. Iritis, retrobulbar neuritis, extraocular muscle paralysis and lipemia retinalis are less frequent ocular complications of diabetes mellitus as are paramacular hyaline degeneration, macular hole, optic atrophy, macular choroiditis, disseminated chorioretinitis, branch vascular occlusions, retinal detachment, rubeosis iridis diabeticum, optic neuritis, and central chorioretinitis.

Method and Data

For a period of 6 months we recorded data on new patients requiring eye examinations who were found to have known or previously unknown diabetes mellitus, for diabetic patients who returned for re-examination and patients referred from the diabetic service at the onset of diabetes mellitus for fundus examination. There were 133 cases which were satisfactory for analysis, however, those having opacities of the media extensive enough to prevent adequate visualization of the fundus were excluded.

Blood pressure, age, sex, duration of diabetes mellitus, retinal hemorrhages, retinal exudates, cataract, retinitis proliferans and intravitreal hemorrhage were recorded as of the date of the first examination at which diabetic retinal changes were revealed. Hemorrhages were carefully classified in examinations of the current year as punctate, small round, flame, and retinal; however, inasmuch as many of the earlier examinations were not specifically noted, retinal hemorrhages were tabulated as present if any type were observed. An attempt was made to record the degree of diabetic control prior to the develop-

*Former Fellow, now practicing in Akron, Ohio

OCULAR FUNDUS FINDINGS

Table 1

OCULAR FINDINGS IN 51 CASES WITH SYSTOLIC BLOOD PRESSURE OVER 160 mm. Hg. AND 82 CASES WITH SYSTOLIC BLOOD PRESSURE UNDER 160 mm. Hg.

Ocular Finding	Systolic B. P. over 160 mm. Hg. (51 Cases)		Systolic B. P. under 160 mm. Hg. (82 Cases)		Total (133 Cases)	
	No. of Cases	Per-centage	No. of Cases	Per-centage	No. of Cases	Per-centage
Retinal hemorrhage	37	72.5	46	56.1	83	62.4
Retinal hemorrhage without exudates	8	15.7	12	14.6	20	15.0
No retinal hemorrhage	14	27.4	36	43.9	50	37.6
Exudates without hemorrhage	0	0	0	0	0	0
Intravitreous hemorrhage	1	1.96	4	4.88	5	3.76
Retinitis proliferans	5	9.8	9	10.98	14	10.51
Glaucoma	4	7.85	1	1.22	5	3.76
Cataract	27	53.0	24	29.4	51	38.3

Table 2

RELATION OF AGE AND BLOOD PRESSURE TO RETINAL HEMORRHAGES

Age Group (Years)	No. of Cases	All 133 Cases		51 Cases with Systolic B. P. over 160 mm. Hg.		82 Cases with Systolic B. P. under 160 mm. Hg.	
		Hemorrh. Present	Hemorrh. Absent	Hemorrh. Present	Hemorrh. Absent	Hemorrh. Present	Hemorrh. Absent
0-9	0	0	0	0	0	0	0
10-19	1	0	1	0	0	0	0
20-29	9	6	3	2	1	4	2
30-39	8	3	5	0	0	3	5
40-49	33	18	15	4	3	14	12
50-59	37	27	10	13	2	14	8
60-69	34	21	13	12	5	9	8
70-79	10	8	2	6	2	2	0
80 and over	1	0	1	0	1	0	0

PERCENTAGE INCIDENCE OF RETINAL HEMORRHAGES
BY AGE GROUP AND IN RELATION
TO BLOOD PRESSURE

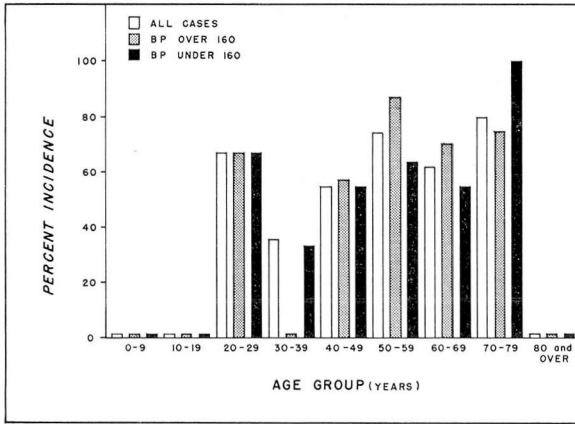


Chart 1

ment of retinal changes but there was such variation in types of treatment and follow-up that it was not possible to apply uniform criteria. Many of the patients were poorly controlled prior to recorded examinations and were under care at the Clinic for this reason or because of the fact that the referring physician encountered difficulty in maintaining adequate diabetic control. Data for patients showing no diabetic retinal changes were reported as of the date of the latest examination. Tables 1, 2, 3, and 4 refer to the conditions previously exemplified.

In all cases the fundi were examined after instillation of a mydriatic drug except in patients having glaucoma.

The tabulated incidence of hemorrhages in percentage for each age group is shown in chart 1 for patients with systolic blood pressure over 160 mm. Hg. and for those with systolic blood pressure under 160 mm. Hg.

Chart 2 shows the percentage and sex incidence of retinal hemorrhages in each decade.

One 62 year old nonhypertensive man who had had diabetes for 7 years with no retinal changes had experienced almost monthly subconjunctival hemorrhages during the previous 2 years. A nonhypertensive diabetic woman, aged 40, had diabetic retinopathy at the time of diagnosis of diabetes and, although followed for 8 years and well-controlled, persistently presented retinal hemorrhages on five examinations during that period. A 43 year old nonhypertensive woman who had diabetes for 25 years and evident retinopathy demonstrated no retinal changes upon examination elsewhere until the twenty-third year of her diabetes. A 65 year old nonhypertensive man had a history of diabetes without retinal changes; frequent ophthalmoscopic examinations during that period revealed no retinal hemorrhages.

Discussion

Hemorrhages, the most frequently found retinal change, were present in 62.4 per cent of the entire series (table 1). This incidence is lower than reported by Hanum² in his series (14 of 183 cases without hemorrhage, a hemorrhage incidence of 92.3 per cent) or, in the series of Gray and Braun which he quotes, 91.9 per cent and 90.1 per cent respectively.

Hanum's series consisted entirely of hospitalized patients and more extensive changes would be expected than in the present series of preponderantly ambulatory cases. Dolger's³ 100 per cent incidence of retinal hemorrhage was observed in cases of diabetes mellitus of 25 years' duration. Wilder⁵ gives the evidence of diabetic retinal changes as 16.6 per cent in consecutive cases of diabetes mellitus; the series of Sherrill et al⁴ included hospital patients and outpatients, as did this series, but there were no ophthalmic examinations with mydriatics, which might have resulted in more than a 31 per cent incidence of retinitis. Waite's and Beetham's⁶ series, reported in 1935, gave an incidence of only 18 per cent of deep retinal hemorrhages and included patients of all age groups having a 1 year to more than 15 year diabetic history.

Retinal hemorrhages were present without accompanying exudates in 15 per cent, whereas the occurrence of characteristic exudates unaccompanied by hemorrhage was not recorded. Hanum² reported diabetic exudates unassociated with hemorrhage in 7.6 per cent of his cases. Retinal hemorrhages were more frequent in the presence of hypertension (72.5 per cent) than in its absence (56.1 per cent) which corresponds closely with Waite's and Beetham's reported 54 per cent incidence with systolic blood pressure under 160 mm. Hg. The occurrence of hemorrhages without exudates was

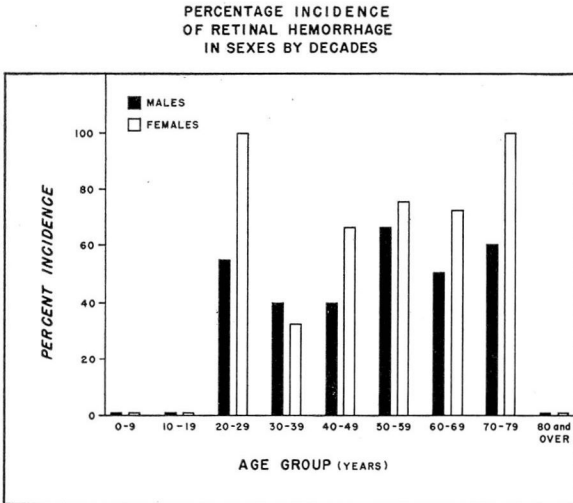


Chart 2

Table 3
RELATION OF SEX AND AGE TO RETINAL HEMORRHAGES

Age Group (Years)	M E N			W O M E N		
	No. of Cases	Hemorr. Present	Hemorr. Absent	No. of Cases	Hemorr. Present	Hemorr. Absent
0-9	0	0	0	0	0	0
10-19	0	0	0	1	0	1
20-29	7	4	3	2	2	0
30-39	5	2	3	3	1	2
40-49	15	6	9	18	12	6
50-59	9	6	3	28	21	7
60-69	16	8	8	18	13	5
70-79	5	3	2	5	5	0
80 and over	1	0	1	0	0	0

Table 4
RELATION OF KNOWN DURATION OF DIABETES MELLITUS
TO PRESENCE OF RETINAL HEMORRHAGES

Duration of Mellitus (Years)	All 133 Cases			51 Cases with Systolic B.P. over 160 mm. Hg.			82 Cases with Systolic B.P. under 160 mm. Hg.		
	No. of Cases	Hemorr. Present	Hemorr. Absent	No. of Cases	Hemorr. Present	Hemorr. Absent	No. of Cases	Hemorr. Present	Hemorr. Absent
Less than									
2	28	11	17	6	2	4	22	9	13
2-4	23	13	10	10	7	3	13	6	7
5-9	26	14	12	10	6	4	16	8	8
10-20	45	35	10	18	15	3	27	20	7
over 20	11	11	0	7	7	0	4	4	0

unaffected by hypertension (15.7 per cent as against 14.6 per cent) and is consistent with Wagner's⁷ statement that the earliest and possibly basic lesion of diabetic retinopathy is the small punctate hemorrhage occurring in the presence of normal vessels. This basic lesion has been shown to be a true spherical capillary aneurysm 30 to 90 microns in size, most frequently on the venous side of the retinal capillaries.^{8,9,10}

Wilder⁵ found a 5.5 per cent incidence of hemorrhages without exudates.

In the three age groups approximating more than 10 cases (table 2 and chart 1), there was a slight progressive rise in incidence of hemorrhages with age increase. In the same groups the incidence was consistently higher in those cases disclosing systolic blood pressure over 160 mm. Hg. (chart 1). However

there was a hypertensive patient over 80 years of age who presented no hemorrhages. The presence of retinal hemorrhage in 6 of the 9 patients in the 20 to 29 year age group refutes Hanum's statement that retinitis rarely is seen before the fourth decade. However the absence of hemorrhages in the patient under 20 is consistent with Hanum's claim that retinitis seldom occurs before this age. A higher incidence in women than in men (table 3 and chart 2) in the age groups between 40 and 70 is in accordance with Hanum's statement that women seem more likely to incur retinitis. The remaining age groups show the same sex difference in incidence but the number of patients is too low in each to be significant. Retinal hemorrhage shows a progressive increase in incidence with the duration of diabetes (table 4 and chart 3), attaining 100 per cent in patients having a 20 year history though there are only 11 cases of diabetes having persisted for this length of time. One of these prolonged cases, however, would have been recorded without hemorrhages had the patient been examined 2 years previously in her twenty-third year of the disease.

Root¹¹ reported 16 patients who acquired diabetes before 30 years of age, who remain without hemorrhage after a 20 to 25 years' interval. Joslin¹² described 7 patients having diabetes for 25 years who were unaffected by retinal lesions. The 100 per cent incidence in diabetes of over 20 years' duration is identical with the report of Dolger³ in cases lasting 25 years. Waite and Beetham⁶ found a similar increase in retinal hemorrhage in accordance with the duration of diabetes, but only to a maximum of 58.9 per cent over a period of 15 years. Except in cases of less than 2 years where there were only 6 patients having systolic blood pressure over 160 mm. Hg. there was a lower incidence of hemorrhage in the patients having systolic blood pressure under 160 mm. Hg. The

PERCENTAGE INCIDENCE OF RETINAL HEMORRHAGE
IN RELATION TO DURATION OF
DIABETES MELLITUS AND SYSTOLIC BLOOD PRESSURE

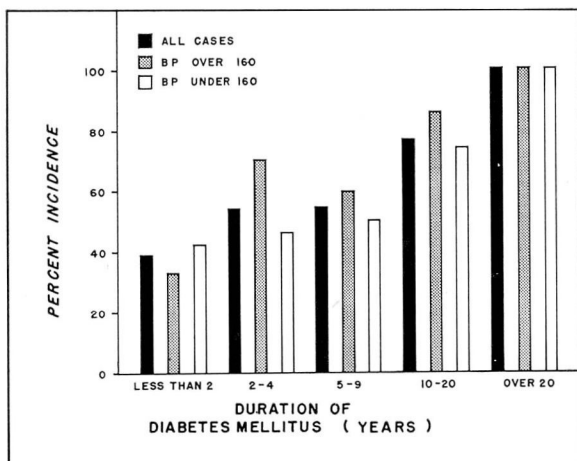


Chart 3

incidence of 78 per cent for a period of 10 to 20 years is higher than the 64 per cent incidence found by Root¹¹ in patients having diabetes for 10 years with the onset at the age of 15 to 30.

Intravitreal hemorrhage and retinitis proliferans were more frequent in nonhypertensive patients, though the cases observed were few. Glaucoma and cataract were found more frequently in cases with hypertension.

Summary

1. The average incidence of retinal hemorrhage in diabetic patients selected as described was 62.4 per cent, and, in patients having a systolic blood pressure less than 160 mm. Hg., 56.1 per cent.

2. Retinal hemorrhages in the absence of exudates were unaffected by the presence of hypertension.

3. Retinal hemorrhages increase in frequency with age, with hypertension, and with duration of diabetes mellitus.

4. Intravitreal hemorrhage, retinitis proliferans and glaucoma were relatively infrequent findings.

5. Cataract was present in 38.3 per cent of the cases studied.

References

1. Jaeger and Fisher, cited by Duke-Elder, W. S.: *Text-Book of Ophthalmology*, Vol. III: *Diseases of the Inner Eye*. St. Louis, C. V. Mosby Company, 1940.
2. Hanum, S.: Diabetic retinitis; clinical studies of 195 cases of retinal changes in diabetics. *Acta. Ophth.*, supp. 16, p. 3, 1939.
3. Dolger, H.: Clinical evaluation of vascular damage in diabetes mellitus. *J.A.M.A.* **134**:1289 (Aug. 16) 1947.
4. Sherrill, J. W. et al: Management of diabetes mellitus, *U. S. Nav. M. Bull.* **49**:29 (Jan.-Feb.) 1949.
5. Wilder, R. M.: *Clinical Diabetes Mellitus and Hyperinsulinism*. Philadelphia, W. B. Saunders Company, 1940.
6. Waite, J. H. and Beetham, W. P.: Visual mechanism in diabetes mellitus; comparative study of 2002 diabetics, and 457 non-diabetics for control. *New England J. Med.* **212**:367 (Feb. 28) 1935.
7. Wagner, H. P.: Retinopathy in Diabetes Mellitus. *Proc. Am. Diabetes A.* **5**:203, 1945.
8. Ballantyne, A. J. and Lowenstein, A.: Retinal micro-aneurysms and punctate hemorrhages. *Brit. J. Ophth.* **28**:593 (Dec.) 1944.
9. Friedenwald, J. S.: New approach to some problems of retinal vascular disease. *Am. J. Ophth.* **32**:487 (April) 1949.
10. Ashton, N.: Vascular changes in diabetes with particular reference to retinal vessels. *Brit. J. Ophth.* **33**:407 (July) 1949.
11. Root, H. F.: Diabetes and vascular disease in youth. *Am. J. M. Sc.* **217**:545 (May) 1949.
12. Joslin, E. P.: Furtherance of treatment of diabetes mellitus. *J.A.M.A.* **139**:1 (Jan. 1) 1949.