

THE ROENTGENOLOGIC APPEARANCE OF PERICARDIAL CALCIFICATION

WYLIE H. MULLEN, JR., M.D. and ROBERT M. GEIST, JR., M.D.
Department of Roentgenology

ALTHOUGH each year brings additional types of cardiovascular disease within the realm of surgical correction, pericardectomy for chronic constrictive pericarditis remains dramatic in its curative end-results.

Calcification is often a diagnostic aid in this disease. Pericardial calcification per se, however, does not necessarily imply constrictive pericarditis. An adhesive pericardium may be present and yet not interfere with cardiac function or produce symptomatology. Conversely, the absence of demonstrable pericardial calcification does not preclude the existence of a noncalcific constrictive pericarditis. Nevertheless, pericardial calcification is unequivocal evidence of pericardial disease. It is the end result of an inflammatory process, frequently tuberculosis pericarditis.

Calcification may assume various shapes within the pericardium: small plaques; irregular bands; forklike, linear, arcuate, or branching deposits; encompassing rings; or huge egg-shell encasements. Various authors^{1,2} have indicated the coronary sulcus and the surfaces of the right ventricle to be the commonest sites of calcification. In our experience it has been demonstrated along the left cardiac border with great frequency, and more commonly over the ventricles than over the auricles. A complete dense tiara of calcification outlining the auriculoventricular sulcus has been found several times with no antecedent history of disease and no signs or symptoms.³ We have seen one such case (fig. 1) in a 33 year old white woman having no history or clinical findings of pericardial or cardiac abnormality. In this case the history and

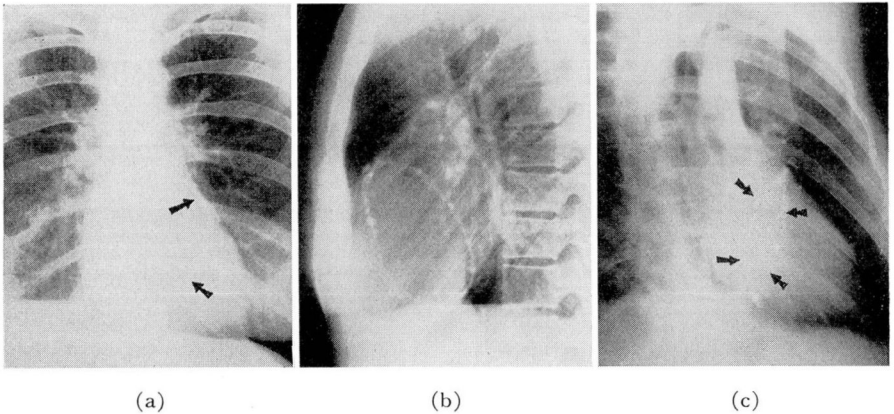


FIG. 1. Pericardial calcification outlining auriculoventricular sulcus as seen in (a) posteroanterior projection; (b) left lateral, and (c) right anterior oblique projection. Note defect in posterior right rib from previous thoracotomy.

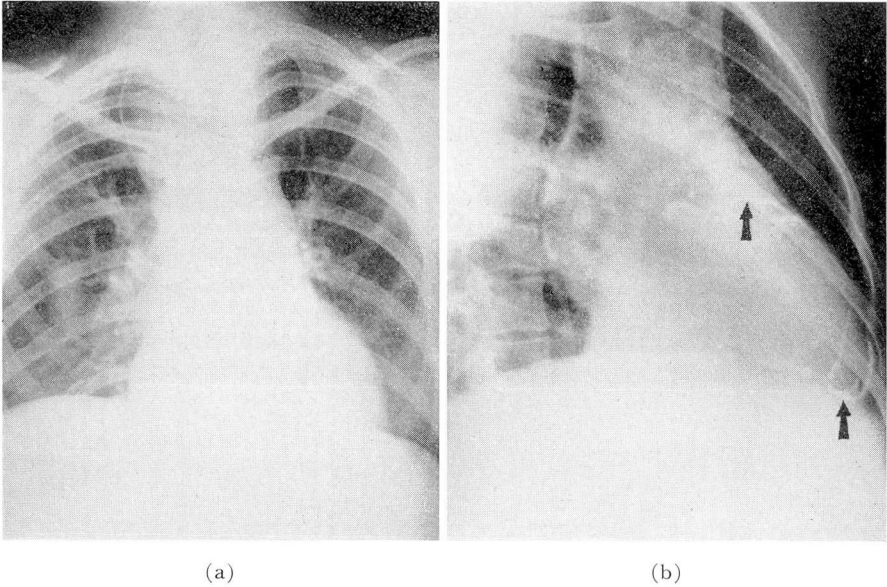


FIG. 2. Extensive pericardial calcification poorly demonstrated on (a) routine posteroanterior roentgenogram, but well demonstrated in (b) right anterior oblique position, especially along sternal and diaphragmatic borders of right ventricle.

residual roentgen evidence of an old empyema indicate the possibility of a contiguous pyogenic pericarditis as a probable etiologic consideration.

Roentgenologically, pericardial calcification is seen just immediately within the heart border and is best visualized on edge. The calcareous encrustations may be observed in any projection, however, those occurring over the right ventricle are best seen long the sternal and diaphragmatic borders with the patient in the right anterior oblique position (fig. 2). Left ventricular location of the plaques is visualized best in the left anterior oblique or posteroanterior positions (fig. 3). Deposits in the coronary sulcus can be well demonstrated on either oblique or on a direct lateral view. Regardless of the size of a plaque it should be projected immediately adjacent to the cardiac border at some position in the rotation of the patient through 180 degrees and in no projection should it lie outside of the silhouette of the heart.

Large calcific encasements may result in greatly diminished or absent pulsations as demonstrated fluoroscopically or by kymograms (fig. 4). In some instances, especially where the plaque is small, normal or even increased pulsations may be observed which probably are due to fixation of the base of the heart to mediastinal structures or adhesions to the chest wall.

If the pericardial calcification is occurring as part of a constrictive lesion and interfering with function, additional findings may be apparent. There may or may not be an enlarged cardiac silhouette due to a fibrous layer as much as 2 cm. thick, an actual increase in heart size, or to the presence of an old encapsulated effusion. Enlargement of the superior vena cava occasionally

PERICARDIAL CALCIFICATION

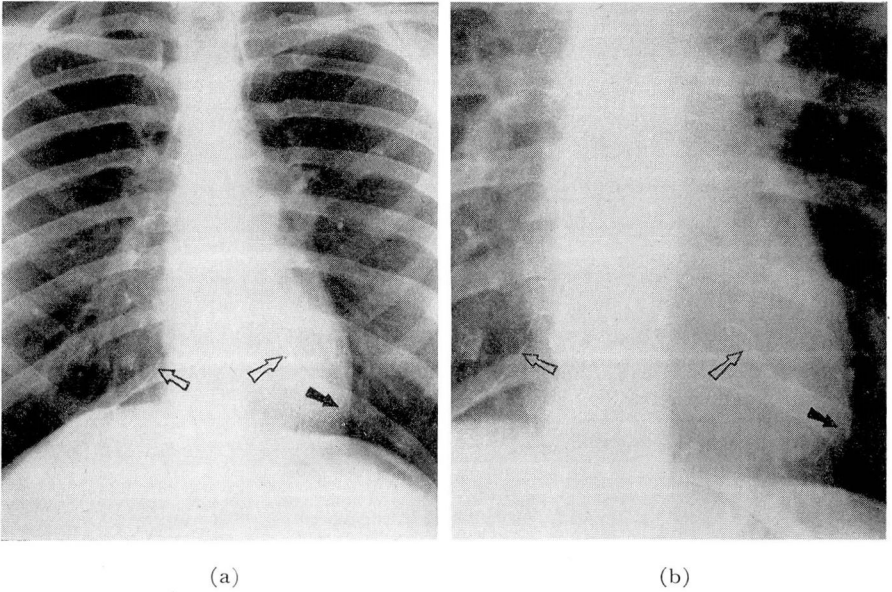


FIG. 3. Minimal pericardial calcification (black arrows) along left ventricle near apex shown in (a) posteroanterior projection, (b) enlarged view. White arrows denote calcified costal cartilages.

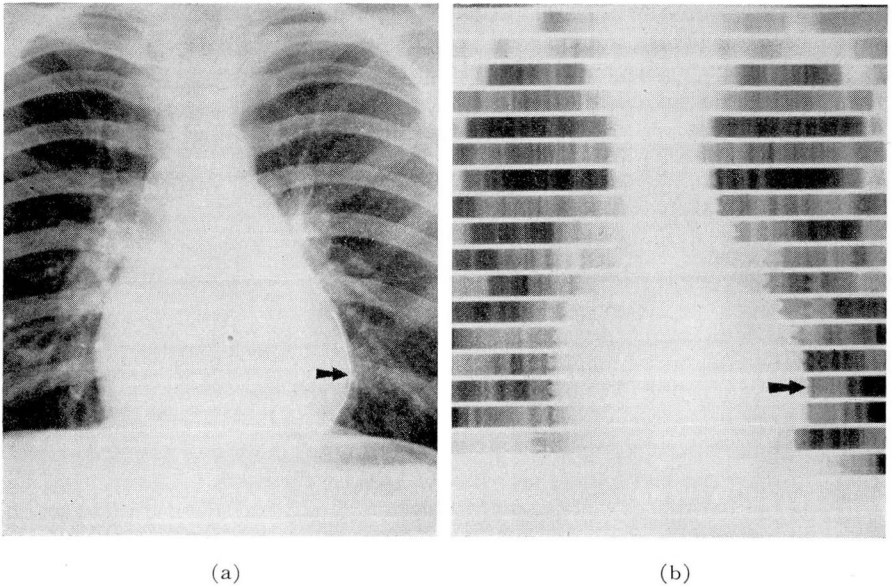


FIG. 4. Extensive pericardial calcification adjacent to left ventricle as seen in (a) posteroanterior view, (b) with greatly decreased pulsations as demonstrated by kymograms.

causes prominence of the right superior mediastinal shadow. Local bulging of the silhouette may occur in uninvolved areas, at times even simulating cardiac aneurysm. Normal or decreased prominence of the pulmonary vascular shadows is customary. Evidence of an old pleural inflammatory lesion frequently is visualized (figs. 1 and 5).

Pericardial calcification must be distinguished from all adjacent extracardial and intracardial calcifications. The calcification of bronchial walls seen frequently in older people may closely follow the heart border in the posteroanterior projection and usually can be recognized as paired, segmental densities easily projected outside the heart on oblique views (fig. 5).

Calcified mediastinal lymph nodes are dense spherical or oval structures readily projected away from the cardiac shadow.

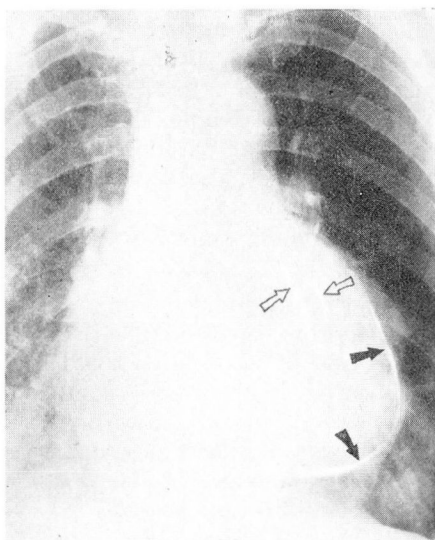


Fig. 5. Extensive pericardial calcification (black arrows). Note segmented calcifications in bronchus (white arrows). Scattered pleural calcifications can be seen to right of cardiac silhouette.

Costal cartilages show multiple patterns of calcification but, in confusing instances, may be distinguished by their extracardiac location (fig. 3). Costal cartilage calcification, as well as calcified mediastinal nodes and bronchial walls do not reveal pulsile motion.

Dermoids, teratomas or neurogenic tumors demonstrating calcification are seldom confusing.

Calcification within the leaflets or free edges of the mitral valve is usually singular and nodular and may simulate calcified lymph nodes. These are most often limited to patients with rheumatic mitral stenosis;^{3,4} hence associated enlargement of the left auricle and right ventricle is seen.⁵ These calcifications are demonstrated best in the right anterior oblique view, are well within the

cardiac border on all projections, and are localized in the plane of the auriculoventricular septum slightly left of the midline. On the left anterior oblique view they are located in the posterior one-third of the heart shadow.

Aortic valvular calcification closely simulates that in the mitral valve except for the location which is usually slightly higher, and in the left anterior oblique view is in the middle one-third of the heart. Like the mitral valve these show vigorous motion when visualized at fluoroscopy. Calcification of other valves does occur but is exceedingly rare.

Calcification of the mitral annulus, usually an incidental occurrence in elderly people, characteristically appears as a dense O, U, or J shaped calcification in the mitral region. Its location is identical with leaflet calcification but the heart is usually normal.

Calcification in the myocardium and even in the adjacent pericardium occurs following myocardial infarction or in ventricular aneurysms secondary to infarction. If the plaque is small and located near the apex, differentiation from calcific pericarditis may be exceedingly difficult. Clinical history, electrocardiographic findings or presence of paradoxical motion are of differential value. Myocardial calcification may also be seen in disturbances of calcium metabolism such as hyperparathyroidism, and rarely in chronic sepsis. In general, myocardial calcification lies slightly deeper within the heart shadow.

Endocardial calcification may occur and its localization within the wall of the left auricle has been described in 5 instances.⁶ Epstein's⁶ 3 patients had rheumatic mitral disease and the calcification is presumed to have been in a MacCallum plaque. This type of calcification could be confused with a ring shaped pericardial calcification in the coronary sulcus. However, the calcification in these instances is found to conform with the anatomic outline of the left auricle and cannot be made to superimpose upon the anterior portions of the cardiac shadow. In the right anterior oblique view it would reveal its close proximity to the barium-filled esophagus.

Coronary artery calcification as demonstrated by Wosika and Sosman⁷ is most commonly seen in the circumflex branch of the left coronary artery, just beneath the pericardium, inferior to the auriculoventricular notch. These are best demonstrated in the right anterior oblique position as faint linear segmental shadows curved convexly upward. They are difficult to demonstrate and must be visualized fluoroscopically or on high speed films.

Calcification of mural thrombi⁸ occur as sharply outlined, rounded, or semilunar dense shadows, projected within the heart chambers. They usually are larger than valve calcification and are seen best in the right anterior oblique position.

Aortic wall or aneurysmal calcification follows the anatomic walls of that structure and generally is not confusing.

Isolated cases of calcification occurring in obliterated ductus arteriosus, cardiac tumor,³ endocardium opposite septal defects, and in the aorta opposite a patent ductus arteriosus⁹ have been reported.

References

1. Schwedel, J. B.: Clinical Roentgenology of the Heart. Annals of Roentgenology, Vol. 18. New York, Paul B. Hoeber, Inc., 1948, p. 309.
2. Roesler, H.: Clinical Roentgenology of the Cardiovascular System, ed. 2. Springfield, Charles C Thomas, 1943, p. 365.
3. Sosman, M. C.: Technique for locating and identifying pericardial and intracardiac calcifications. Am. J. Roentgenol. **50**:461 (Oct.) 1943.
4. Sosman, M. C. and Wosika, P. A.: Calcification in aortic and mitral valves with report of 23 cases demonstrated in vivo by roentgen ray. Am. J. Roentgenol. **30**:328 (Sept.) 1933.
5. Epstein, B. S.: Roentgenologic differentiation of rheumatic from non-rheumatic mitral valve calcifications. Am. J. Roentgenol. **44**:704 (Nov.) 1940.
6. Epstein, B. S.: Left atrial calcification in rheumatic heart disease. Am. J. Roentgenol. **61**:202 (Feb.) 1949.
7. Wosika, P. H. and Sosman, M. C.: Roentgen demonstration of calcified coronary arteries in living subjects. J.A.M.A. **102**:591 (Feb. 24) 1934.
8. Berk, L. H.: Roentgen diagnosis of mural thrombi. Arch. Int. Med. **63**:1183 (June) 1939.
9. Weiss, E.: Calcified plaque of aorta at entrance of patent ductus arteriosus; point in diagnosis. Am. Heart. J. **7**:114 (Oct.) 1931.