

# SPONTANEOUS INTERNAL BILIARY FISTULA

## *A Case of Cholecystocolic Fistula*

ARTHUR G. MICHELS, M.D. and STANLEY O. HOERR, M.D.

Department of Surgery

RECENTLY we had occasion to make the preoperative diagnosis of cholecystocolic fistula and demonstrate this complication of gallbladder disease at operation. The symptoms and roentgen findings were of sufficient diagnostic interest to stimulate this report.

The patient had a history of multiple attacks of acute cholecystitis for many years and apparently developed the cholecystocolic fistula a few weeks before its recognition. The onset of fistula formation was characterized by a period of upper abdominal pain, fever, prostration, and diarrhea. Barium x-ray study of the colon was diagnostic for an internal biliary fistula.

### Case Report

A widow, aged 73, was admitted to the Clinic hospital with a presumptive diagnosis of subsiding acute cholecystitis. Twenty-three years previously a clinical diagnosis of chronic cholecystitis had been made because of a history of recurrent attacks of pain in the right upper abdomen radiating into the right scapular region, often accompanied by nausea and vomiting. The gallbladder had been normal on subsequent repeated cholecystograms until one year prior to admission when gallstones were demonstrated for the first time.

Three weeks before hospital admission the patient experienced a recurrent dull ache in the epigastrium which became progressively intense. She developed a fever ranging from 100 to 102 F. which lasted 5 to 6 days, and passed numerous foul green loose stools. The patient entered a community hospital and during the period of observation was unable to tolerate food. There was no jaundice, no acholic stools or dark urine. She was discharged after the fever subsided and one week later was admitted to the Cleveland Clinic Hospital.

Physical examination revealed an elderly, thin woman who appeared chronically ill. A few rales were evident in the right lung field which cleared with coughing. The liver was moderately tender, enlarged to the level of the right iliac crest and below the umbilicus in the midline; there was also a tender mass in the left periumbilical region which descended with the liver on deep inspiration. Proctoscopic examination revealed multiple small rectal polyps which appeared benign. A needle biopsy of the liver was reported as hemochromatosis. *Streptococcus faecalis* was isolated on urine culture, and cystoscopy demonstrated a diffuse moderate cystitis with a negative retrograde pyelogram.

The patient was placed on Mandelamine with prompt disappearance of all urinary symptoms. X-ray of the colon several days later revealed polypoid changes in the sigmoid colon which were interpreted as a probable neoplasm. In addition there was a fistulous communication between the biliary tree and the hepatic flexure (figs. 1a

and b). The common duct was dilated and the large calculus was suspected of having caused common duct obstruction. As presence of a sigmoid tumor would require immediate attention, the patient was explored through a left lower rectus incision. However, careful examination of the entire left colon failed to reveal evidence of tumor despite the previous x-ray findings; the right upper abdomen disclosed numerous adhesions. The gallbladder was filled with palpable stones and was densely adherent to the right transverse colon. The abdomen was closed and 11 days later the patient was explored through a right midabdominal incision and the cholecystocolic fistula was demonstrated. Two faceted stones in the dilated common duct were removed after division of the fistulous tract and cholecystectomy. A cholangiogram (fig. 2a) made at the time of surgery, shows the dilated common duct and the obstructing calculi. The accompanying cholangiogram (fig. 2b) was made after removal of the calculi. Drainage of the common duct was provided by means of a T tube. The fistulous opening in the right transverse colon was closed with a standard two layer suture technic.

The patient's postoperative course was uneventful and the T tube in the common duct was removed on the sixth postoperative day. Pathologic examination revealed the gallbladder as the site of severe acute and chronic cholecystitis; it contained five faceted stones approximately 1.5 cm. in diameter which were similar to the two calculi removed from the common duct. The cholecystocolic fistula communicated with the fundus of the gallbladder. Nine months later the patient was free from complaints relating to the gastrointestinal tract or abdomen.

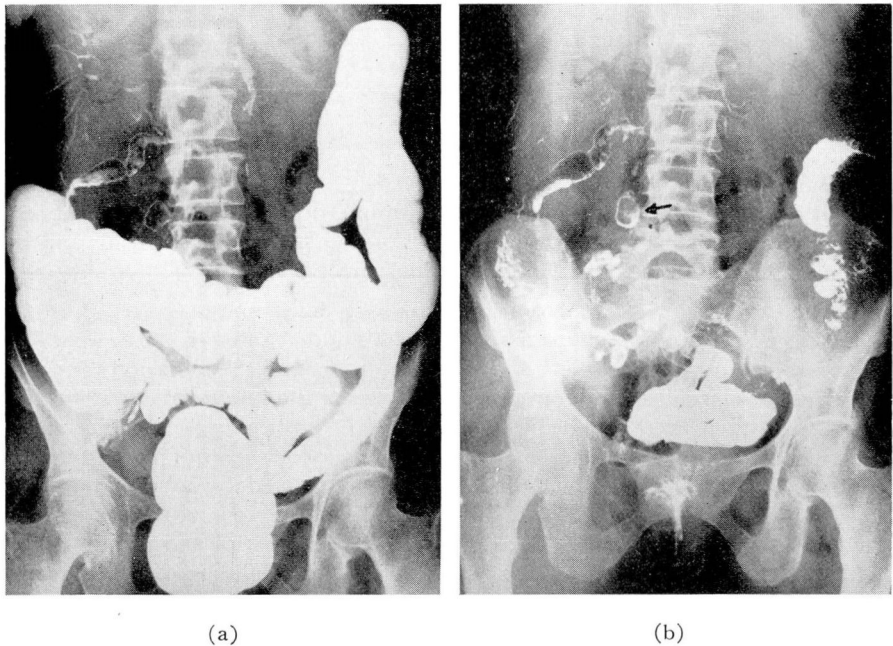


FIG. 1. (a) Barium and gas outlining fistulous communication between biliary tree and hepatic flexure of colon. (b) Barium outlining common duct stone (arrow) right of fourth lumbar interspace.

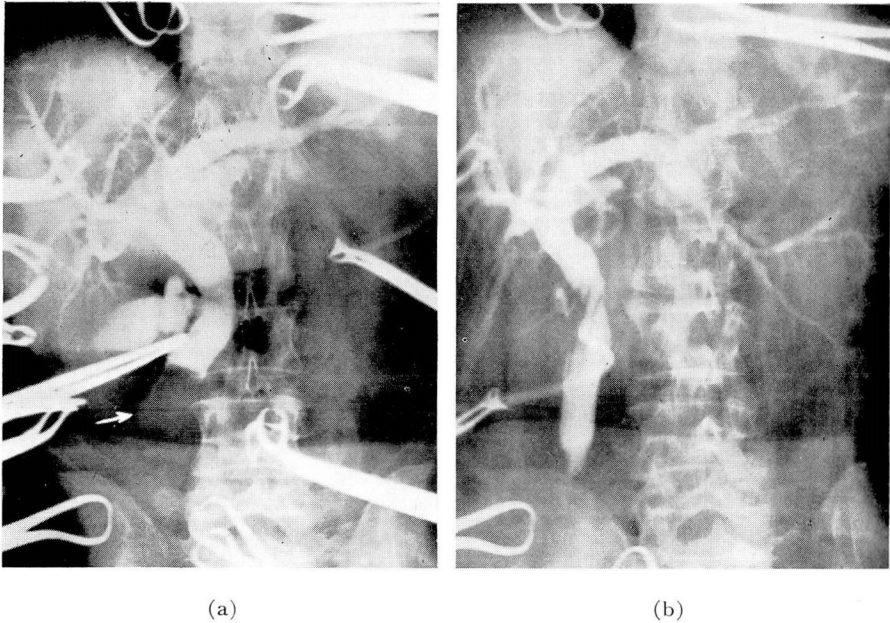


FIG. 2. (a) Cholangiogram made at time of surgery showing dilated common duct and obstructing calculi (arrow). (b) After removal of calculi.

### Etiology

The recognition of spontaneous internal biliary fistulas is uncommon except during surgery or at postmortem examination. The presence of fistulous connections between the biliary tract and other viscera is not unusual, and the commonest of these internal biliary fistulas involve the gastrointestinal tract.

When the gallbladder becomes infected, the inflammatory process usually is localized. The anatomic position of the gallbladder, in close proximity to the surrounding organs, permits its adherence to the adjacent structures. With obstruction of the cystic or common duct, parts of the biliary tree may become densely adherent to neighboring organs; local necrosis may occur, and a stone may be discharged into the intestine or other viscera through the acquired spontaneous fistulous opening. Fistulas may be formed by a second process, i. e. subsequent to rupture of a diseased gallbladder; the resultant pericholecystic abscess may produce necrosis of the intestinal wall and form a fistula, with the abscess cavity providing the tract. Finally, malignant neoplasm or peptic ulcer may initiate a perforation with concomitant fistula formation.

The reflex of gastric or intestinal contents into the biliary tree often produces an extensive cholangitis. Extensive cirrhosis of the liver can result from retrograde infections<sup>1,2</sup> inducing unusual gastrointestinal symptoms. Most biliary fistulas are single; multiple fistulas are rare.

### Incidence

Occurrences of internal biliary fistulas have been reported between any part of the biliary tract and adjacent parts of neighboring organs. Kehr<sup>3</sup> found 100 such fistulas in 2000 routine cholecystectomies; Bernhard<sup>4</sup> demonstrated 109 fistulas in 6,263 biliary operations, and Puestow<sup>5</sup> found 16 fistulas in 500 operations for biliary abnormalities. Hicken and Coray<sup>6</sup> estimated that 4 per cent of all patients requiring surgery for biliary disease have internal biliary fistula.

In 30,000 autopsies, Borman and Rigler<sup>7</sup> found 67 internal biliary fistulas and, in 10,866 autopsies reported by Roth et al,<sup>8</sup> there were 43 internal biliary fistulas.

Most frequently the fistula appears between the gallbladder and the duodenum. The secondary site of occurrence is between the bile ducts and duodenum. Fistulas between the biliary system and the colon, stomach, or other adjacent organs are observed less frequently.

Garland and Brown<sup>9</sup> reported 5 cases of internal biliary fistulas diagnosed preoperatively by x-ray examinations, and summarized the previously reported cases. Of the 90 cases reviewed, 46 were cholecystoduodenal fistulas, 24 choledochoduodenal fistulas, and 10 cholecystocolic fistulas; in 4 the anatomic locations were not determined. Of the remaining 6 cases, 3 were cholecystogastric fistulas, one was a cholecystoduodenocolic fistula, one a choledochogastric fistula, and one a choledochocolic fistula. The presence of an internal biliary fistula does not necessarily imply poor health. McQueeney<sup>10</sup> reported 2 patients having cholecystoduodenal fistulas who enjoyed normal health; in one case the fistula had existed for 19 years, and in the other the fistula had been present for 15 years.

The gastrointestinal viscera, however, are not the only organs violated by spontaneous biliary fistulas. Gallstones have been passed in the urine, and observed in the placenta after labor. Occasionally, even the precordial or pleural cavities are invaded by the contents of a diseased gallbladder. Dean<sup>11</sup> reports that gallstones have been found plugging the portal vein and hepatic artery.

### Diagnosis

The preoperative diagnosis and localization of internal biliary fistulas depend almost entirely upon x-ray examination. Clinical examination rarely suggests biliary fistula unless the patient has a history of having passed gallstones in the stool. Many cases are demonstrated accidentally at the time of operation and any symptoms produced by the fistulous tract usually have been overshadowed by those of gallbladder disease. In recent years preoperative diagnoses have been made more frequently with the increased utilization of roentgen studies in biliary disease and the establishment of criteria for the identification of these fistulas. The most common circumstance is the so-called "gallstone ileus," where acute obstruction of the small intestine is produced by a gallstone. X-ray recognition rests upon the characteristic picture of small

bowel obstruction together with either gas in the biliary tree or a radio-opaque gallstone at the tip of a dilated loop of bowel.

Hunt and Herbst<sup>12</sup> reported the first case diagnosed by x-ray in 1915, and in a series of 153 cases reported by Judd and Burden<sup>13</sup> in 1925 only one case was diagnosed preoperatively. In 1937 Borman and Rigler<sup>7</sup> recognized 86 fistulas preoperatively out of 267 cases.

The positive diagnosis of biliary fistula can be established when barium outlines the tract or portions of the biliary tree, either by oral administration or by means of an enema (figs. 1a and b). Corroborative x-ray findings include the presence of air or residual barium in the biliary tract, nonvisualization of the gallbladder on cholecystography, and changes in the mucous membranes of parts such as the duodenum and colon at the site of the fistula.

Barium x-ray of the colon is the most positive means of making the correct diagnosis of biliary colic fistulas, and air contrast studies are second in reliability. The presence of air in the biliary system, especially the interlobar ducts of the liver, is almost always diagnostic of some abnormal communication between the biliary and digestive systems. Occasionally bacilli infecting the gallbladder will produce enough gas to outline the biliary system, and gas has been known to reflux through the ampulla of Vater into the common duct outlining the bile ducts.

### Symptoms

Weight loss, jaundice, and diarrhea are common symptoms in biliary tract fistula but are not pathognomonic. The weight loss is usually secondary to the diarrhea and the amount of liver damage present. Jaundice is generally due to associated cholangitis and hepatitis resulting from an ascending infection by intestinal organisms. Puestow<sup>5</sup> reported high virulence and acute hepatic infection most prominent in the cases of cholecystocolic fistula; he attributed these to the high bacterial flora count of the colon. Diarrhea is most pronounced in the cholecystocolic fistulas associated with a large tract which permits the full laxative effect of bile to act directly in the colon through the fistula. Most patients feel improved or well after the fistula forms as this permits the inflammatory debris or calculi to be drained spontaneously and to be carried away with the intestinal contents. The formation of a communication between the biliary tree and the gastrointestinal tract may sometimes be a life-saving accident with resultant spontaneous internal drainage.

### Operative Treatment

The presence of an internal biliary fistula increases the risk of surgical intervention many times over that of uncomplicated biliary tract disease. However, a large fistula may so disable a patient that surgical intervention is indicated despite the increased operative risk. Spontaneous closure with permanent remission is rare in these cases.

In order to prevent the formation of biliary fistula the gallbladder and all calculi should be removed in the early stages of biliary tract disease. If oper-

ation is not delayed the massive adhesions and inflammatory reaction which usually accompany such formation may be avoided; these complications increase the technical difficulties of the procedure. Early surgery for cholecystolithiasis would circumvent the possible perforation of the gallbladder at a later date and the resultant high mortality. If the fistula is unrecognized or if the lumen is small at the time of operation, the surgeon may excise the fistula and inadvertently overlook an opening in the bowel. Such an oversight can result in peritonitis. Large fistulous openings or cavities, in these cases, should be drained in the manner of any other intraabdominal abscess after correction of the underlying cause.

### Summary

A case of cholecystocolic fistula has been presented and the pertinent data associated with internal biliary fistulas briefly reviewed. An accurate pre-operative diagnosis of cholecystocolic fistula was made by means of a barium x-ray study of the colon and confirmed at operation. This complication of gallbladder disease can be avoided by early removal of the seriously diseased gallbladder.

### References

1. Jenkinson, D. L. and Lowry, H. M.: Cholecystocolic fistula diagnosed by roentgen examination; case report and review. *Am. J. Roentgenol.* **60**:658 (Nov.) 1948.
2. Lovell, D. L.: Internal biliary fistulas; report of case. *South. Surgeon* **13**:152 (Feb.) 1947.
3. Kehr: cited by Puestow.<sup>5</sup>
4. Bernhard, F.: Die Fruh- und Spatergebnisse der Cholecystogastrostomie, der Cholecystoduodeno- und Choledochoduodenostomie bei 128 Fallen. *Ztschr. f. Chir.* **242**:736, 1934.
5. Puestow, C. B.: Spontaneous internal biliary fistula. *Ann. Surg.* **115**:1043 (June) 1942.
6. Hicken, N. F. and Coray, Q. B.: Spontaneous gastrointestinal biliary fistulas. *Surg., Gynec. and Obst.* **82**:723 (June) 1946.
7. Borman, C. N. and Rigler, L. G.: Spontaneous internal biliary fistula and gallstone obstruction, with particular reference to roentgenologic diagnosis. *Surgery* **1**:349 (March) 1937.
8. Roth, Schroeder and Schloth: cited by Judd.<sup>13</sup>
9. Garland, L. H. and Brown, J. M.: Roentgen diagnosis of spontaneous internal biliary fistulae, especially those involving the common bile duct. *Radiology* **38**:154 (Feb.) 1942.
10. McQueeney, A. M.: Internal biliary fistulae and intestinal obstruction due to gallstones. *Ann. Surg.* **110**:50 (July) 1939.
11. Dean, G. O.: Internal biliary fistulas; discussion of internal biliary fistulas based on 29 cases. *Surgery* **5**:857 (June) 1939.
12. Hunt and Herbst: cited by Jenkinson and Lowry.<sup>1</sup>
13. Judd, E. S. and Burden, V. G.: Internal biliary fistula. *Ann. Surg.* **81**:305 (Jan.) 1925.