

# CYSTOSARCOMA PHYLLODES MAMMAE, FIBROSARCOMA VARIANT

## *A Case Report*

A. H. ROBNETT, M.D.

Department of Surgery

JOHN B. HAZARD, M.D.

Department of Pathology

and

R. S. DINSMORE, M.D.

Division of Surgery

THE term cystosarcoma phyllodes, originating more than a century ago is attributed to Johannes Muller who, in 1838, utilized it "to designate the cauliflower-like masses of connective tissue which fill a cystic cavity in the breast."<sup>1</sup> In 1941 Owens and Adams<sup>2</sup> listed thirty different names for the same lesion, and agreed with other authors that a more appropriate term was giant intracanalicular fibroadenoma of the breast.

Confusion regarding the exact nature of the lesion still exists, principally in relation to actual or potential malignancy; i. e. whether it is basically sarcomatous or benign. Although cases reported have emphasized that the lesion is benign in a vast majority of instances, ultimately lethal sarcoma has been noted also. In 1950 Steckler and Landman<sup>3</sup> found in the literature 3 reported cases of cystosarcoma phyllodes with metastases and described a fourth of their own. Saltzstein and Pollack<sup>4</sup> stated in 1949 that, in a review of 52 cases of cystosarcoma phyllodes, Pollack found 8 to be cancerous. McDonald and Harrington<sup>5</sup> protested the use of the term cystosarcoma phyllodes, believing that 90 per cent of the lesions so termed are benign and the other 10 per cent are fibrosarcoma. They agree with and quote Deaver's statement that "Large tumors of intracanalicular myxomatous type are not sarcomas and the term cystosarcoma should be abandoned."<sup>5</sup>

The following case report illustrates the accepted clinical and pathologic characteristics of cystosarcoma phyllodes with areas of fibrosarcoma in the stroma.

## Case Report

Three years prior to examination the patient, a nulliparous white woman of 53, first noted itching and light "shock-like" pains in the left breast and a few weeks later discovered a small mass in the left breast. The mass exhibited only slight increase until 2 weeks prior to admission when there was sudden rapid development which continued

until the entire breast was involved by a mildly painful, draining lesion the size of a grapefruit (fig. 1).

Examination disclosed a large, bosselated growth, the nodular protuberances varying in diameter from 5.0 cm. to 2.0 cm. The overlying skin was red and small superficial ulcers which drained pink fluid surmounted the tumor. The breast was not tender and was freely movable over the chest wall. No axillary or supraclavicular adenopathy was palpable.

The remainder of the examination, including routine laboratory studies and chest x-ray, was within normal limits.

A provisional diagnosis of cystosarcoma phyllodes was made and a simple mastectomy was performed under general anesthesia with removal of the breast and the external pectoral fascia, but not the pectoral muscles. A large skin defect remained which was successfully covered with a split-thickness skin graft.

Postoperative examination at the end of 10 months failed to reveal evidence of local recurrence or adenopathy in the supraclavicular and axillary zones.

### Pathology

**Gross Examination:** (Fig. 2) The specimen consisted of a cone-shaped breast 11.0 cm. across the base and 12.0 cm. in height, weighing approximately 800 Gm. There was normal appearing skin around the base, but at the apex

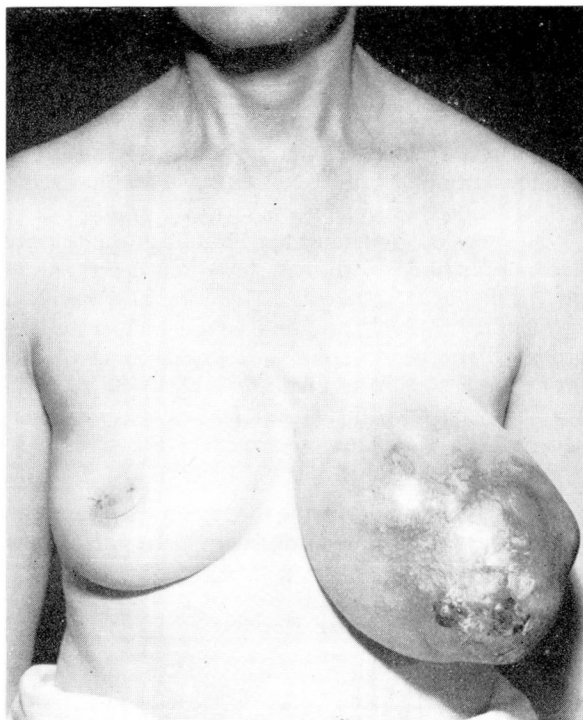

FIG. 1. Greatly enlarged left breast with marked skin changes including ulceration.

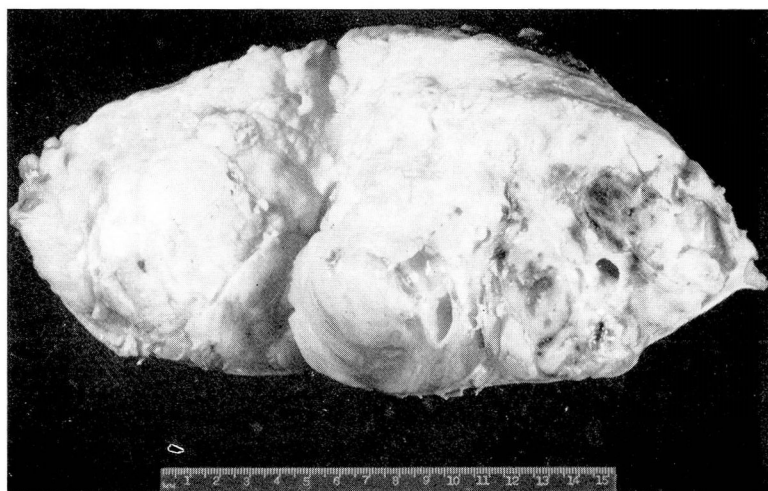

FIG. 2. Sectioned surfaces of gross specimen showing lobulated large tumor mass with bulging surfaces, partly smooth, homogeneous, and in part cystic. Neoplasm comprises major portion of specimen.

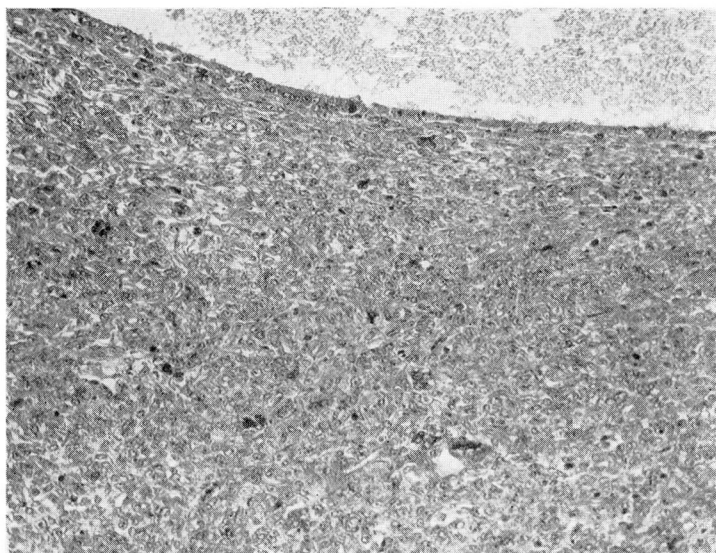
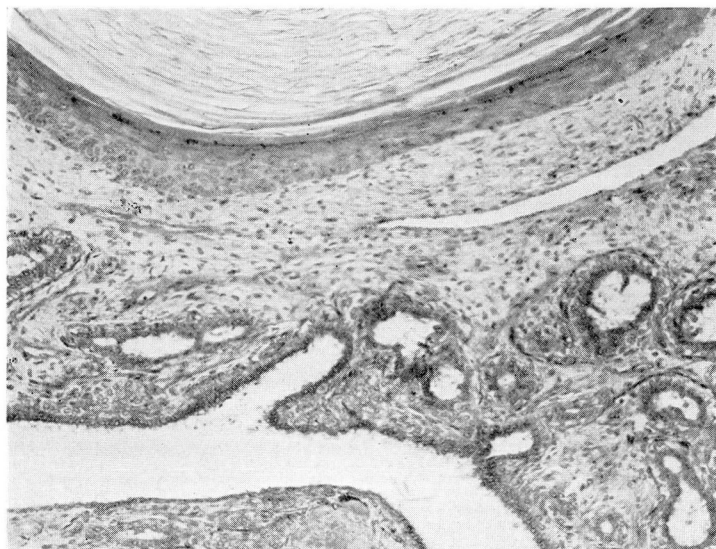
of the cone the skin was thinned, erythematous and glistening, and the surface nodular; these protuberances measured 5.0 x 3.0 cm. for the largest and 2.0 cm. for the smallest. Near the apex of the specimen the skin was ulcerated in several places and through these areas bulged red and pink friable tissue. The nipple was present near one of these ulcerated zones. Palpation of the external surface gave the impression of multiple nodules of firm tissue within the breast substance and not attached to the skin. On section, the specimen was found to be composed almost entirely of a coarsely lobulated fleshy tumor mass having irregular areas variably firm, soft, hemorrhagic and of necrotic appearance. There were numerous cystic structures present, containing opaque, gray-white material and averaging 1 cm. in diameter. The mass was demarcated from surrounding breast and fatty tissue, but there was no capsule. Muscle tags and fascia separated it from the deep line of excision.

**Microscopic Examination:** (Fig. 3) The neoplasm was formed by abundant connective tissue stroma and epithelial-lined spaces, at times irregular due to finger-like projections of stroma covered with epithelium. The epithelial cells for the most part appeared in several layers and were well-differentiated. In zones of fairly frequent occurrence circumscribed patches of squamous epithelium were observed, including keratinized masses. The stroma was of variable density, mostly loose and myxomatous, but with dense fibrous patches. In addition to these well-differentiated zones there were stromal areas of marked cellularity, cells round or spindle-shaped with frequent mitoses and occasional giant nuclear forms. The margins of the neoplasm were well-separated from the adjoining tissue. The zones of ulceration presented partly necrotic and myxomatous tissue projecting through the skin defect. Breast tissue outside the large mass was not unusual.



Pathologic diagnosis: cystosarcoma phyllodes, in part fibrosarcoma, of breast (left); squamous metaplasia, ulceration.

(a)



(b)

FIG. 3. (a) Microscopic section illustrating benign area with characteristics of fibroadenoma and with zones of squamous metaplasia (x70). (b) Microscopic section showing malignant area characterized by increased cellularity of stromal zone adjoining cyst. Many tumor giant cells and mitoses were present (x100).

## Discussion

In 1931 Lee and Pack,<sup>6</sup> in a comprehensive survey of their own cases and 107 cases from the literature, concluded that the lesion developed from pre-existing intracanalicular fibroadenoma at a time of gelatinous metamorphosis of the stroma. As a rule a small mass had been known to exist for a number of years with little if any growth before a sudden acceleration to great size occurred; the average weight in their series was 7.6 pounds. Grossly the tumor was lobulated with variable areas of resistance and fluctuation and seemed to be encapsulated without invasion of the breast tissue. There was mobility and nonadherence to the skin or fascia. On section intracystic polypoid excrescences were observed separating fluid containing clefts. The stroma was myxomatous with cellular pseudosarcomatous zones. Lee and Pack were of the opinion that wide excision constituted successful treatment. In 91 cases discussed there were 6 recurrences.

In regard to history and gross appearance the lesion reported herein coincides with the cases described by Lee and Pack as giant intracanalicular fibroadenoma of the breast and as cystosarcoma phyllodes mammae by Johannes Muller. The presence of focal fibrosarcoma in the stroma places it as a malignant variant.

Unfortunately the term cystosarcoma phyllodes has a connotation of malignancy although the neoplasm, according to reported cases, is most often benign. It is not always possible, however, to discard a long-recognized term and it has been retained in this report. To prevent misunderstanding it seems necessary to qualify this basic diagnosis in order to indicate whether the tumor is benign or malignant. Since both epithelial and connective tissue elements are present, it is also important to designate the type of malignancy. Thus, in this case report we have chosen the complete diagnosis of cystosarcoma phyllodes, in part fibrosarcoma. Where no apparent malignancy exists the most logical diagnostic term would appear to be cystosarcoma phyllodes, fibroadenoma type, benign.

Because of the presence of sarcomatous change the advisability of further and more radical surgical therapy might be proposed. We concur in the opinion of Geschickter who has stated, "Since intracanalicular myxomas of giant size do not, as a rule, metastasize to the regional lymph nodes, whether or not the stroma shows the histologic features of sarcoma, amputation of the breast including the pectoral fascia and without axillary dissection is the treatment of choice."<sup>7</sup> However our patient is being followed for evidence of recurrence since this has been recorded in a small percentage of patients.

## Summary

1. A case of cystosarcoma phyllodes, in part fibrosarcoma, is presented to exemplify the clinical characteristics and the accepted treatment of the disease.
2. The gross and microscopic appearance of the lesion is illustrated.
3. Although this lesion is generally benign, malignant variants have been

reported. Clarity in diagnosis requires that the term cystosarcoma phyllodes be modified to indicate the presence or absence of malignancy.

### References

1. Ewing, J.: *Neoplastic Diseases, a Textbook on Tumors*. Philadelphia, W. B. Saunders Company, 1919, p. 4.
2. Owens, F. M., Jr. and Adams, W. E.: Giant intracanalicular fibro-adenoma of breast. *Arch. Surg.* **43**:558 (Oct.) 1941.
3. Steckler, C. and Landman, M.: Cystosarcoma phyllodes with metastasis. *New York State J. M.* **50**:339 (Feb. 1) 1950.
4. Saltzstein, H. C. and Pollack, R. S.: Benign tumors of breast. *J.A.M.A.* **140**:997 (July 23) 1949.
5. McDonald, J. R. and Harrington, S. W.: Giant fibro-adenoma of the breast, cystosarcoma phyllodes. *Ann. Surg.* **131**:243 (Feb.) 1950.
6. Lee, B. J. and Pack, G. T.: Giant intracanalicular fibro-adenomyxoma of breast. So-called cystosarcoma phyllodes mammae of Johannes Muller. *Am. J. Cancer* **15**:2583 (Oct.) 1931.
7. Geschickter, C. F.: *Diseases of the Breast*, ed. 2. Philadelphia, J. B. Lippincott Company, 1947, p. 323.