

ACUTE PORPHYRIA

S. R. LA TONA, M.D.* and ADRIAN FOE, M.D.

Department of General Medicine

PORPHYRIA is a metabolic disease characterized by excessive excretion of porphyrins in the urine and feces. Clinically it appears to occur in two forms, congenital and acute. Congenital porphyria is rare and is distinguished by red discoloration of the teeth and bones and by photosensitivity of the skin. The acute form is much more common. It is actually a chronic disease characterized by remissions and exacerbations, with symptoms involving principally the nervous and gastrointestinal systems. Both forms are thought to be hereditary, the congenital being transmitted as mendelian recessive and the acute as mendelian dominant.¹ The following patient represents a case of acute porphyria.

Case Report

A 26-year-old housewife entered the Clinic complaining of "bad nerves." She had felt well until 4 weeks before admission when she developed "grippe" with chilly sensations, myalgias, transient diarrhea, and generalized crampy abdominal pain. The chilly sensations and diarrhea disappeared after 1 or 2 days. No fever was present. The patient continued to experience intermittent crampy abdominal pain, became constipated and required the use of repeated laxatives and enemas. She lost her appetite and vomited occasionally. There was a loss of 31 pounds during this period. In addition she had two attacks characterized by weeping, hyperventilation, carpal spasm, and inability to speak clearly; each lasted about 10 minutes. No loss of consciousness or sphincter control accompanied these episodes. As a result the patient became depressed and apprehensive. She was observed in a local hospital for 2 weeks, and was given barbiturates repeatedly for sedation. Her symptoms were ascribed to "nerves."

Family history revealed no similar illness. Her past history disclosed that she had experienced approximately six similar mild attacks of generalized abdominal pain beginning about the age of 15; each had lasted only a few hours. In 1947, during the second trimester of pregnancy, she underwent a similar attack accompanied by nausea and vomiting lasting 3 or 4 days. Her difficulty was diagnosed as acute appendicitis and she underwent an appendectomy, the pathologic findings of which are not known. There were no postoperative complications; however, 11 days later she had a recurrence of pain which lasted 3 weeks but subsided without further treatment. The patient subsequently delivered a healthy full-term baby after which she felt well until the onset of the present illness. Further questioning revealed that she had first noted dark brown discoloration of urine, coincident with the attack of "grippe" and this persisted until the time of admission to the Clinic.

Physical examination showed normal temperature and blood pressure. The pulse was 120 and respirations 24 per minute. The skin was sallow. There was no discoloration of the teeth. Slight generalized muscle tenderness was apparent and the abdominal

*Former Staff Assistant, now practicing in Niagara Falls, New York.

reflexes were absent; the right Babinski reflex was equivocal; bilateral nystagmus on lateral gaze was evident on one occasion. The abdomen was soft and no masses were palpable.

Laboratory studies included normal blood counts and negative blood serology. Cephalin flocculation, thymol turbidity, and Tiselius protein fractionation were within normal limits. The fasting blood sugar was 92 mg. per cent, and a glucose tolerance test exhibited slight elevation at 30 and 60 minutes. Urinalysis showed a trace of albumin, and the urinary sediment contained occasional erythrocytes and 4 to 8 white blood cells per high power field. Freshly voided urine varied in color from amber to light brown, and turned dark brown on standing. Schwartz-Watson tests for urine porphobilinogen were repeatedly positive. Chest and skull x-rays showed no abnormality. An electroencephalogram was reported as "borderline with no evidence of epilepsy nor of focal cortical lesion." Proctoscopic examination and barium enema were negative. Exposure of the skin to ultraviolet radiation revealed no sensitivity. Neuropsychiatric examination suggested an anxiety hysteria reaction.

The patient was hospitalized for 11 days. She remained afebrile and manifested a slow fall in pulse and respiration to near-normal limits. Cramping abdominal pain was relieved by prostigmine bromide. One episode of visual hallucinations subsided spontaneously. She was discharged symptomatically improved. However, her local physician reported that she died several weeks later from ascending paralysis which affected first the legs and then the arms. No autopsy was performed.

Discussion

Acute porphyria is said to occur predominantly in women, usually in the third or fourth decades. Photosensitivity is rare. Pigmentation of the teeth does not occur although the skin may show diffuse pigmentation. Dark brown or red discoloration of the urine may appear intermittently, usually coincident with clinical activity of the disease. This discoloration may increase with standing or exposure to sunlight. Symptoms involve principally the nervous system and gastrointestinal tract.^{1,2,3}

Gastrointestinal symptoms commonly include generalized crampy abdominal pain, nausea, vomiting, and severe constipation. Abdominal tenderness is poorly localized, and rigidity is slight or absent. The clinical picture may suggest an "acute abdomen" consistent with acute appendicitis, cholecystitis, pancreatitis, or intestinal obstruction. Many of these patients have been subjected to unnecessary and dangerous surgical procedures. The importance of considering acute porphyria in the differential diagnosis of the "acute abdomen" has been recently re-emphasized.⁴

Neurologic manifestations are variable in severity and character.^{5,6} There may be involvement of both cranial and peripheral nerves. Weakness or paralysis of the extremities and the facial muscles is fairly common; ascending paralysis has been reported in a number of cases. Sensory changes are less common, but pain, paresthesias, and anesthesia have been recorded. Mental disturbances are observed frequently, and vary from irritability and hysteria to toxic psychosis with delusions and hallucinations. Convulsions may occur. The combination of mental symptoms with atypical neurologic and abdominal signs is often strongly suggestive of psychoneurosis, an impression inferred

by several observers in the case presented. Roth⁵ has emphasized the frequent absence of knee jerks with intact ankle jerks, and the summation phenomenon in which tendon reflexes become increasingly active with continued tapping.

In 1941 Watson and Schwartz suggested a simple test to identify porphobilinogen—a substance which is excreted in the urine in acute (not congenital) porphyria.⁷ Porphobilinogen, in the presence of Ehrlich's reagent and sodium acetate, is converted into an aldehyde insoluble in chloroform. It is readily distinguished from urobilinogen, which is completely extracted into the chloroform layer (figure). Subsequent studies have revealed that false positives are extremely rare, and the test is considered reliable in the diagnosis of acute porphyria.⁸

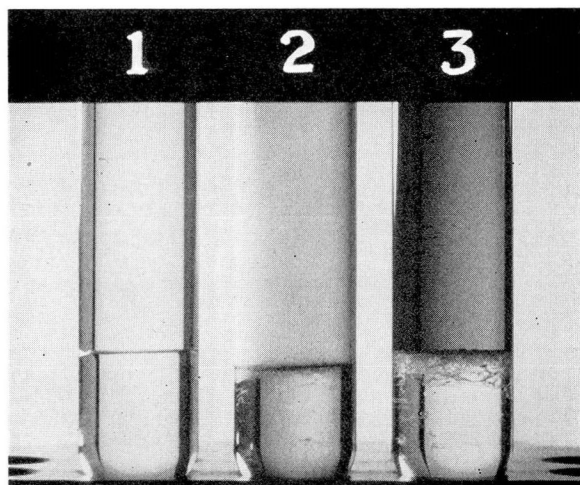


FIGURE. Watson test for porphobilinogen. Tube 1 is negative. Tube 2 is positive for urobilinogen (chloroform layer). Tube 3 is positive for porphobilinogen (water layer).

There is no specific treatment for the disease. Certain drugs have been reported as having initiated attacks in some instances and should, therefore, be avoided. These include barbiturates, sulfonamides, lead, alcohol, acetanilid, nitrobenzol, salvarsan, and trional. Prostigmine, which has been suggested for relief of abdominal cramps, seemed to be helpful in this patient.

Summary

A case of acute porphyria has been reported. It illustrates some of the commonly reported clinical and laboratory findings in this metabolic disorder. Porphyria should be considered in the differential diagnosis of cases presenting obscure abdominal and neurologic findings.

References

1. Nesbitt, S.: Acute porphyria. *J.A.M.A.* **124**:286 (Jan. 29) 1944.
2. Hayman, J. M., Jr.: Porphyria. *Ohio State M. J.* **45**:800 (Aug.) 1949.

3. Prunty, F. T. G.: Acute porphyria; investigations on pathology of porphyrins and identification of excretion of uroporphyrin I. *Arch. Int. Med.* **77**:623 (June) 1946.
4. Calvy, G. L.: Porphyria; a consideration in surgical diagnosis. *Surg., Gynec. and Obst.* **90**:716 (June) 1950.
5. Roth, N.: Neuropsychiatric aspects of porphyria. *Psychosom. Med.* **7**:291 (Sept.) 1945.
6. Schneck, J. M.: Porphyria; neuropsychiatric aspects in case of Negro. *J. Nerv. and Ment. Dis.* **104**:432 (Oct.) 1946.
7. Watson, C. J. and Schwartz, S.: Simple test for urinary porphobilinogen. *Proc. Soc. Exper. Biol. and Med.* **47**:393 (June) 1941.
8. Hammond, R. L. and Welcker, M. L.: Porphobilinogen tests on 1,000 miscellaneous patients in search for false positive reactions. *J. Lab. and Clin. Med.* **33**:1254 (Oct.) 1948.