

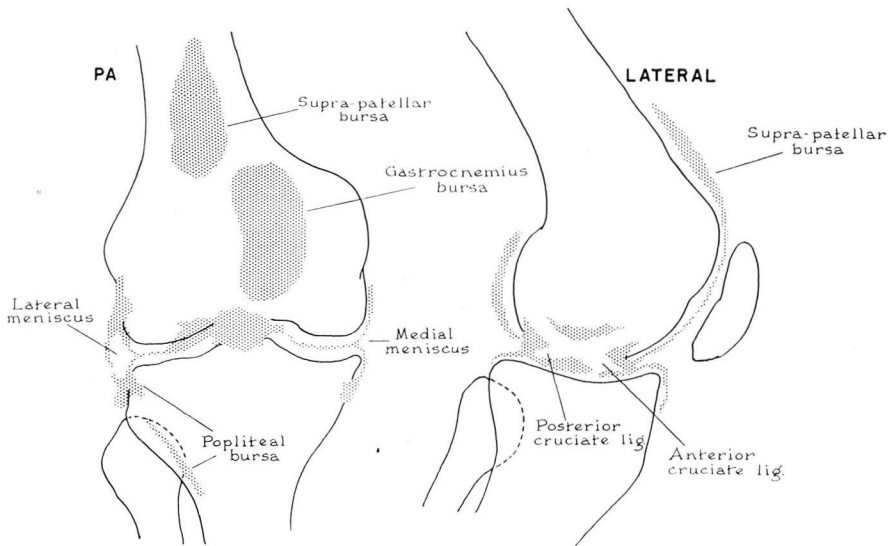
DIODRAST ARTHROGRAPHY OF THE KNEE

ROBERT M. GEIST, JR., M.D., CHARLES C. WHITSETT, M.D.
and C. ROBERT HUGHES, M.D.

Department of Roentgenology

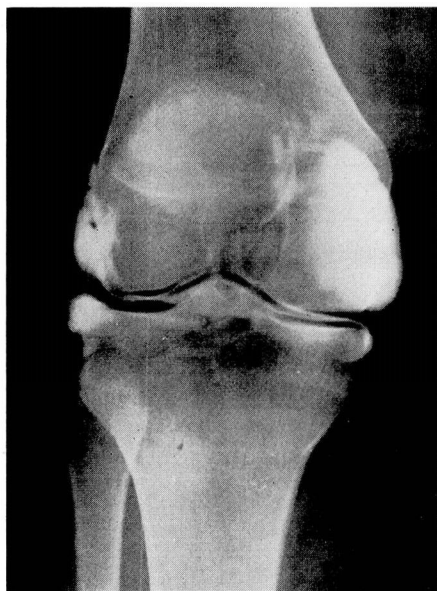DURING the past 20 years contrast arthrography of the knee has enjoyed varying degrees of popularity. For the most part the contrast medium employed has been air or oxygen. Enthusiasm has been discouraged in this type of examination because of the actual technical difficulty of obtaining adequate contrast by means of gas. In our experience poor contrast and poor filling have made accurate diagnosis practically impossible. As a result we had discarded contrast arthrography until recent months. Its revival was based on the valuable work of Lindblom,¹ who has carried out some 6000 arthrograms employing parabrodil (diodrast) as the contrast media.

This article constitutes a preliminary report of our first 22 consecutive examinations of this type. To date the results have been good. The sharp contrast obtained with 35 per cent diodrast makes even the minimal pathologic change within the realm of accurate preoperative diagnosis (fig. 1a, b and c). This is partially explained on the ability of the iodine salt solution to mix with the synovial fluid and be imbibed on the cartilage and ligament surfaces. Sec-

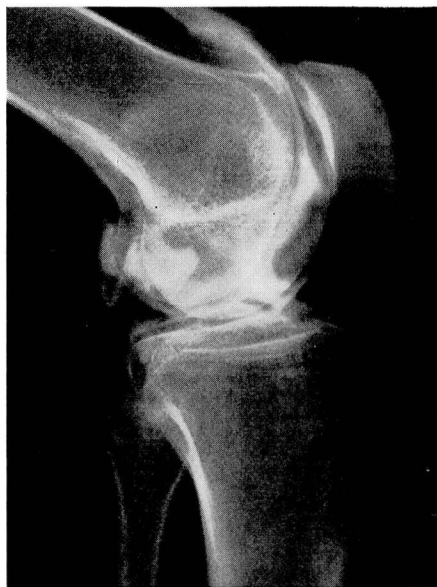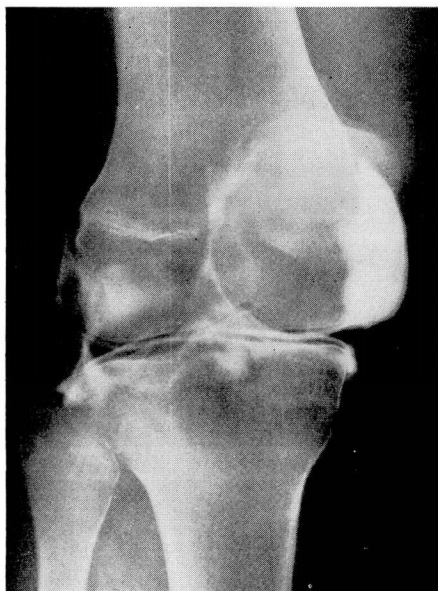


DIAGRAMS OF DIODRAST ARTHROGRAMS OF KNEE

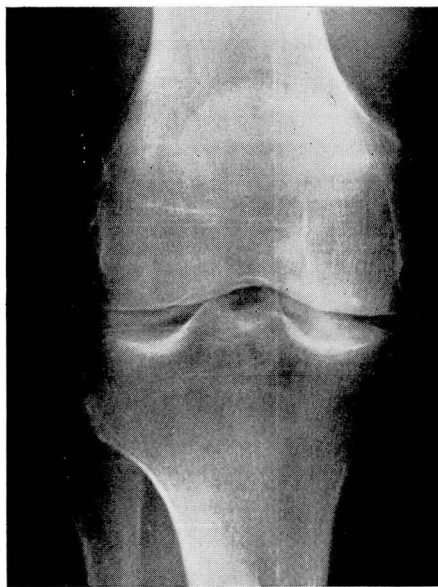(a)



(b)



(c)



(d)

FIG. 1. (a, b and c) Normal posteroanterior, 45 degree oblique, and lateral views of diodrast arthrogram of knee. (d) Normal appearance of arthrogram one-half hour after injection of diodrast showing rate of absorption of opaque media.

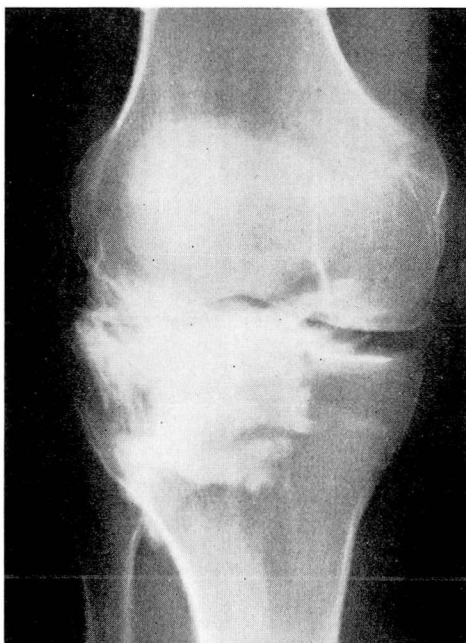


FIG. 2. Diodrast in infrapatellar fat pad due to error in injection.

tions of the synovia at surgery showed no microscopic evidence of reaction to the contrast media. The procedure is simple and requires no special equipment.

A number 20 needle is inserted into the knee joint from the lateral side, angling beneath the patella. Any synovial fluid present is aspirated and 10 cc. of 35 per cent diodrast is injected. The knee is then manipulated to spread the media over the joint surfaces. Compression is applied on the anterior medial and the anterior lateral aspect of the suprapatellar area by means of pads held in place by an ace bandage. This forces the diodrast from the suprapatellar bursa into the joint space for better contrast. Anteroposterior, posteroanterior, lateral, and 45 degrees oblique stereoscopic films are then exposed. The stereoscopic shift is 6 degrees and is of great importance in the proper localization of small collections of opaque media at the menisci. A routine film is made one-half hour after the injection for evaluation of the absorption ability of the synovial membrane. Normally only a trace of diodrast remains at this time (fig. 1d). No technical difficulties were encountered in the procedure except on one occasion when the opaque media was injected into the infrapatellar fat pad (fig. 2). There was no clinical reaction, however, and the diodrast was rapidly absorbed. Almost all patients we have examined were referred from the Department of Orthopedics and represented cases of old and new trauma involving cartilage and ligaments. As a result our pathologic findings consist of tears of the medial and lateral menisci, ruptures of the anterior cruciate ligament,

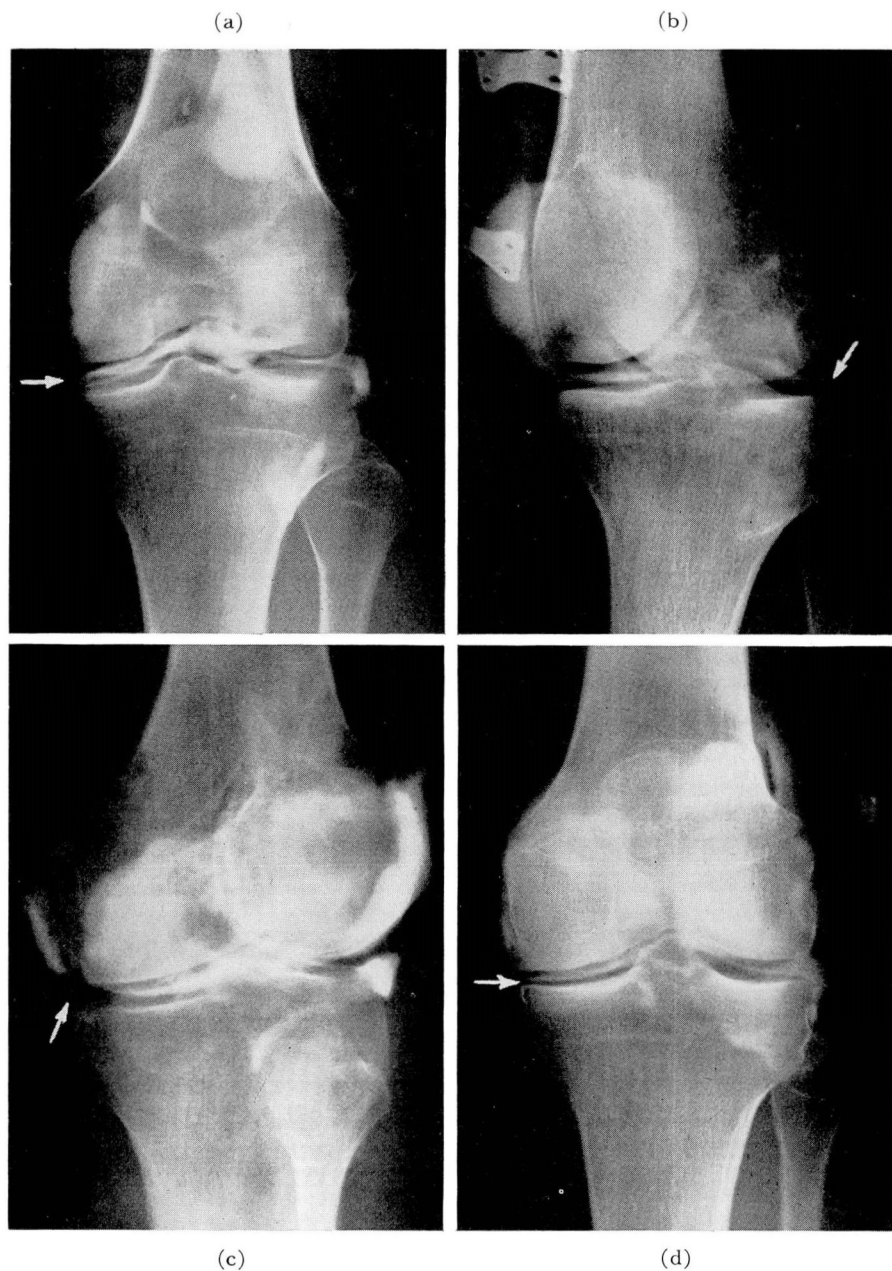


FIG. 3. (a and b) Diodrast arthrograms showing a tear in medial and lateral meniscus respectively as indicated by arrows. (c) Tear in medial meniscus as occasionally demonstrated by filling defect and associated aberrant bursa. (d) Postoperative arthrogram showing absence of medial meniscus.

DIODRAST ARTHROGRAPHY OF KNEE

CLINICAL	PLAIN FILMS	ARTHROGRAM	SURGERY
Tear anterior and posterior cruciates Tear medial meniscus	Normal left knee	Tear lateral miniscus, posterior Tear anterior cruciate ligament	Tear lateral, miniscus Tear anterior cruciate
Tear med. men.	Normal right knee	Normal	No
Tear med. men.	Normal right knee	Tear med., men., post.	Tear med. men., post.
Tear med. men., post.	Normal right knee	Normal	No
Tear med. men.	Narrowing med. joint space with minimal arthritic changes; left knee	Tear med. men., ant.	Tear med. men., ant.
Surgical absence of med. men. Residual internal derangement Synovitis	Slight narrowing med. joint space; left knee	Absent med. men. ? Tear lat. men., lat. and post. Baker's cyst Deformity ant. cruciate Chronic synovitis	Absent med. men. Normal lat. men. Baker's cyst Chronic synovitis
Med. men. injury Synovial thickening; minimal	Min. osteoarthritis; left knee	Tear med. men., lat. and post.	Tear med. men.
Cyst lat. men.	Normal right knee	Atypical changes, lat. men.	Tear lat. men.
Baker's cyst. Possibly a fragment of post. med. men. remaining	Slight narrowing med. joint space	Small Baker's cyst; incomplete removal med. men.	No
Tear med. men.	Normal right knee	Tear lat. men., post.	No
Tear med. men.	Normal right knee	Tear lat. men., post.	No
Tear med. men.	Normal right knee	Tear med. men., lat. and post. Separation ant. portion of capsule from med. men.	Tear med. men.
Tear med. men., ant.	Normal right knee	Normal	No
Tear med. men.	Normal right knee	Tear med. men., lat.	No
? Tear lat. men. ? Discoid men. ? Cyst lat. men., post.	Normal left knee	Normal	No
Tear med. men.	Normal left knee	Incomplete filling about med. cartilage with atypical med. bursa indicative of med. men. lesion	Tear med. men., post. Atypical bursa adjacent to post. med. men.
Tear med. men.	Normal right knee	Tear med. men., lat. and post. Tear lat. med., lat.	No
Tear med. men.	Normal right knee	Large Baker's cyst	No
Cyst lat. men.	Normal left knee	Normal	No
Tear med. men., post.	Normal left knee	Normal	No
Tear med. men.	Normal left knee	Tear med. men., post. Luxation of fragment of med. men. into inferior recess	No
Chronic mild med. Collateral ligament strain	Normal left knee	Normal	No

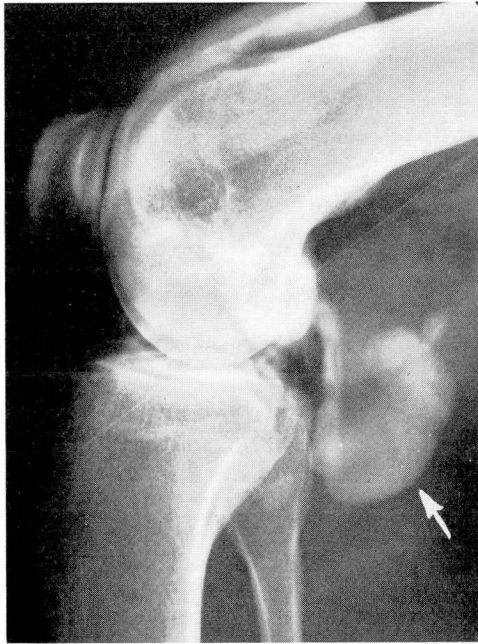

FIG. 4. Lateral diodrast arthrogram demonstrating large Baker's cyst.

and Baker's cysts (figs. 3, 4). Although in many cases the arthrogram was only confirmatory, in occasional instances the findings were remarkable and hitherto unsuspected (table).

Summary

Contrast arthrography with the use of 35 per cent diodrast is apparently a simple, safe, and accurate means of diagnosing pathologic changes of the knee joint induced by trauma. A further study is indicated to determine its usefulness in varying arthritic conditions.

Reference

1. Lindblom, K.: Arthrography of knee. *Acta radiol. Supp.* 74, p. 1-111, 1948.