

# BRAIN TUMOR IN INFANCY

## *Report of Case With Four-Year Follow-up After Surgical Removal*

A. T. BUNTS, M.D.

Department of Neurosurgery

**A**LTHOUGH tumors of the brain are encountered with moderate frequency during childhood, their occurrence during the first year of life is distinctly rare. Stern<sup>1</sup> found 62 intracranial tumors in children under the age of 12 at 2808 consecutive autopsies at the Great Ormond Hospital; of these, 6 occurred during the first year of life. Critchley<sup>2</sup> reported 125 brain tumors in children under the age of 16 among a total of 1028 cases of brain tumor; only 1 of these occurred in an infant under the age of one year. Cushing,<sup>3</sup> in a series of 1108 verified intracranial tumors, found 24 in children younger than 5 years; one of these proved to be a teratoma in an infant 2 months of age. Gross<sup>4</sup> reviewed the literature concerning tumors of the brain during the first 2 years of life, citing 9 cases which had been reported from 1861 to 1931; to these he added 9 cases which he had observed in the same age group. In a series of 100 intracranial tumors occurring in children under 15 years of age, Smith and Fincher<sup>5</sup> encountered none during the first year of life. In a review of the literature of cases of brain tumor occurring during the neonatal period (the first 60 days of life) Arnstein et al<sup>6</sup> found 13 reports of such lesions prior to June 1950 and added a case of angioma of the choroid plexus in a 3 day old infant. Bailey et al<sup>7</sup> in their complete monograph reviewed a series of 100 cases in children younger than 16 years of age; of these, 5 occurred during the first year of life and 7 during the second year. No reference will be made to the many interesting papers in which small numbers of cases in early childhood have been reported; most of them are cited in the bibliographies or reference lists of the authors mentioned.

In childhood, gliomas predominate over other types of brain tumor (75 per cent) and occur most frequently in the subtentorial region. Among the gliomas in this age group, the astrocytoma and the medulloblastoma are the more common. The rarity of meningeal tumors in childhood is notable, and this is particularly true in infancy. Bailey and Ingraham<sup>8</sup> reported 3 cases of intracranial fibrosarcoma of the dura, one in an infant 27 days old. It seems possible that their case 3 may have been a benign meningioma of fibroblastic type.

Brain tumors during the first year of life usually are not recognized before death and autopsy, since the clinical picture is most likely to lead to a diagnosis of congenital hydrocephalus. The following case report will illustrate some of the difficulties of diagnosis. Fortunately the tumor which was encountered in this baby proved to be a meningioma of fibroblastic type, and the growth shows no signs of recurrence 4 years after its surgical removal.

### Case Report

A baby boy, 6 months old, was brought to the Clinic by his parents on January 20, 1947 because of an enlarged head and spasms. He was the fourth child of the mother and apparently had been normal at birth. His siblings were normal children and had shown normal development. At the age of 3 months the patient began to experience involuntary muscular contractions in which the legs became stiff, the arms flexed, and the eyes rolled. Since that time the parents had noticed progressive enlargement of the baby's head.

Examination revealed a large head, whose circumference was 50 cm., a small face, a bulging anterior fontanel, and widely separated skull sutures. There was no demonstrable evidence of paralysis of the arms or legs. Ophthalmoscopic examination showed 2 or 3 diopters of papilledema in both eyes.

Roentgenograms of the skull showed enormous enlargement. As measured on the films, the anteroposterior diameter was 17 cm. and the vertical diameter 16.5 cm. The sella turcica showed no erosion. The bones of the skull were thin and the anterior fontanel was enlarged. No calcifications were visible. There was moderate asymmetry of the skull in the posteroanterior projection, the left side being slightly larger than the right side. The superior orbital margins were indistinct, especially on the left side, and the orbits appeared to be somewhat more widely separated than normal.

A diagnosis of congenital hydrocephalus was made, and it was suggested to the parents that the baby be admitted to the hospital for further studies and possible excision of the choroid plexuses, although the prognosis in any event appeared distinctly unfavorable.

The infant was admitted to the hospital on January 29, 1947. On the following day a needle was inserted through the scalp at the left angle of the anterior fontanel and

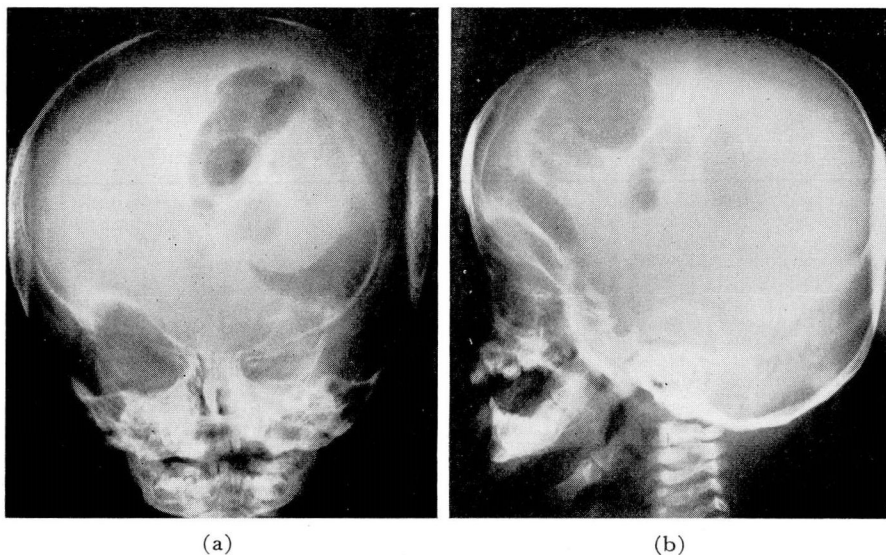


FIG. 1. Roentgenograms after intracranial injection of air on left side showing bizarre bubble formation. Lower mass of air in anteroposterior view suggests outline of inferior surface of tumor.

presumably into a dilated left ventricle. Fifty cc. of yellow fluid was aspirated and coagulated in the test tube. The fluid contained 140 lymphocytes per cu. mm., a heavy trace of globulin, and 3300 mg. of total protein per 100 cc. Lumbar puncture was then performed and clear colorless cerebrospinal fluid was obtained. The lumbar fluid contained 6 cells and 297 mg. of total protein. The following day the right angle of the anterior fontanel was punctured and at a depth of 7.5 cm. clear, colorless fluid was encountered, presumably in the right ventricle. The fluid from the right side contained only 2 cells per cu. mm. and only 155 mg. of total protein. These studies caused us to abandon the diagnosis of congenital hydrocephalus, inasmuch as the yellow fluid with its high protein content suggested the presence of organic disease, either inflammatory or neoplastic, in the left side of the brain. On February 6, 1947 an attempt was made to gain further information by ventriculography; 30 cc. of air was injected into the left side of the head through the anterior fontanel after removing a small quantity of yellow fluid. The roentgenograms demonstrated loculated collections of air, probably bubbles, scattered throughout the parietal, temporal, and frontal regions on the left side (fig. 1). There was no air on the right side of the head. No definite diagnosis could be made from these films, but the possibility of cystic changes or neoplasm in the left cerebral hemisphere was considered.

Operation was advised, and on February 11, 1947 a scalp flap was turned down in the left parietal area and a disk of bone about 1.5 inches in diameter was removed with scissors. When the dura was opened, a thin-walled transparent cyst bulged through the opening. Numerous blood vessels coursed in the wall of the cyst. The cyst was opened and 30 cc. of clear yellow fluid was removed by aspiration. Through the opening in the skull, brain tissue could be seen in the posterior part of the cranial cavity on the left side. The anterior half of the left cerebral hemisphere appeared to be atrophic or compressed by the encysted fluid and by a large, firm, encapsulated tumor. This growth seemed to be rather closely attached to the dura underlying the coronal suture on the left side. The posterior aspect of the tumor was gradually exposed by cotton dissection

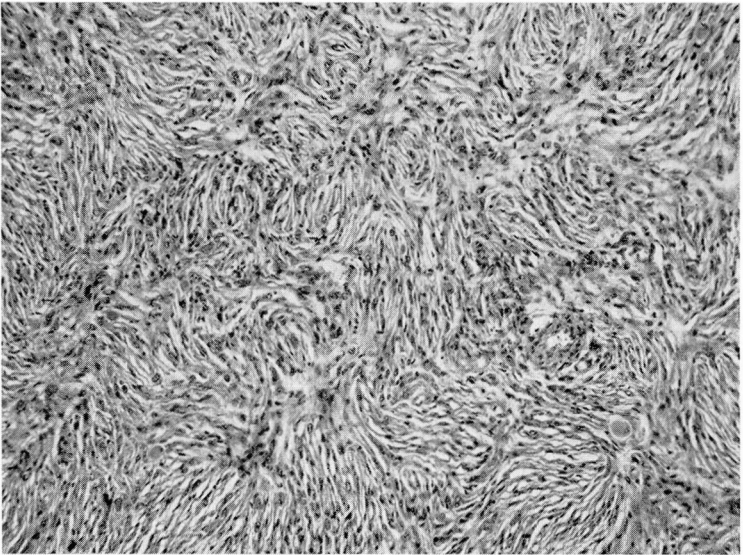


FIG. 2. Photomicrograph of fibroblastic meningioma which was removed in this case (x70).

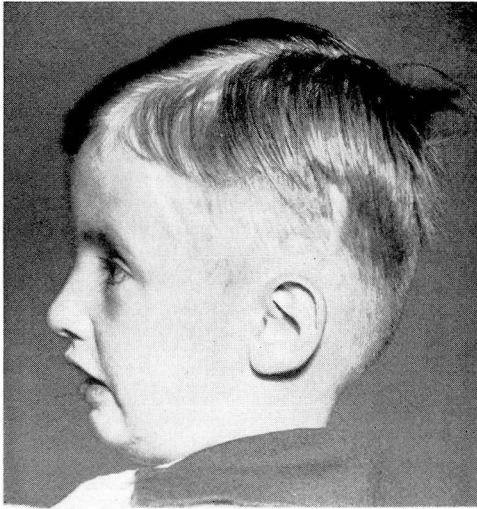

FIG. 3. Patient  $3\frac{1}{2}$  years after operation.

and approximately two-thirds of it was removed by means of the electric loop. The tumor was exceptionally hard and avascular, and its cut surface was white in color. The portion of the tumor which was not removed at this operation appeared to extend forward into the frontal part of the cranial cavity on the left side. Because of the baby's age, and the duration of the operation, it was considered wise to postpone further removal of the tumor until a later date. The dura was partially closed with nylon sutures, the bone disk was replaced and anchored with nylon sutures, and the scalp incision was closed.

On February 22, 1947 the surgical wound was opened and the remaining portion of the tumor was removed. Its attachment to the dura underlying the coronal suture was divided with the electric knife. The lateral aspect of the tumor was encapsulated, but its medial aspect appeared to be more intimately associated with brain tissue of the left cerebral hemisphere. All of the hard tumor tissue was removed, and it is probable that small portions of cerebral tissue were removed with it. At the end of the procedure the left cerebral hemisphere was found to be atrophic, its surface lying 2 inches below the inner table of the skull. The dura was then loosely closed, and the bone disk replaced and anchored at four points with nylon sutures. The scalp was closed with interrupted nylon sutures.

The baby developed a low-grade postoperative staphylococcal meningitis which fortunately responded well to penicillin, and he was afebrile for a week before discharge from the hospital on March 19, 1947.

The microscopic appearance of the tumor was described by Dr. John B. Hazard, Cleveland Clinic Pathologist, as follows: "The mass is formed by slender spindle-shaped cells arranged in short interlacing bundles. Nuclei are elongated or oval and appear well differentiated. In some of the marginal zones, the tissue is somewhat more cellular; in one section the spindle-shaped cells extend into cerebral tissue. Invading tumor cells encase patches of glial tissue in this area. In addition to the spindle-shaped cells, there are some plump cells of moderate size with abundant pink cytoplasm and with somewhat vesicular nuclei. A PTAH stain shows fine collagen bundles between these spindle-

shaped cells. No mitoses are apparent. Pathologic diagnosis: "Meningioma, fibroblastic type, apparently slowly growing" (fig. 2).

The child has been examined at intervals since operation for a period of more than 4 years, the latest observation occurring on August 2, 1951. At that time his mother stated that he had been well and had experienced no convulsions. He had begun to talk at the age of 2½ years and to walk at the age of 3 years. Examination showed the boy to be in good general condition, but with a persistent right hemiparesis. He walked with a circumduction type of gait. Although his speech was limited, he was able to name objects and to use many simple words. There was no papilledema. An electroencephalogram showed abnormal delta waves from the left frontal and parietal areas. Measures were instituted for rehabilitation of the right arm and leg. His parents plan to have him start school in September 1952. (Fig. 3).

### Discussion

A review of the literature and of the case presented above makes it clear that intracranial tumors in infancy are not only rare but difficult to diagnose before death or operation. In the vast majority of cases a rapid increase in the size of an infant's head is due, not to the presence of a tumor, but rather to so-called "congenital hydrocephalus." The latter condition may be the result of stenosis of the aqueduct, nonpatency of the foramina of Luschka and Magendie, the Arnold-Chiari malformation, inadequate absorption of cerebrospinal fluid in the cortical subarachnoid pathways, or other causes. Nevertheless, the possibility of intracranial tumor should be borne in mind when an infant exhibits a rapidly enlarging head, convulsions, and vomiting. Aspiration of xanthochromic fluid from one side of the cranial cavity through the bulging anterior fontanel should cause one to suspect tumor, particularly if the fluid is found to contain a large quantity of protein. Air studies may be of some assistance. Finally, of course, the presence of a tumor can be determined only by operation or by necropsy. Occasionally a surgical effort may be rewarded by the discovery and removal of a benign neoplasm, as in the case reported.

### References

1. Stern, R. O.: Cerebral tumors in children; pathological report. *Arch. Dis. Childhood* 12:291 (Oct.) 1937.
2. Critchley, M.: Brain tumors in children; their general symptomatology. *Brit. J. Child. Dis.* 22:251 (Oct.-Dec.) 1925.
3. Cushing, H.: Intracranial tumors of preadolescence. *Am. J. Dis. Child.* 33:551 (April) 1927.
4. Gross, S. W.: Tumors of brain in infancy; clinical and pathologic study. *Am. J. Dis. Child.* 48:739 (Oct.) 1934.
5. Smith, W. A. and Fincher, E. F.: Intracranial tumors in children; preliminary study of 100 cases. *South. M. J.* 35:547 (June) 1942.
6. Arnstein, L. H., Boldrey, E. and Naffziger, H. C.: Case report and survey of brain tumors during neonatal period. *J. Neurosurg.* 8:315 (May) 1951.
7. Bailey, P., Buchanan, D. N. and Bucy, P. C.: *Intracranial Tumors of Infancy and Childhood.* Chicago, University of Chicago Press, 1939.
8. Bailey, O. T. and Ingraham, F. D.: Intracranial fibrosarcomas of dura mater in childhood; pathological characteristics and surgical management. *J. Neurosurg.* 2:1 (Jan.) 1945.