

INTRACRANIAL EPENDYMOMA

Clinicopathologic Observations

EDWIN R. FISHER, M.D. and JOHN B. HAZARD, M.D.

Department of Pathology

and

W. JAMES GARDNER, M.D.

Department of Neurosurgery

UNTIL recently, little has been added to our knowledge of the ependymal group of gliomas as first described by Bailey¹ in 1924. In the following year, Bailey² presented the results of the study of 5 cases designated as ependymoblastoma and 7 as ependymoma. These results originated the conception that the tumors were malignant primarily because of their predilection for the fourth ventricle, a site presenting surgical difficulties in the complete removal of such growths. Although the impression has persisted that ependymoblastomas grow more rapidly and are more malignant lesions than ependymomas, analysis of the first series reported by Bailey and Cushing² failed to corroborate this assumption. Also, Bailey later recognized the fact that, insofar as prognosis was concerned,³ the difference between these tumors was minimal. His conclusion was emphasized further by Davidoff³ and later by Mabon et al⁴ and Penfield.⁵

Kernohan and Fletcher-Kernohan⁶ in 1937 subdivided the ependymomas into the following subtypes: (1) epithelial, (2) cellular, (3) myxopapillary and (4) papillomas of the choroid plexus. This classification also included the neuroepithelioma of Bailey and Cushing in the general group of ependymomas. Although an attempt was made to correlate the prognosis with these individual subdivisions, the results were unsatisfactory. More recently (1949), Mabon, Svien, Kernohan and Craig⁴ reviewed 57 cases of ependymoma in which the patients were operated upon, and graded the neoplasms according to pleomorphism of nuclei and cytoplasm, hyperchromatism, mitotic figures and preservation of architecture. They found a close correlation between the degrees of dedifferentiation of these gliomas and the survival periods of the patients. The results revealed survival rates to be inversely proportional to the degree of anaplasia or grade of the tumor.

The purpose of this study was to apply these same principles of gradation to a group of ependymal tumors seen at the Cleveland Clinic from 1933 to 1948. It was hoped that such an analysis would offer histologic criteria for the predictability of growth rate or prognosis.

Material

Thirteen cases of ependymoma which were referred to surgery were observed during the previously mentioned 15 year period. One additional case was

disregarded because the follow-up study was incomplete. The tissue was fixed in 10 per cent formalin or Zenker's fluid. All slides from each individual case were reviewed. The sections were stained with hematoxylin, eosin and methylene blue, Mallory's phosphotungstic acid hematoxylin and Masson's trichrome stain. Mitotic figures were noted and recorded as the number per twelve high power fields. Actually all fields available were studied for mitoses. The estimation of cellularity, stroma, and rosette formation was relative and was classified as 4 plus, 3 plus, 2 plus, 1 plus. Since the group was small, this method presented little difficulty. Coincident evaluations were obtained on four different occasions, and two observers independently agreed upon these designations. In regard to uniformity of cell cytoplasm, it was discovered that, for the most part, the cell outline was indefinite and this feature could not be estimated accurately. The occurrence of the nuclei in symplasmic masses in this type of tumor has not been stressed as a histologic feature. Because of this absence of well defined cell margins, pleomorphism must depend upon nuclear variation. A well differentiated growth demonstrated 75 per cent or more of the nuclei to be uniform. Moderate dedifferentiation was considered when 50 to 75 per cent of the nuclei appeared similar. Less than 50 per cent uniformity was considered to indicate marked dedifferentiation. The terms "rosette" and "pseudorosette" in this discussion are defined as follows: A true rosette is a cuff of cells arranged about a central space; the term pseudorosette is reserved for that structural arrangement of cells which surround a blood vessel or central mass of fine fibers. The histologic studies were performed prior to the tabulation of the clinical data to avoid undue subjective influence.

Results

Age and Sex. Of the 13 patients studied, 8 were women and 5 men. The mean age for the group at the time of operation was 19.3 years; the ages ranged from $2\frac{1}{2}$ to 44 years.

Duration of Symptoms Prior to Surgery in Relationship to Survival (table 1). Inaccuracy is recognized in the evaluation of onset of symptoms, and amplified, perhaps, in analyzing the symptoms of brain tumor, viz., headache and nausea and vomiting, since many other illnesses can produce such episodes. The onset of symptoms accepted as indicative of brain tumor was established at the time when symptoms became either progressive or persistent. It is obviously impossible to estimate the duration of the lesion prior to onset so that the exact inception of a given neoplasm is not known. Using the previously described criteria, it was found that the mean duration of symptoms prior to operation was $10\frac{1}{2}$ months. The average postoperative survival time of patients, including 3 who died immediately after operation, was 22 months. This is a minimal estimation, as it includes those still living. In 7 patients with symptoms 5 months or less, 5 survived 15 to 88 months postoperatively, and 2 deaths occurred 2 and 19 months postoperatively. Of 6 patients whose symptoms endured for a period longer than 5 months, 2 were living 11 and 12 months postoperatively and 1 died 7 months after operation, 3 died post-

Table 1

Preop. Symptoms Duration (mos.)	Postop. Survival (mos.)	Total Duration Disease (mos.)	Site	Removal
1/2	21 1/2	22	fourth vent.	partial
1	17	18	parietofront.	aspirated
1	15	16	parietotemp.	partial
2	88	90	parietofront.	'complete'
5	28	33	parietofront.	'complete'
5	19*	24*	fourth vent.	partial
5	2*	7*	fourth vent.	aspirated
10	11	21	fourth vent.	partial
10	**	10**	lat. vent.	partial
13	12	25	fourth vent.	partial
13	7*	20*	fourth vent.	partial
30	**	30**	fourth vent.	biopsy
41	**	41**	fourth vent.	partial

*Dead
**Operative death

Table 2

Cellularity	Mitoses (12hpf)	Degree Differ.	Rosettes	Site	Total Survival (mos.)
4+	8	poor	P-mod.	fourth vent.	7*
3+	2	well	T-many	parieto-frontal	90
3+	0	well	P-many	parieto-frontal	33
3+	0	well	T-many	parieto-frontal	24*
3+	14	mod.	P-mod.	fourth vent.	22
3+	1	well	P-many	fourth vent.	21
3+	3	mod.	T-mod.	fourth vent.	20*
3+	0	well	P-many	fourth vent.	20*
3+	0	well	P-few	parieto-frontal	18
3+	1	mod.	T-mod.	parieto-temp.	16
3+	14	mod.	P-rare	lat. vent.	10**
2+	0	well	T-few	fourth vent.	41**
2+	0	mod.	P-few	fourth vent.	30**
1+	0	well	P-mod.	fourth vent.	30**
1+	0	well	none	fourth vent.	25

T—True Rosettes
P—Pseudorosettes
*—Dead
**—Operative death

operatively. Thus, in this small group, there is an inverse relationship between duration of symptoms and survival.

Site and Removal in Relationship to Postoperative Survival (table 1). Eight of the 13 neoplasms were located in the fourth ventricle. Of these 2 occurred in patients who died postoperatively but had symptoms prior to operation for periods of 30 and 41 months; 3 died 7 to 19 months after operation with total duration of disease 7 to 24 months, and 3 were living 11, 12 and 21½ months after surgery was performed. Three tumors were found in frontal areas and all patients were living 17 to 88 months postoperatively. One patient with an ependymoma in the parietotemporal region was living 15 months after operation and has survived the disease 16 months. The tumor removed from the lateral ventricle occurred in a patient who died postoperatively but had experienced symptoms for 10 months prior to operation.

Two tumors which were considered to have been completely removed recurred at the original site, proving these observations erroneous. The tumors were located superficially in accessible regions in the parietofrontal lobes, and these patients survived the longest, 28 and 88 months postoperatively (total duration of disease 33 and 90 months). In 8 patients removal was partial, according to the notes of operation. The average postoperative survival time has been 7.2 months and total duration of the disease 22.2 months.

In one only a biopsy specimen was taken as the lesion was considered inoperable. The lesion was in the fourth ventricle and the patient died in the postoperative period after having had symptoms for 10 months. In the remaining 2 patients operations were performed with removal of the cyst wall. One of these tumors lay in the frontoparietal region and the patient was living 17 months postoperatively and has survived 18 months since the onset of symptoms. In the other case the lesion was in the fourth ventricle. The patient died 2 months after operation and survived the disease only 7 months.

Apparently tumors located in accessible and nonobstructing regions of the brain offer the longest survival period regardless of completeness of removal.

Histologic Studies

This phase was undertaken for the purpose of studying morphologic details and correlating histologic features of these neoplasms with survival rate, such as Mabon et al demonstrated in a much larger series. Due to re-operation, 4 cases provided two and three specimens at various time intervals and comparative studies could be made.

Cellularity (table 2). It is generally agreed that ependymal tumors are highly cellular neoplasms. The patient with a 4 plus cellularity died 2 months postoperatively and survived her disease for 7 months from the estimated date of onset. This was the shortest survival period of the entire series. Nine patients had neoplasms demonstrating 3 plus cellularity. Of these, 6 patients are still living, an average survival period of 29 months from onset of symptoms. This coincides closely with the value of the entire group (28.2 months). The 3 patients who died had an average survival rate of 8.3 months. Included in

this latter group is one postoperative death. Each patient had a tumor of the fourth ventricle and 2 of the 3 experienced symptoms for more than 5 months prior to operation. The 2 lesions demonstrating 2 plus cellularity occurred in patients who died postoperatively and who had experienced an estimated 40 and 30 months' duration of symptoms prior to surgery; each period was longer than the average for the entire group. Both tumors were located in the fourth ventricle. One lesion graded 1 plus was from a patient who remains alive 12 months subsequent to surgery; the total duration of the disease has been 25 months, which approaches the average of the entire group.

Although there is no relationship between the site of tumor and the degree of cellularity, a lower degree of cellularity in tumors from similar sites appears to offer a more favorable prognosis. A degree of 3 plus cellularity in lesions of the fourth ventricle indicate a much lower survival period than 3 plus lesions located elsewhere. The former show an average postoperative survival period of 10.6 months and a disease duration totaling 19.4 months; those patients having lesions not located in the fourth ventricle have average survivals of 37 postoperative months and 39.2 months of total duration of disease. These latter values are minimal since all patients are still living.

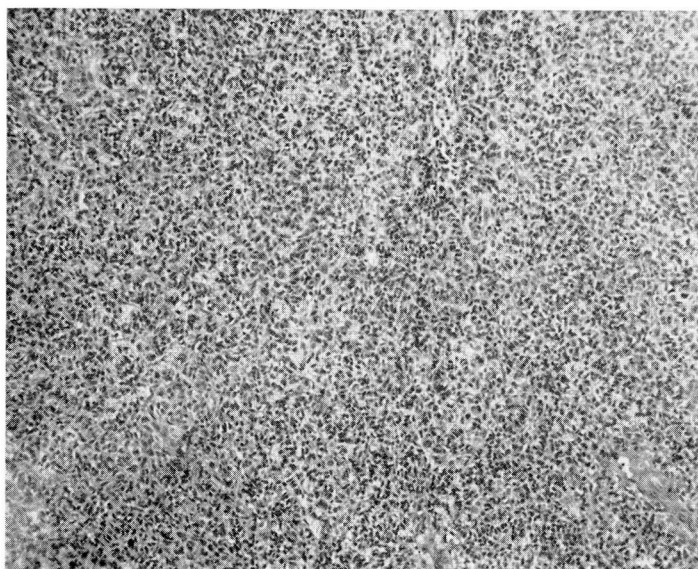
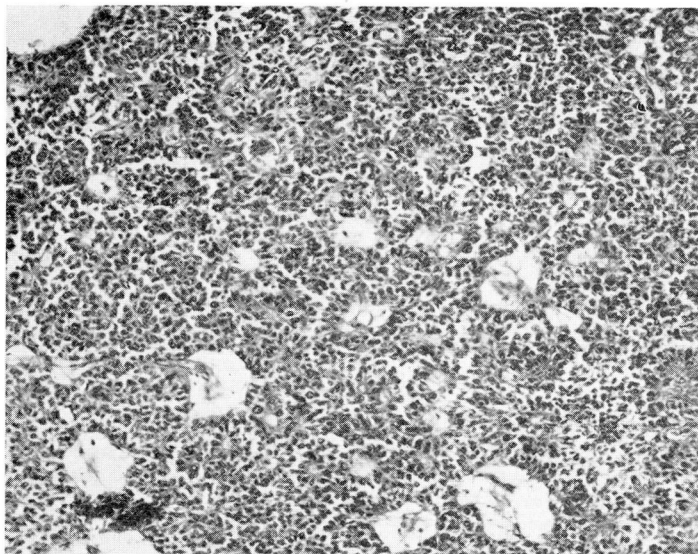
Mitoses and Pleomorphism (table 2). There appears to be a direct linear relationship between pleomorphism and the number of mitoses in these tumors. Of the 7 lesions which demonstrate mitoses 2 were considered to be uniform, 4 moderately uniform and 1 pleomorphic. Those lesions showing moderate uniformity have more mitotic figures than those considered uniform. Of the remaining lesions not showing mitoses 5 were uniform and 1 moderately uniform.

Insofar as survival is concerned there is not as direct a relationship. The average postoperative survival period in this series for the 6 patients with tumors without mitoses has been 19 months with a total duration of disease of 28 months. Conversely, the 7 lesions demonstrating mitoses occurred in patients having an average postoperative survival period of 24 months and total disease duration of 26 months.

Table 3

Case No.	Operation	Interval Between Operations (mos.)	Change in Mitoses (12hpf)	Change in Cellular- ity	Change in Differ.	Change in Rosettes	Change in Stroma
1	2nd	32	2-6	3+-3+	well-mod.	many-mod.	same
	3rd	43	6-12	3+-3+	mod.-mod.	mod.-mod.	more neuroglia
2	2nd	10	0-0	3+-3+	well-mod.	many-mod.	same
	3rd	17	0-0	3+-3+	mod.-mod.	mod.-few	more collag- enous
3	2nd	14	1-12	3+-4+	mod.-poor	mod.-few	same
4	2nd	7	3-2	3+-3+	mod.-mod.	mod.-mod.	same

(a)



(b)

FIG. 1. (a) Tumor from initial operation revealing numerous true and false rosettes (x70). (b) Tumor from second operation 14 months later demonstrating absence of rosettes. Smaller cell type (x70).

Thus pleomorphism and mitoses in this series have been of little value in the prediction of survival.

Rosette and Pseudorosette Formation (table 2). Interestingly, there does not appear to be any direct relationship between the number of rosettes, either true or false types, and the previous histologic details noted, especially mitotic figures and cellularity. Conversely, an inverse proportion is observed, indicating that this important architectural feature is preserved in more dedifferentiated tumors.

Stroma. The stroma of ependymal tumors has received little attention. It was noted that two common types exist in these lesions: (1) a collagenous stroma not only about vessels, but also arranged as septa coursing through the tumor and among individual cells; (2) a fine fibrillary type staining blue with phosphotungstic acid hematoxylin, evident among tumor cells. One neoplasm demonstrated a third type, an amorphous matrix which stained acidophilic with hematoxylin and eosin. No relationship between the stroma, either quantitatively or qualitatively, and cellularity, mitoses, pleomorphism or survival periods could be determined.

Vessels. Ependymal tumors frequently are vascular, especially in those tumors exhibiting many pseudorosette formations with vascular cores. Reduplication of vessels was noted in only one instance. This neoplasm was also poorly differentiated, of 4 plus cellularity, and contained 8 mitoses per twelve high power fields. This patient survived 2 months postoperatively with a total disease duration of 7 months. Fibrinoid change was noted in one tumor. In this patient the disease had persisted for 20 months.

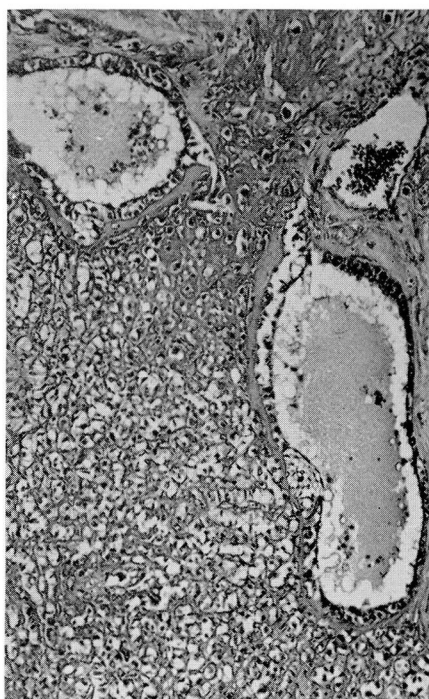
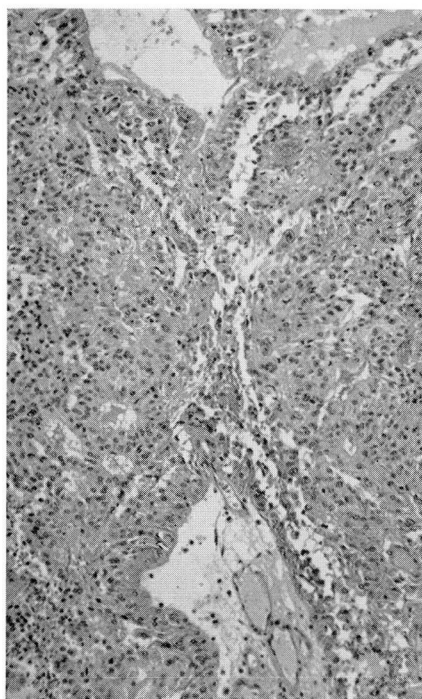
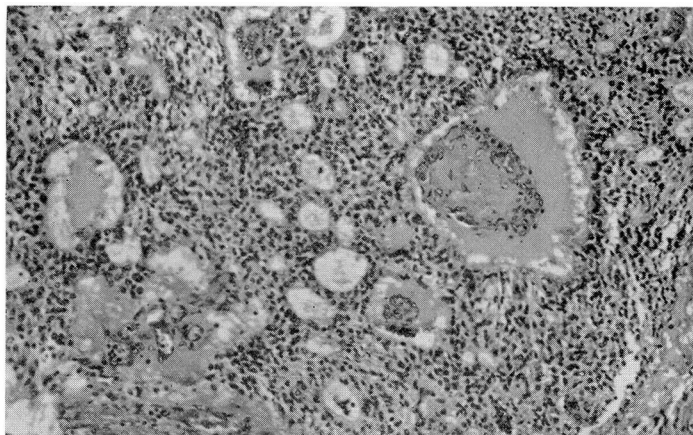
Necrosis. Areas of necrosis were noted in 5 of the 13 neoplasms studied. No relationship between this and other histologic details or survival could be formulated.

Patterns. Papillary, pseudopapillary and cystic patterns were observed. A correlation between these features and other histologic details and survival was nonexistent.

Ependymoblasts and Blepharoplasten. Although phosphotungstic acid hematoxylin stained sections were studied, no cellular inclusions structurally compatible with blepharoplasten were found. A few ependymoblasts were evident in 2 tumors. The duration of the disease prior to surgery was 41 and 30 months. Both patients died during the immediate postoperative period.

Roentgen Therapy. This type of therapy was employed in 4 cases following surgery. The dosage ranged between 3,000 and 5,000 r. Two patients received second courses of irradiation. Three of the group are alive 12, 21½ and 17 months postoperatively. One patient died 19 months after operation. This patient's tumor was in the fourth ventricle and histologically demonstrated uniformity with 3 plus cellularity and no mitoses per twelve high power fields. Of the 3 surviving patients 2 also had tumors in the fourth ventricle. One was of moderate cellularity and demonstrated 14 mitoses per twelve high power fields; two courses of irradiation were given in this instance and the patient is alive 22 months after surgery. The other patient with a lesion of the fourth ventricle has survived 12 months postoperatively. This tumor was judged to

(a)



(b)

(c)

FIG. 2. Interval studies. (a) Tumor from initial operation. Frequent rosettes (x70). (b) Tumor from second operation 10 months later showing reduction in number of rosettes (x70). (c) Tumor from third operation 17 months subsequently; rare rosettes, small cysts, dense collagenous stroma.

be uniform; it had no mitoses, and demonstrated a 1 plus cellularity. The remaining patient who is living 17 months after operation had an ependymoma in the parietofrontal region. This tumor was uniform with 2 plus cellularity and was free of mitotic figures. The group is too small to permit conclusive evaluation; however, the satisfactory response obtained in that lesion with 14 mitoses per twelve high power fields warrants further investigation of the effect of irradiation upon ependymal tumors. Since irradiation was not used in any cases presenting interval specimens, its effect upon the histology of these tumors could not be determined.

Interval Studies (table 3). Neoplasms of 4 patients could be studied at time intervals since they were submitted to two or more operative procedures. In 3 of these instances the tumor was located in accessible and relatively nonobstructing areas of the brain such as the parietofrontal region. It is apparent in table 3 that, in general, there is an increase in mitoses, and decrease in uniformity and number of true rosettes and pseudorosettes (figs. 1 and 2). There was no apparent relationship to the time interval between operations and degree of change. Neither is change consistent among the features of rosettes, pseudorosettes, mitoses and other histologic elements.

Comment

Ependymoma is a rare type of glioma comprising approximately 3.7 per cent of all brain tumors.⁷ These cases represent 2.7 per cent of all gliomas seen at the Cleveland Clinic during the period 1933 to 1948. Furthermore, the sparsity must necessarily emphasize the importance of the individual tumor. This is as significant in the study of biologic phenomena as are larger statistical evaluations. The study of only one small area of tumor may be justifiably criticized; yet, its importance is obvious to the pathologist who may be called upon to offer prognosis as to survival in a case in which only a small portion of tumor is available for study. The presence of mitotic figures in over one-half of all cases in this series is at variance with the concept that ependymomas contain no mitoses.

Although the work of Mabon, Svien, Kernohan and Craig⁴ has offered much in the correlation of histologic features with prognosis, it has been observed in this investigation that the actual grading of these neoplasms is, as in many malignant tumors, exceedingly difficult, especially when correlating classification with survival. This study indicates that the clinical features associated with site of tumor, and the duration of symptoms prior to operation, are of greater importance insofar as survival is concerned than any single histologic feature or group of features. The findings corroborate Bailey's and Cushing's original contention that these tumors are malignant due to site.

Conclusions

1. Thirteen ependymomas were studied from a clinical as well as pathologic standpoint.

2. The grading of these tumors is difficult due to inconsistency among the histologic criteria used in determining the degree of differentiation.

3. The site of tumor, ease of surgical removal, and preoperative duration of symptoms appear to influence survival more than any single histologic feature or group of features.

References

1. Bailey, P.: Tumors arising from ependymal cells. *Arch. Neurol. and Psychiat.* **11**:1 (Jan.) 1924.
2. Bailey, P. and Cushing, H.: *A Classification of the Tumors of the Glioma Group on a Histogenetic Basis with a Correlated Study of Prognosis.* Philadelphia, J. B. Lippincott Company, 1926.
3. Bailey, cited by Davidoff, L.: Brain tumors; their pathology, symptomatology, diagnosis, and prognosis. Reprinted from *Psychiat. Quart.* Vols. 4 and 5, April 1930 to April 1931.
4. Mabon, R. F., Svien, H. J., Kernohan, J. and Craig, W. M.: Ependymomas. *Proc. Staff Meet. Mayo Clin.* **24**:65 (Feb. 2) 1949.
5. Penfield, W.: *Principles of pathology of neurosurgery.* Chapter 6, Reprint No. 15, p. 303, 1932.
6. Kernohan, J. and Fletcher-Kernohan, E.: Ependymomas. *A. Research Nerv. and Ment. Dis. Proc.* **16**:182, 1937.
7. Scheinker, I. M.: *Neurosurgical Pathology.* Springfield, Charles C Thomas, 1948.