

SKELETAL IDENTIFICATION*

DANIEL P. QUIRING, Ph.D.
Department of Anatomy

THE problem of skeletal identification is older than anatomy, anthropology, or medicine. Man's early use of bone marrow for food, his utilization of bones for weapons, and his attempts at surgery offer indirect evidence that his knowledge of the skeletal parts was considerable. In our own American Indian cultures, bone played an important role. Jaw bones of deer were used as scrapers; their vestigial ulnae as well as the long bones of birds were fashioned unto points used for piercing. The preservation of skulls of slain enemies by many primitive people gave the leaders opportunities which they probably did not utilize for contemplation and observation of individual skeletal differences; but certainly they recognized differences between human skulls and others.

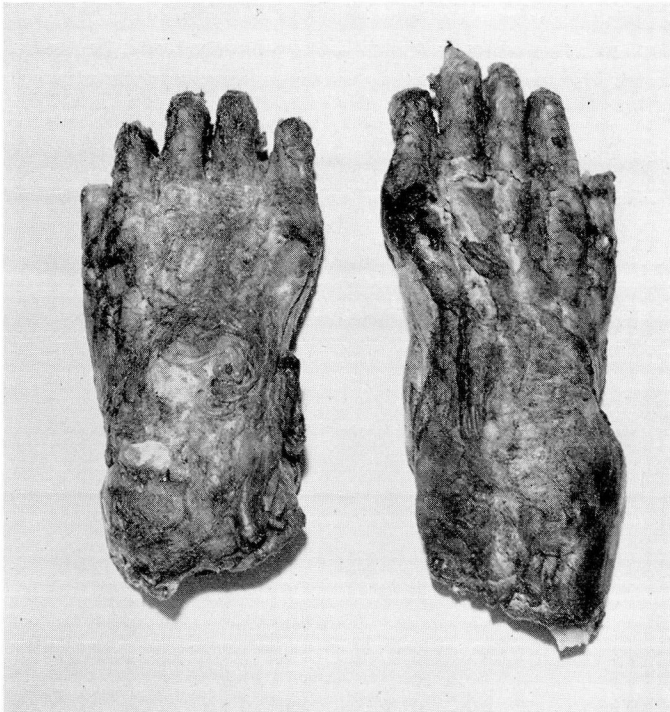

FIG. 1. (a) Dorsal view of bear paws. The terminal phalanges have been removed in skinning. These paws were sent to the coroner's office in the belief that they were human feet.

*Address delivered at the annual convention of the Ohio State Coroners' Association, May 23, 1951.

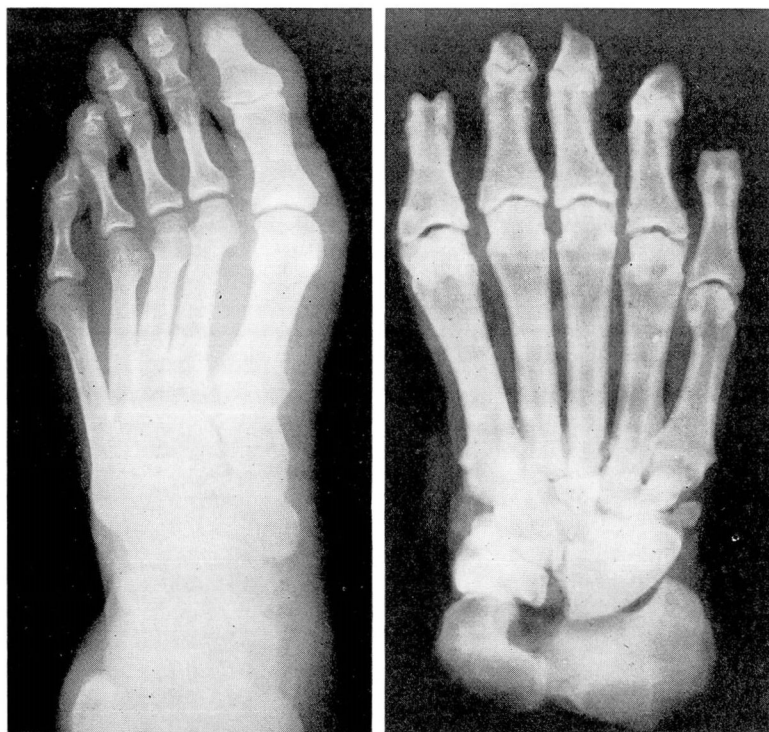


FIG. 1. (b) Radiograph of human foot, left, and bear paw right, both of the left foot (human dorsal view, bear plantar view).

Today the medical profession is called upon frequently to determine the nature of skeletal finds. Frequently animal bones are mistaken for human bones. Dutra,¹ for example, in his excellent article on skeletal identification, points out the close resemblance between a human femur and that of a bear. Recently a pair of bear's paws (fig. 1), found on a Cleveland city dump, were sent to Dr. S. R. Gerber, Cuyahoga County Coroner, for identification in the belief that they were human remains. If the finds prove to be of human origin, further questions as to age, sex, race, stature, and individual peculiarities immediately arise. In the event of murder or violent death suspected in connection with skeletons unearthed by chance from shallow graves, from skeletal fragments found in the ashes of buildings destroyed by fire or explosion, or washed up on beaches, their identification becomes a matter of public concern.

To qualify as an expert on skeletal identification demands a long apprenticeship which the medical practitioner and the coroner are unable to serve unless their primary interests follow these channels. There are a number of criteria developed over the years, chiefly by anatomists and anthropologists, that enable anyone reasonably acquainted with the human framework or its isolated parts or fragments to determine with some degree of accuracy the sex, race, age and stature of the unknown skeleton.

Age

Perhaps the first question in the mind of the examiner of skeletal remains concerns the age of the skeleton. If skull and/or long bones are present, this question may be answered with considerable accuracy. Tooth eruption, epiphyseal union of long bones, fontanel closure and occipital suture closure are the best criteria to determine skeletal age.

The fontanels of the skull are usually six in number. An anterior fontanel lies at the junction of sagittal and coronal sutures, an occipital or posterior at the junction of sagittal and lambdoid sutures, a lateral at the sphenoid-parietal junction, and a posterior lateral or mastoid fontanel at the masto-occipital junction. The last two are paired. The two lateral and the occipital fontanels are closed shortly after birth, usually within the first 2 months; the frontal or anterior closes about the middle of the second year. The condition of these fontanels, together with the extent of eruption of the deciduous dentition, permits fairly accurate assessment of age within the first 2 years of life.

The status of the permanent dentition together with the degree of fusion of the occipital elements comprise the safest criteria to follow for age evaluation between the fifth and the seventeenth year (table 1).

The occipital bone consists of a squamous, two lateral and a basilar part and the difference in time of its various suture fusions yields valuable information regarding skeletal age. The squamous and lateral parts unite at from 4 to 5 years. Between the sixth and seventh year the basilar and the lateral parts join. The basilar part does not fuse with the sphenoid bone until the twenty-second to twenty-fifth years.

Thus if the squama and lateral parts of the occipital are united, and the first permanent molars are beginning to erupt in a skull under examination, the skeleton would be between 5 and 6 years' old.

The interval between 17 and 25 can be determined rather accurately by noting the relationship between the eruption of the third permanent molars and the degree of fusion between basioccipital and sphenoid bones. If the third molar has erupted and the occipitosphenoid suture is open, the skull is over 17 and undoubtedly under 22. If, with the eruption of the third molar, the occipitosphenoid union is almost completed the age is probably near 25 years.

Beginning about the fifteenth year, epiphyseal union of the long bones proceeds in somewhat orderly fashion. Table 2, based on the study of Stevenson,⁶ is a reliable guide for assessment of age between 15 and 30 years.

Time of cranial suture closure, aside from the occipital sutures already mentioned, is another approach to the problem of age assessment. Todd and Lyons,⁷ on the basis of many observations, have set up a tabulation which is of some value in age assessment (table 3). Perhaps the greatest single fact that emerges from their work is the evidence of delay of initiation of mastoid and temporal and sphenoid closures in comparison with sagittal and coronal fusions. Associated with this finding is a further fact of practical value: the mastoid, temporal and sphenoid sutures are not completed until late in life,

Table 1

TABLE OF TOOTH ERUPTION (After Gray)

Milk dentition	
Lower central incisors	6 to 9 months
Upper incisors	8 to 10 months
Lower lateral incisors and first molars	15 to 21 months
Canines	16 to 20 months
Second molars	20 to 24 months
Permanent dentition	
First molars	6th year
Two central incisors	7th year
Two lateral incisors	8th year
First premolars	9th year
Second premolars	10th year
Canines	11th to 12th year
Second molars	12th to 13th year
Third molars	17th to 25th year

Table 2

AGE ORDER OF EPIPHYSEAL UNION IN MAN

Order	Begins (Year)	Completed (Year)
1. Distal extremity of humerus	15 (?)	Before 17
a. Medial epicondyle	16 (?)	Before 17
2. Coracoid process of scapula	15	Before 16
3. Three elements of innominate	15 (?)	Before 17
4. Head of radius	Beginning of 18	End of 18
a. Olecranon of ulna	16 (?)	17
5. Head of femur	Beginning of 18	18
a. Lesser and greater trochanter	Lesser slightly earlier, greater same as head	18
6. Tuberosities of ribs	18 (very unreliable)	22
7. Distal extremities of tibia and fibula	18	End of 18
8. Proximal extremity of tibia	Beginning 18	Beginning 20
a. Proximal extremity of fibula	Beginning 18	Beginning 20
9. Distal extremity of femur	Beginning 19	Beginning 20 (or earlier)
10. Tuberosity of ischium	Beginning 18	Beginning 19
11. Distal extremities of radius and ulna	Beginning 19	19
12. Head of humerus	19	20
13. Crest of ilium	19	21
14. Heads of ribs	20 (very unreliable)	22
15. Ramal epiphysis of pelvis	19	22
16. Clavicle	22 (?)	28

Table 3
CRANIAL SUTURE CLOSURE (From Todd and Lyons)

Suture	Begins (Year)	Termination or Peak (Year)
Sagittal		
pars obelica	20	29 to 3.9*
pars lambdica	21	29 to 2.4
pars verticis	21	29 to 2.7
pars bregmatica	26	29 to 2.9
Coronal		
pars bregmatica	26	29
pars complicata	26	29
pars pterica	22	50 to 3.8
Lambdoid		
pars lambdica	21 to 26	30 to 2.3
pars media	21 to 26	30 to 1.9
pars asterica	26	30 to 0.6
Masto-occipital		
pars superior	28	old age
pars media	28	old age to 3.5
pars inferior	26	62 to 3.6
sphenotemporal	36 to 37	65
squamous	38	65
Parietomastoid	39	64
Sphenoparietal	28	
Sphenofrontal		
pars temporalis	28	65 to 4.0
pars orbitalis	28	46 to 3.8

*Todd and Lyons set up a scale ranging from 1 to 4 to denote the degree of fusion. Thus 1 indicates the initiation and 4 the completion of fusion.

Table 4
PELVIC DIMENSIONS*

False Pelvis	Male (mm)			Female (mm)		
Greatest distance between crests of ilia (externally)	287			279		
Distance between anterior superior spines of ilia	241			233		
Distance between front of symphysis pubis and first sacral spine	183			178		
True Pelvis	Inlet	Cavity	Outlet	Inlet	Cavity	Outlet
Transverse diameter	127	119	89	132	127	119
Oblique diameter	119	114	102	127	132	89
Anteroposterior diameter	102	107	79	114	127	114

*Modified from Quain, ed. 10.

while sagittal, coronal and lambdoid are, with one exception (*pars pterica*), virtually completed by 30 years of age.

If all sutures save those associated with the mastoid bone are well on the way to fusion in a given skull, it is most likely under 30 years old. If the squamous portion of the temporoparietal suture is partly fused, the skull is likely between 45 to 55 years old. If that suture is obliterated, the skull is probably over 65.

Sex

Certain sexual skeletal characteristics facilitate the determination of the sex if the skeleton is of normal pattern or if it is complete. If one deals with fragments or with an atypical skeleton, e.g., the skeleton of a large muscular female of robust type, identification becomes more difficult.

The pubic angle is over 70 degrees and rounded in the female, and less than 70 degrees and more angular in the male. This is probably the best single criterion. Table 4 shows other sexual differences both in the true and in the false pelvis. If the pelvis is fractured, the sex may easily be confused. For example, in the great Ohio gas explosion three of us identified a charred torso, minus head, legs, and arms as that of a male on the basis of the x-ray plates of the fractured pelvis. Dissection of the few remaining fragments of charred internal organs indicated the remains to be those of a female.

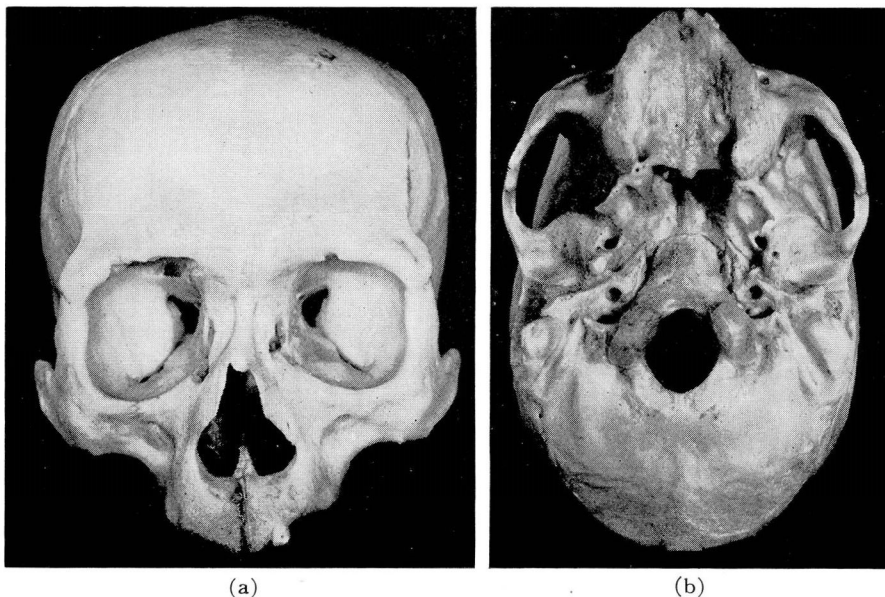
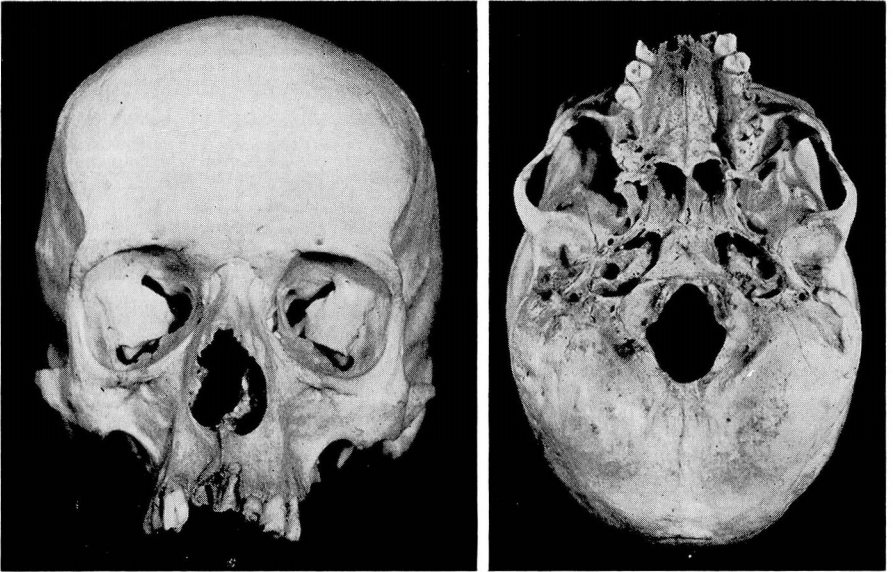


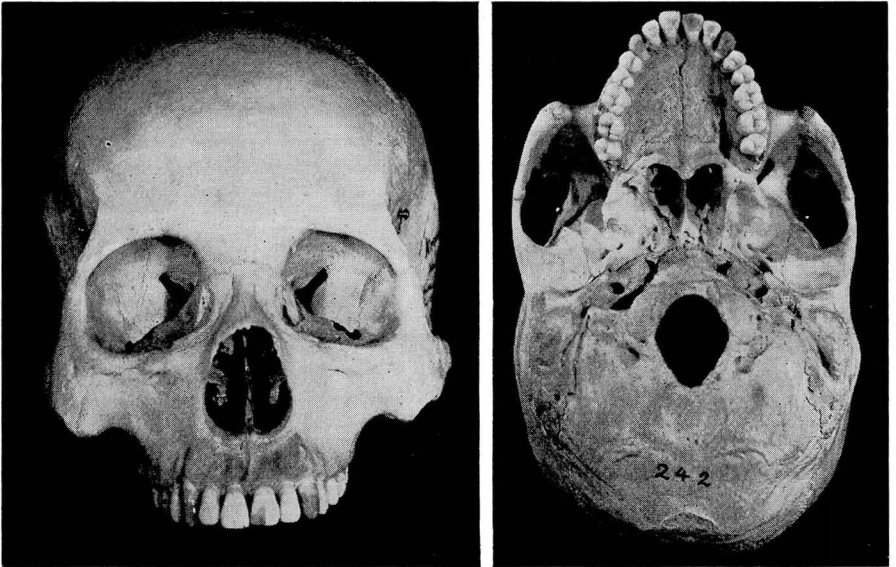
FIG. 2. Negro Skull. (a) Note particularly wide nasal aperture with dull lower margin, deep canine fossae, large orbits, long fused nasal suture, relatively narrow forehead, flat temporal region. (b) Compare long hard palate and narrow dental arch with that of the Mongoloid (fig. 4)



(a)

(b)

FIG. 3. White Skull. (a) Observe sharp lower margin of nasal aperture, deep canine fossae, relatively small orbits, tendency toward streamlining of malar bones. (b) Narrow hard palate and narrow dental arch resembling that of the Negro.



(a)

(b)

FIG. 4. Mongoloid Skull (North Korean). (a) Shows angularity and prominence of malar bones, absence of pronounced canine fossae, angularity of orbits, wide nasal aperture with tendency toward dull lower margin resembling that of the Negro. Shovel-shaped incisors. (b) Short wide hard palate and accentuated arching of dental arcade.

In general female bones are more delicate, the bony markings for muscular attachments less pronounced than those of the male. The articular heads also are relatively smaller. The pelvic outlet in the female is less constricted than in the male. The lower part of the sacrum is bent backward. It is shorter and broader, while the greater sciatic notch is wider and more shallow than in the male. The margins of the pubic bones are inclined outward in the female and the iliac margins do not flare as greatly as in the male.

The cranium is smaller, less rugged, more delicate than in the male. All markings for muscle attachments (temporal lines, nuchal lines, mastoid processes, styloid processes) are less pronounced in the female than in the male. The forehead is more bulbous, the eyebrow ridges are less pronounced, the malar bones are less rugged, the hard palate and the teeth are smaller, and the lower jaw is smaller and has a lesser chin projection than in the male.

Race

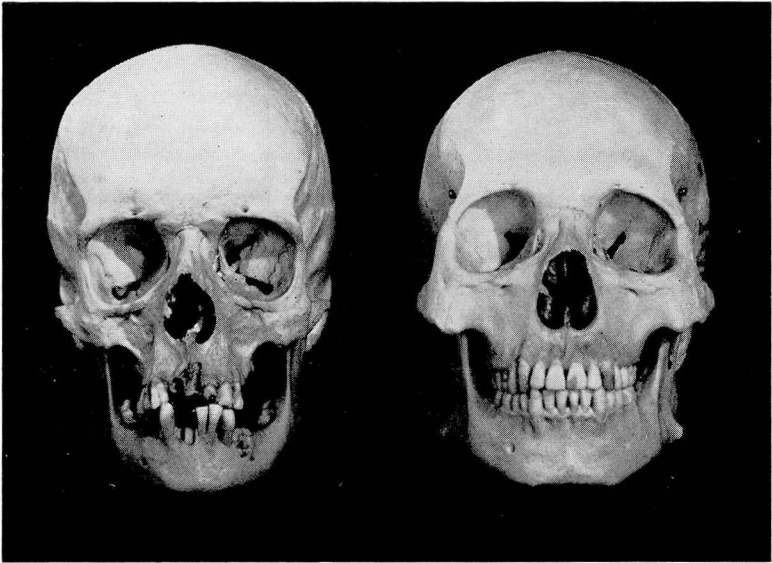
It is of great importance in the evaluation of skeletal data to know the race of the skeleton. In connection with this problem one difficulty results from the fact that we are frequently confronted with racial mixtures of varying degree. Each of the major races, i. e., the White, Negro, and Mongoloid is marked skeletally by certain well-defined features that become greatly moderated in instances of racial admixtures.

Outstanding Cranial and Postcranial Features of the Negro Skeleton

(Figs. 2, 6, 7)

Cranial

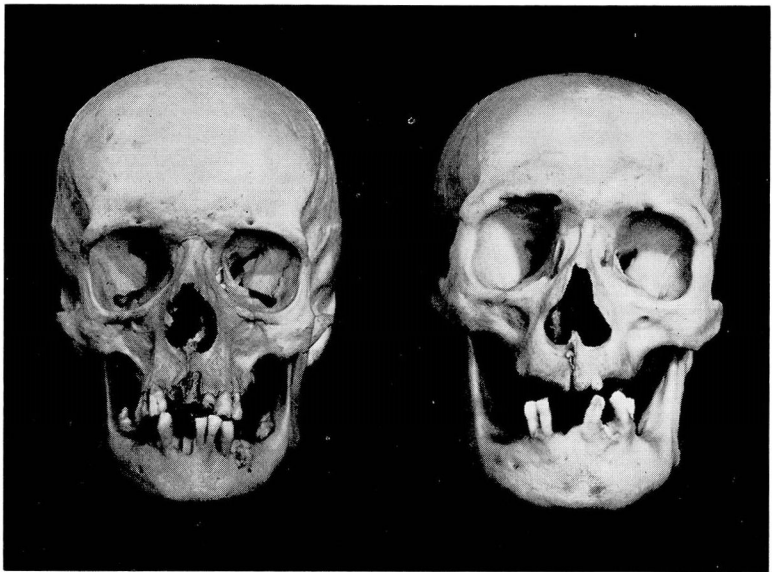- Wide nasal aperture, dull lower margin.
- Rudimentary nasal spine.
- Deep canine fossa.
- Prognathism frequently pronounced.
- Close dense texture of relatively fresh skull.
- Chin may be poorly developed.
- Jaws may bulge subnasally.
- Broad nasal bridge.
- Long nasal suture often fused in adult skull.
- Palate and dental arches long and narrow.
- Teeth exceed those of a white skeleton in size.
- Impacted third molars rare.
- Orbit low but not tilted down or out.
- Glabella not protrusive.
- Forehead symmetrically rounded side to side and from front to back, inclines to narrowness.
- Female forehead often bulbous.
- Temporal region flat.



(a)

(b)

FIG. 5. (a) White skull. (b) Mongoloid with complete dentition.



(a)

(b)

FIG. 6. (a) White skull. (b) Negro skull.

Crania generally long headed.
 Cranial constriction just behind coronal suture.
 Occipit protuberant.
 Attachments for neck muscles and ligaments ordinarily not strongly marked.
 Cranial sutures less serrated than in whites.
 Molars sloping as in whites.
 Canine fossa pronounced.
 Malar bone streamlined.

Postcranial

Bones slender, articular heads small.
 Pelvis narrow and high.
 Bones of forearm and leg long relative to upper segments of respective limbs.

The greatest single characterizing feature is probably the dull lower margin of the nasal aperture which stands in great contrast to the sharp-edged margin in the white skull—the nasal spine too is well defined in the white skull and relatively shorter in the Negro.

Outstanding Cranial and Postcranial Features of the White Skeleton

(Figs. 3, 5, 6, 7)

Cranial

Small jaws, pinched palates.
 High narrow nasal bones.
 Lower and upper nasal border sharp.
 Prominent nasal spine.
 Chin eminence more pronounced than in non-whites.
 Depression of nasofrontal suture.
 Brow ridges prominent in male, more developed laterally.
 Receding forehead more common in male whites than in Negro.
 Tortuous cranial sutures.
 Mastoid and styloid processes larger than in Negro.
 External occipital protuberance, conical or hooked.
 Straight orthognathous face, devoid of prognathism.
 Deep canine fossa.
 Malar bone moderately streamlined.

Postcranial

Bones thicker, more massive than Negro.
 Joints larger than Negro.
 Pelves wider and more rugged than in Negro skeleton.
 Muscular skull markings prominent.

Outstanding Cranial and Postcranial Features of the Mongoloid Skeleton

(Fig. 4, 5, 8)

Mongoloid skeletal features vary greatly within the race.

The features are more rugged and primitive in appearance in Eskimo and certain Siberian tribes than in Japanese, Korean, Chinese and certain Amerindian skeletons. The following characteristics appear quite general:

Cranial

Outstanding feature is the angularity and prominence of malar bone. Body of malar deeper and more massive than in non-Mongoloid, produces flat appearance of Mongol skull.

Canine fossa disappears.

Slight or no nasofrontal suture depression.

Root of nose broad and flat.

Middle pillar (nasal) wide.

Top of nasal bones narrow, flare out distally.

Below nasion nasal root is depressed.

Borders of nasal aperture dull, spine small.

Some alveolar prognathism.

Palate and dental arcades short and wide.

Shovel-shaped incisors.

Glenoid fossa more shallow than in Negro or white.

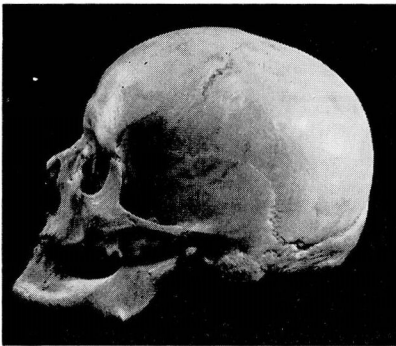
Brow ridges not prominent.

Forehead moderately high.

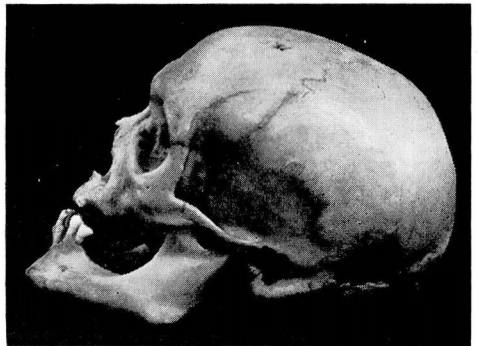
Ridge pole like elevation of sagittal suture.

Skull sutures simple.

Temporal region not building.



(a)



(b)

FIG. 7. (a) Lateral view of white skull with somewhat bulging temporal bone. (b) Negro skull with flattened temporal bone. The canine fossa is deep in both races.

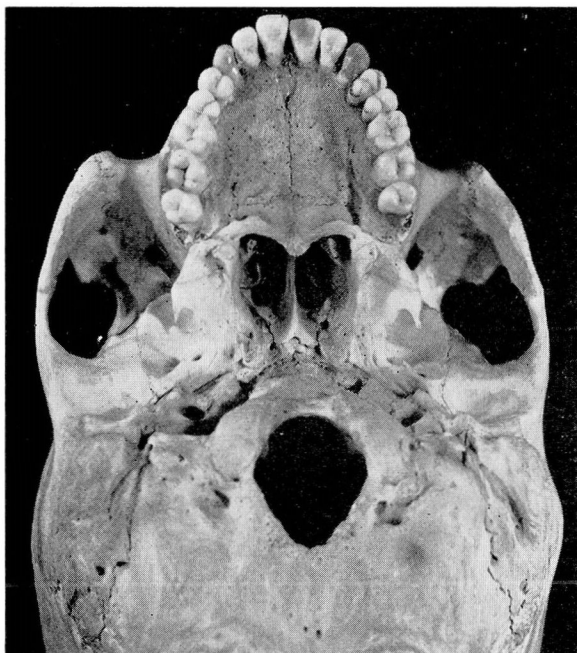


FIG. 8. Base of Mongoloid skull. Note open temporal-occipital sutures which close normally between 55 and 62; open basioccipital-sphenoid suture that closes normally at 25; short wide palate and horseshoe shaped dental arch, and pronounced angularity of malar bones.

Postcranial

Articulations are smaller, long bones more slender than whites except in primitive Eskimo types.

The question of the value of determining long-headedness or round-headedness is frequently raised. The Negro, the Mongoloid, the Mediterranean and Nordic white generally run to long-headedness; the Alpine European is more commonly round-headed. The Armenianoid types have peaked heads as do the Dinaric from Southeastern Europe.

The American types commonly represent mixtures. The ancient pure Negro types also are tempered by interbreeding. Anglo-Saxon, Mediterranean and Alpine mixtures produce skeletal results difficult to translate in many skulls. Table 5 (from Dutra) shows the differences in the measurements of skulls of various races.

The studies of Karl Pearson⁴ which led to a series of formulas for determination of stature from dried bones deserves prominent mention in any study directed to skeletal identification (table 6). He was the first to develop (1899) reliable formulas for such determinations from individual bones or from com-

Table 5
RACIAL DIFFERENCES IN SKULLS

Character	Caucasoid			Mongoloid	Negroid
	North European	Central European	South European		
Skull length (center of forehead to occiput)					
Male	183-192*	Below 175	183-192	Below 175	183-192
Female	175-184	Below 167	175-184	Below 167	175-184
Skull breadth (maximum breadth between parietal bones)					
Male	132-142	Above 151	132-142	Above 151	132-142
Female	126-136	Above 145	126-136	Above 145	126-136
Skull height (anterior margin of foramen magnum to junction of sagittal and coronal sutures)					
Male	Above 138	Above 138	Approx. 138	128-138	Below 128
Female	Above 131	Above 131	Approx. 131	121-131	Below 121
Face height (upper) (tip of upper jaw, excluding teeth, to suture between nasal and frontal bones)					
Male	75-80	75-80	Approx. 75	75-80	Below 69
Female	70-75	70-75	Approx. 70	70-75	Below 64
Face breadth (maximum breadth between cheek bones)					
Male	Below 128	136-144	Below 128	Above 144	Below 128
Female	Below 118	126-134	Below 118	Above 134	Below 118
Cranial index					
Breadth of skull	Below 75	Above 80	Below 75	Above 80	Below 75
Length of skull					
Index of height					
Height of skull	Above 75	Above 75	Approx. 75	70-75	Below 70
Length of skull					
Nasal index					
Nasal breadth	Below 47	51-53	Below 47	Below 47	Above 51
Nasal height					

*All measurements are expressed in millimeters.

binations of bones although Manouvrier (1892) and Rollet (1889), earlier, had laid the foundations for such studies. I have found the formulas highly accurate when applied to material available to me. Ordinarily variations between the theoretical values and the actually established values are less than 2.5 cm.

The lengths are measured in centimeters. In the case of the femur the maximum length from head to distal end is taken. If the oblique length is used, add 0.32 to the femur length if from a male or 0.33 from a female, before applying the equation. In measuring the length of the tibia, the length to the distal articulating surface is taken, and not to the tip of the styloid process. The values in centimeters (found by direct measurement of the bones in question) are multiplied by the adjacent constants and the result added to the first constant in the formula; this gives stature in centimeters. The formulas have been determined from right members. According to Pearson⁴ a slight error of the second order may arise when the left member is used. Use of formulas e, f, and i show the lowest factor of error.

With the indicated tools whose value has been determined by long experience, one should not err too greatly in skeletal identification. But with all these criteria—suture closing, racial characteristics, formulas for determining stature—it is still an easy matter to make wrong evaluations. I have, for example, in my collection a white skull presumably about 25 years of age, if the status of the cranial sutures were authentic. This skull is edentulous, the frontal, parietal,

Table 6

STATURE RECONSTRUCTION FORMULAS

Male Stature

- a. $S = 81.306 + 1.880 \text{ femur}$
- b. $S = 70.641 + 2.894 \text{ humerus}$
- c. $S = 78.664 + 2.376 \text{ tibia}$
- d. $S = 85.925 + 3.271 \text{ radius}$
- e. $S = 71.272 + 1.159 \text{ (femur + tibia)}$
- f. $S = 71.443 + 1.220 \text{ femur} + 1.080 \text{ tibia}$
- g. $S = 66.855 + 1.730 \text{ (humerus + radius)}$
- h. $S = 69.788 + 2.769 \text{ humerus} + 0.195 \text{ radius}$
- i. $S = 68.397 + 1.030 \text{ femur} + 1.557 \text{ humerus}$
- k. $S = 67.049 + 0.913 \text{ femur} + 0.600 \text{ tibia} + 1.225 \text{ humerus} - 0.187 \text{ radius}$

Female Stature

- a. $S = 72.884 + 1.945 \text{ femur}$
- b. $S = 71.475 + 2.754 \text{ humerus}$
- c. $S = 74.774 + 2.352 \text{ tibia}$
- d. $S = 81.224 + 3.343 \text{ radius}$
- e. $S = 69.154 + 1.126 \text{ (femur + tibia)}$
- f. $S = 69.561 + 1.117 \text{ femur} + 1.125 \text{ tibia}$
- g. $S = 70.542 + 2.582 \text{ humerus} + 0.281 \text{ radius}$
- h. $S = 67.435 + 1.339 \text{ femur} + 1.027 \text{ humerus}$
- i. $S = 67.469 + 0.782 \text{ femur} + 1.120 \text{ tibia} + 1.059 \text{ humerus} - 0.711 \text{ radius}$

occipitoparietal sutures are open. Everything indicates that the skull is about 20 to 25 years old, save that the individual was approximately 56 years old at the time of death.

Generally stature, body types and race may be determined with considerable accuracy. This knowledge supplements, in criminal or anthropologic investigation, the findings and speculations obtained from other avenues of approach.

References

1. Dutra, F. R.: Identification of person and determination of cause of death from skeletal remains. *Arch. Path.* **38**:339, 1944.
2. Hooton, E. A.: *Up from the Ape*. New York, The Macmillan Company, 1946.
3. Manouvrier, M.: *Memoires de la Societe d'Anthropologie de Paris*. **4**:384, 1892.
4. Pearson, K.: *Philosophical Transactions of the Royal Society*. **192**:169, 1899.
5. Rollet, E.: *De la Mensuration des Os Longs des Membres—Lyons*, 1889.
6. Stevenson, P. H.: Age order of epiphyseal union in man. *Am. J. Phys. Anthropol.* **7**:53, 1924.
7. Todd, W. T. and Lyons, D. W.: Ectocranial closure in adult males of white stock. *Am. J. Phys. Anthropol.* **8**:23-46, 47-71, 149, 168, and **7**:325-384, 1925.