

## THE LATERAL DECUBITUS POSITION IN CHOLECYSTOGRAPHY

WYLIE H. MULLEN, Jr., M.D.\* and LOUIS J. MAKIELSKI, M.D.\*\*  
Department of Roentgenology

THE value of the lateral decubitus position during cholecystography has been long established. Its use as a routine procedure is recommended and can be accomplished with little additional effort, resulting in greater diagnostic accuracy.

For this view the patient is positioned on a mobile table, with his right side directly over a well in the table top. A horizontal x-ray beam is employed, traversing the gallbladder area in a posteroanterior direction. An upright Bucky holds the cassette in a position against the patient's right upper abdomen (fig. 1).

In our routine cholecystographic examination at the Cleveland Clinic, each patient has a posteroanterior lateral decubitus film and an ordinary posteroanterior prone film. These are developed and the wet films studied. If these two films are diagnostic, no other films are exposed. If, in the opinion of the roentgenologist, these two films do not constitute a diagnostic examination, fat meal, pitressin, or a second dose of dye are given, or oblique and up-

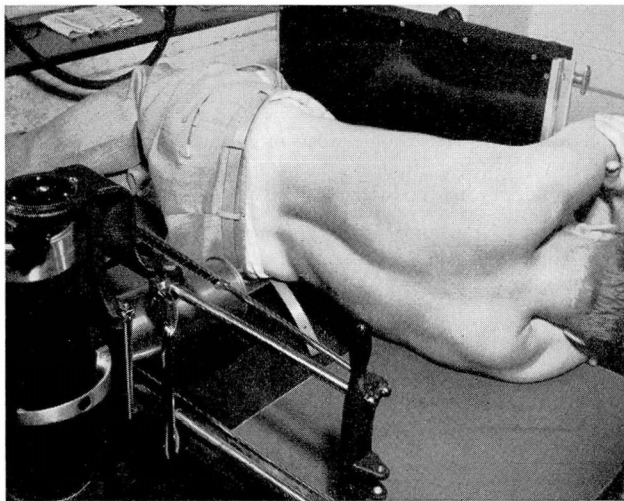


FIG. 1. Table used for lateral decubitus roentgenograms of the gallbladder. Note the well in table top which offers no obstruction to x-ray beam and which permits the patient's right flank to drop down slightly decreasing his anteroposterior diameter.

\*Formerly on the Assistant Staff. Now practicing in Joliet, Ill.

\*\*Former Fellow. Now located in Kingsport, Tenn.

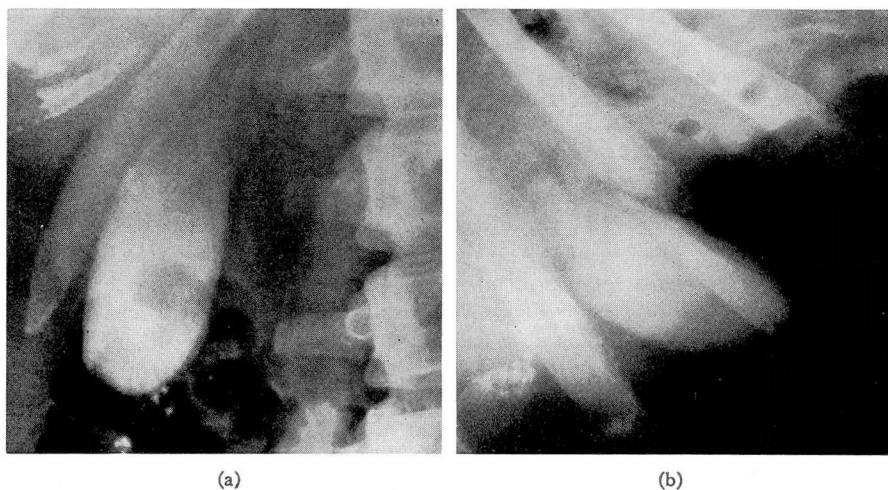


FIG. 2. Normal gallbladder. (a) Posteroanterior prone roentgenogram showing fundus of the gallbladder obscured by gas and fecal shadows in hepatic flexure of the colon. (b) Posteroanterior lateral decubitus roentgenogram revealing that gallbladder has dropped toward the right and now lies unobscured by gas.

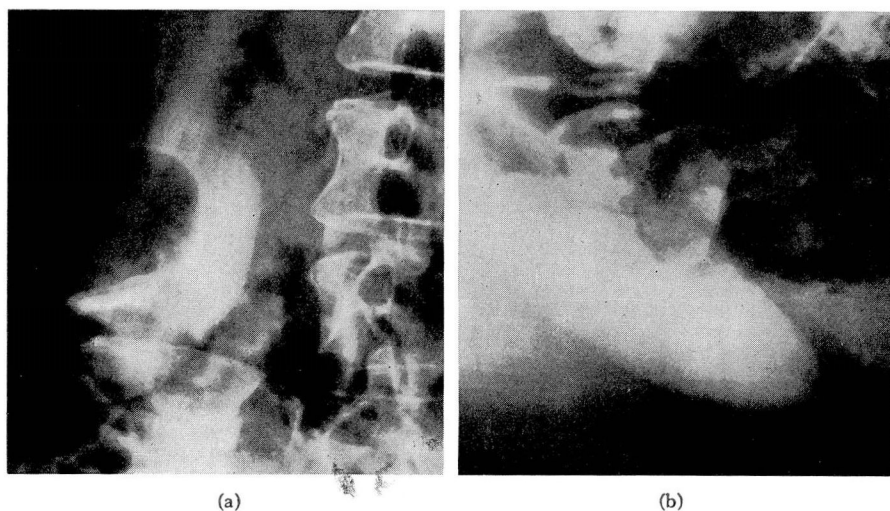


FIG. 3. Normal gallbladder. (a) Posteroanterior prone roentgenogram with gallbladder obscured by intestinal gas, fecal matter, and the right iliac crest. (b) Posteroanterior lateral decubitus roentgenogram showing a normal gallbladder lying unobscured in right flank.

right films may be taken. By following this procedure, less than 20 per cent of the patients need more than the two original films.

One of the main objections to routine prone views of the gallbladder is the great frequency with which the gallbladder shadow will be obscured by gas or fecal shadows present in the hepatic flexure of the colon, duodenal bulb or small intestine. These may be identified incorrectly as calculi or may obscure the presence of calculi in the portion of the gallbladder over which they are superimposed. Half cubic centimeter doses of pitressen will, in most instances, remove this obscuring gas and fecal matter; however its administration and subsequent repetition of the films are time consuming. More important, it is well known that pitressen is a dangerous drug and should not be prescribed to elderly patients suffering from hypertension or other types of cardiovascular disease. Compliance with these contraindications withholds the use of this drug from a large group of ill and elderly patients who have the greatest tendency toward gas accumulation. It is especially in this latter group that the lateral decubitus position is of great value. The gallbladder, if mobile, drops toward the right flank while the gas-filled bowel tends to float upward to the left giving an unobscured gallbladder shadow. Since the institution of the lateral decubitus film as part of our routine gallbladder examination, the administration of pitressen has been limited to an occasional young patient with obscuring gas present on both routine views. Formerly, pitressen was considered necessary in as many as 10 to 20 patients daily. The ability to obtain a gallbladder shadow free from obscuring gas on the decubitus film is demonstrated clearly in figures 2, 3 and 4.

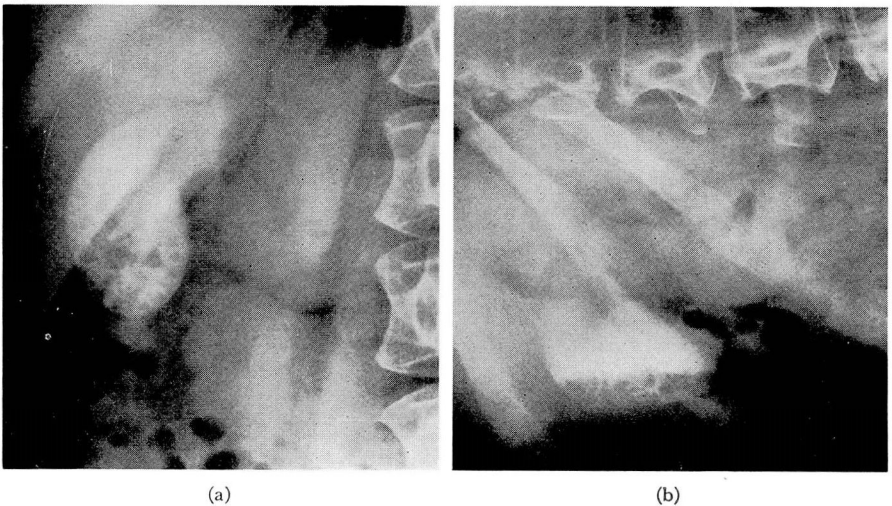


FIG. 4. Cholelithiasis. (a) Posteroanterior prone roentgenogram showing multiple nonopaque calculi. (b) Posteroanterior lateral decubitus roentgenogram where calculi have settled to bottom of the gallbladder silhouette. Note increased contrast between calculi and dye-containing bile above.

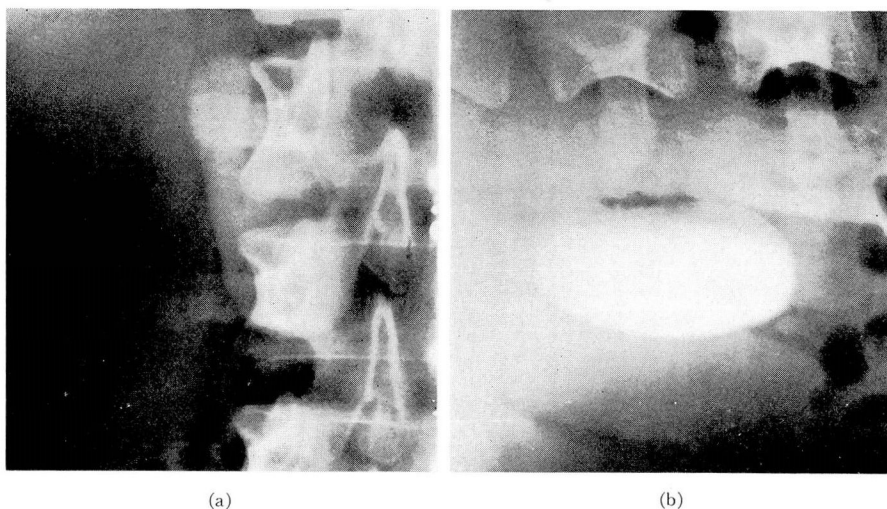


FIG. 5. Normal gallbladder. (a) Posteroanterior prone roentgenogram with gallbladder overlying the spine. (b) Posteroanterior lateral decubitus roentgenogram showing a normal unobscured gallbladder shadow down and to the right of spine. Note layer of bile of lighter specific gravity and less dye-density at top of the gallbladder shadow.

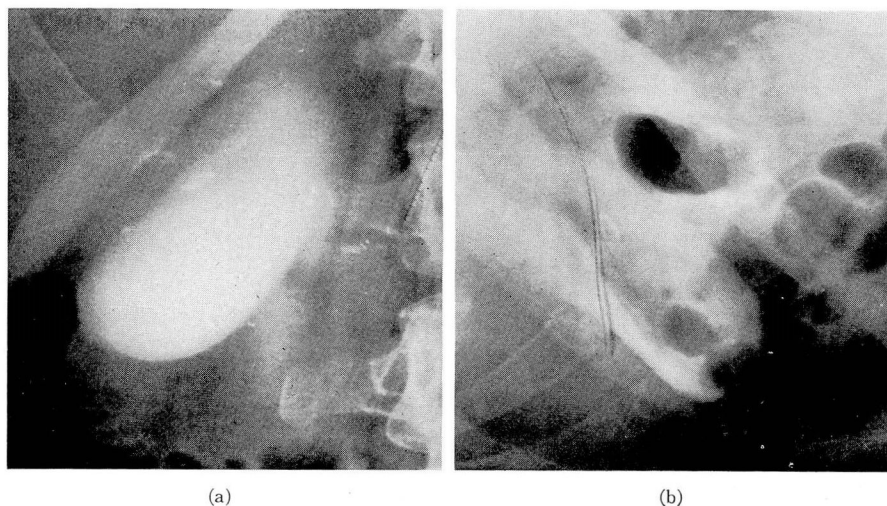
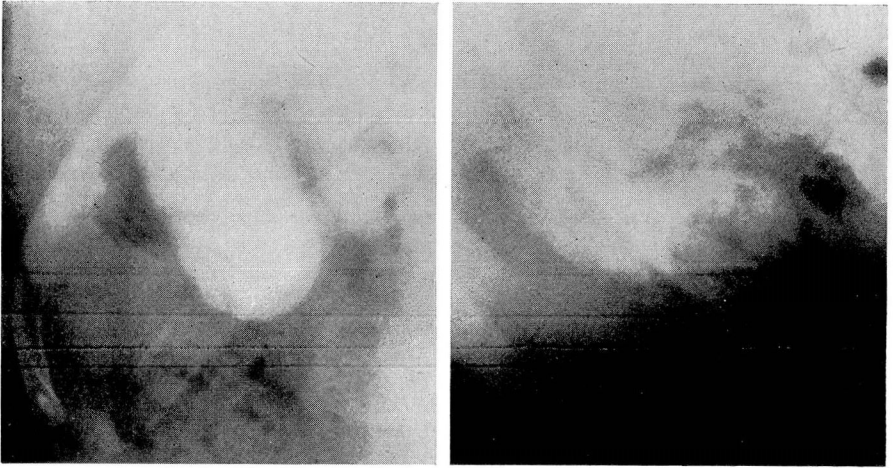


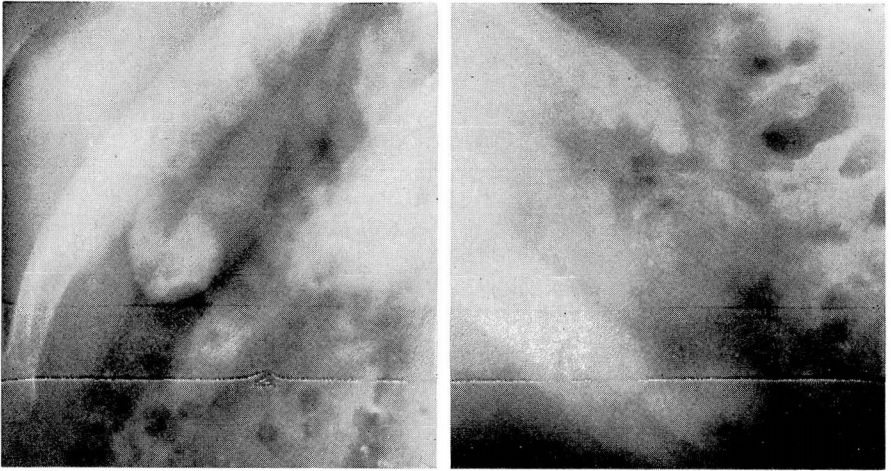
FIG. 6. Normal gallbladder. (a) Posteroanterior prone roentgenogram; normal gallbladder unobscured. (b) Posteroanterior lateral decubitus roentgenogram where obscuring colon gas has shifted over gallbladder.



(a)

(b)

FIG. 7. Cholelithiasis. (a) Posteroanterior prone roentgenogram. Although calculi are present they cannot be distinguished from the superimposed gas shadows. (b) Posteroanterior lateral decubitus roentgenogram showing multiple small nonopaque calculi which have settled to bottom of gallbladder silhouette and stand out in sharp contrast to surrounding bile above although the obscuring gas still lies over gallbladder.



(a)

(b)

FIG. 8. Cholelithiasis. (a) Posteroanterior prone roentgenogram showing four nonopaque calculi simulating small gas bubbles. (b) Posteroanterior lateral decubitus roentgenogram where stones have settled to the bottom of gallbladder shadow.

In the occasional patient in whom the gallbladder normally overlies the spine on the routine posteroanterior prone view, the lateral decubitus film will show it to have fallen away from the spine and to be lying in an area unobscured by bony structures (fig. 5). In rare instances, the lateral decubitus film may show more obscuring shadows than the prone film but this occurs infrequently (fig. 6).

The various physiologic and pathologic contents of the gallbladder always occupy a level dependent on their relative specific gravities. On lateral decubitus or upright films, these contents are viewed in profile. Calculi, usually being the heaviest, often settle to the bottom of the gallbladder silhouette on these views (figs. 4, 7, 8 and 9). If concentrated bile is present the calculi may not settle to the bottom but instead may layer in a level of bile of the same specific gravity (fig. 10). Gallbladders free of calculi may demonstrate a normal layering of bile of various specific gravities (figs. 5 and 11).

If the gallbladder concentrates the dye well, small calculi may not be detected through the density of the gallbladder shadow on prone films. If, however, they settle on the lateral decubitus film they may be detected because they now occupy a peripheral portion of the shadow where the dye is less dense and where their shadow will be more apparent because the roentgen beam is passing through several of the stones layered into a thin but broad area (figs. 4, 7 and 9).

Solitary or multiple papillomata are easily mistaken for calculi on posteroanterior prone films; however, if lateral decubitus or upright films are made, these shadows maintain a constant position in relationship to the gallbladder shadow and fail to settle or layer in spite of the patient's position. This will often make their correct identification possible (fig. 12).

The upright film with the patient erect and employing a horizontal beam will, like the lateral decubitus position, demonstrate settling and layering of calculi, show the failure of papilloma shadows to change position, and will on occasion free the gallbladder shadow of obscuring gas. As a routine procedure, we have not found this position as valuable as the lateral decubitus since the gallbladder will drop into the lower abdomen, often to be obscured by other gas shadows or, in elderly people, by the osseous structures of the pelvis. In addition, when the patient is erect, the lower abdomen is slightly thicker and more surrounding tissue must be penetrated by the exposing roentgen beam, lessening detail and contrast. In the lateral decubitus position, the gallbladder falls into the flank area where the patient's anteroposterior diameter is actually less and contrast and detail are resultingly enhanced.

The routine use of the lateral decubitus position is recommended. The decreased need for pitressin and fat meals, the confirmation of cholelithiasis where evidence is only suspected on prone films, the correct identification of a papilloma or of calculi not indicated on prone films, and the actual saving of film and time will more than repay the user for its institution.

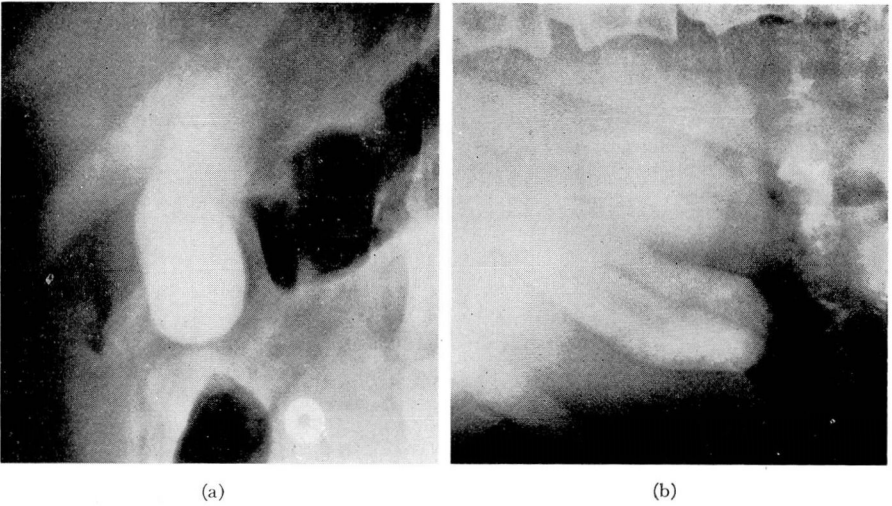


FIG. 9. Cholelithiasis. (a) Posteroanterior prone roentgenogram showing what appears to be a normal gallbladder free of calculi. (b) Posteroanterior lateral decubitus roentgenogram revealing that a few nonopaque calculi have settled to the bottom.

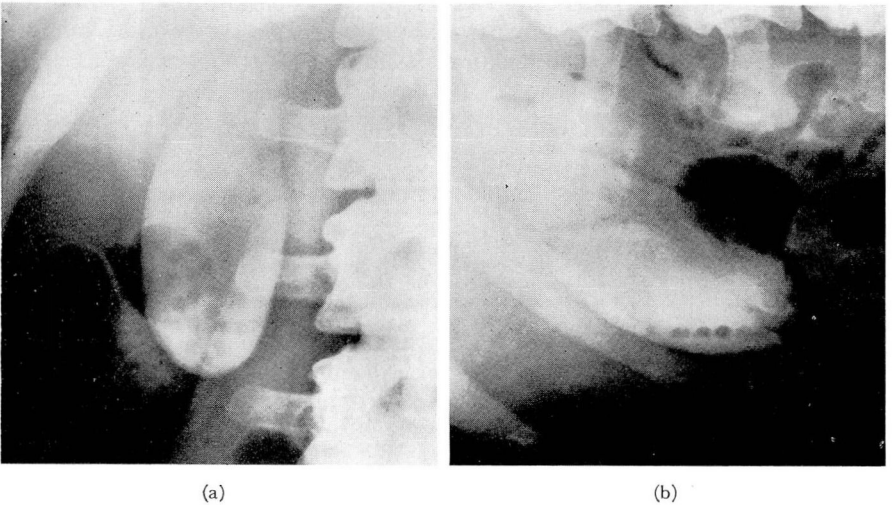


FIG. 10. Cholelithiasis. (a) Posteroanterior prone roentgenogram showing several obvious nonopaque calculi. (b) Posteroanterior lateral decubitus roentgenogram where "layering" of calculi is demonstrated.

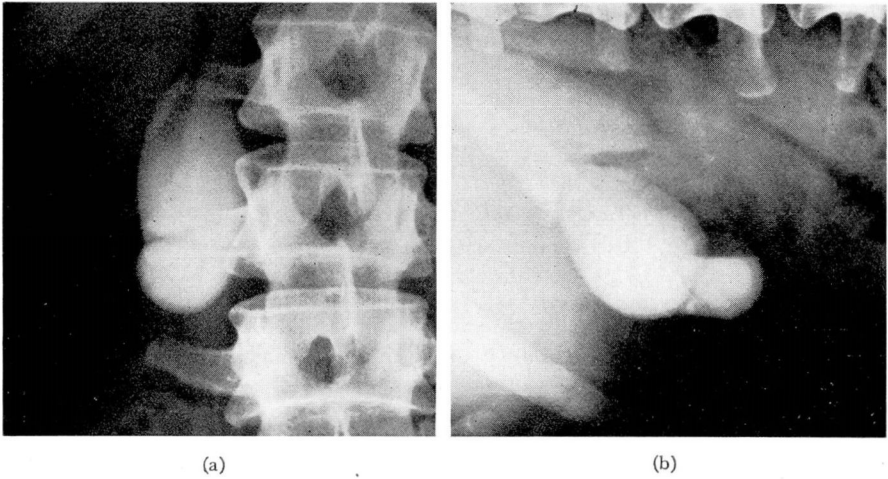


FIG. 11. Normal gallbladder. (a) Posteroanterior prone roentgenogram showing normal gallbladder. (b) Posteroanterior lateral decubitus roentgenogram where a layer of bile with low specific gravity and only slight dye-density is trapped in the top of a Phrygian cap.

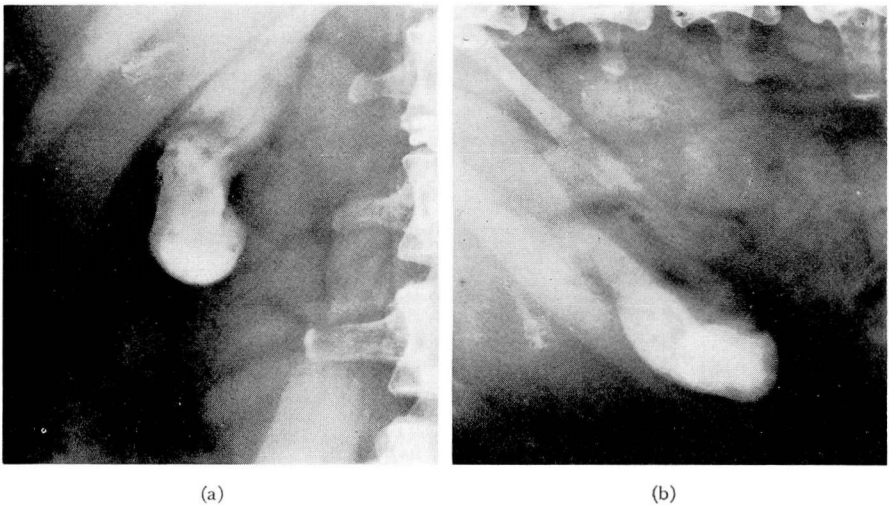


FIG. 12. Multiple papillomata. (a) Posteroanterior prone roentgenogram showing multiple nonopaque shadows. (b) Posteroanterior lateral decubitus roentgenogram. The nonopaque shadows have not settled or layered but remain in the same constant position with respect to gallbladder as in (a).