

# CHYLOTHORAX

## *A Conservative Method of Management*

DONALD B. EFFLER, M.D.  
Department of Thoracic Surgery

CHYLOTHORAX is produced by interruption of the thoracic duct above the aortic hiatus with fistulous communication into a thoracic space. Such a condition is serious and will prove fatal in a high percentage of cases unless adequate treatment is instituted. A review of medical literature suggests considerable variation in opinion as to clinical management of this complication.

**Etiology:** Chylothorax is usually produced by direct trauma to the thoracic duct. Until recently the chief offenders have been penetrating wounds inflicted by bullet, steel fragment or knife. Fractures of the vertebral column and severe compression injuries of the thorax have resulted in interruption of the duct. Neoplasms involving the posterior mediastinum may be capable of producing chylothorax; care must be taken, however, to distinguish between chyle and a chyloform effusion. In recent years an increasing number of surgical procedures have been employed involving the posterior mediastinum; splanchnicectomy, esophagectomy and mediastinotomy in vascular surgery have become commonplace. Surgical injuries to the thoracic duct in these procedures are now recognized as the principal cause of chylothorax.

**Anatomy:** (Figure 1) The thoracic duct arises from the cisterna chyli at the level of the second lumbar vertebra and enters the posterior mediastinum through the aortic hiatus. The structure rests on the anterior surface of the vertebral column, usually to the right of the midline, and is intimate with the azygos vein and splanchnic nerves. Whereas variations of the thoracic duct are common, the structure usually consists of a single trunk with paired intercostal branches capable of becoming collaterals. Characteristically the duct crosses to the left at the level of the sixth thoracic vertebra and, passing under the arch of the aorta, ascends with the esophagus into the first rib circle. In the neck the duct arches above the level of the clavicle and joins the subclavian vein near its junction with the internal jugular vein.

**Physiology:** The flow rate of chyle is directly dependent on diet and fluid intake. The usual quantitative value varies between 60 cc. and 200 cc. per hour.<sup>1</sup> Total chyle output in adults usually exceeds 2.0 liters per day.<sup>1</sup> The pressure within the duct has been measured in dogs and has been found to reach 15.0 cm. of water.<sup>2</sup> The specific gravity usually is from 1.012 to 1.020. The fluid is alkaline in reaction.

The chemical constituents of chyle are those of lymph fluid with added fat. About 60 to 70 per cent of ingested fat is carried in the chyle; the quantitative value varies between 0.5 to 3.0 Gm. per cent depending on the diet. Chyle

## CHYLOTHORAX

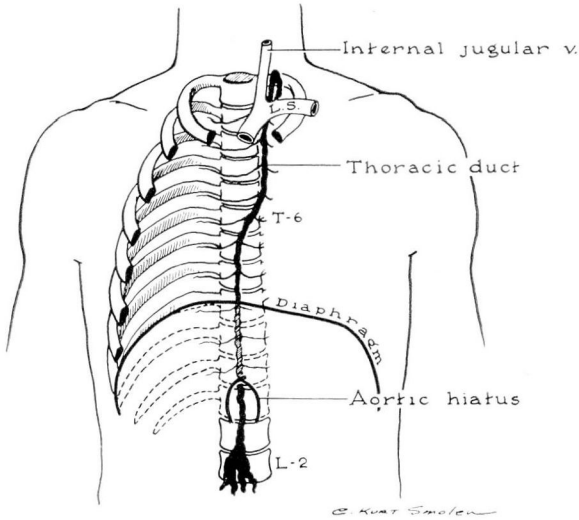


FIG. 1. Diagram illustrating the pathway of chyle.

also contains large amounts of protein; protein levels range from 1.0 Gm. to 6.0 Gm. per cent with an average level of 3.4 Gm. per cent. The nonprotein nitrogen, sugar and electrolyte levels are similar to the accompanying blood values; the lymphocyte and eosinophil counts in chyle are considerably higher than in circulating blood.<sup>2</sup>

**Symptoms:** Chylothorax may occur within a few hours following injury or an operative procedure. As a surgical complication, the chylous effusion may not appear for a period of a few days to a week. This latent period suggests that the duct was not initially severed at the time of surgery but that the fistula was secondary to impaired blood supply and local ischemic necrosis.

Regardless of the cause at the time of onset, chylothorax manifests itself by two serious disturbances in physiology: (a) asphyxia, and (b) inanition. In the former, the symptoms are identical to those of a massive hydrothorax producing mediastinal compression and shift. The symptoms of air hunger, anxiety, tachycardia, diaphoresis and pallor are related directly to the cardio-respiratory embarrassment produced by the fluid mass. Continuous loss of chyle over a period of days or weeks results in severe depletion of fat, protein, water and electrolytes. Unless the replacement of these nutritional elements exceeds the loss, a severe deficiency state develops. The symptoms of hunger, thirst and muscular weakness are indicative of physical deterioration and inadequate therapy.

### Case Report

A 14 month old white girl weighing 24 pounds was admitted to the Cleveland Clinic Hospital for diagnosis and therapy. According to the parents, the child suffered

repeated episodes of regurgitation when feeding and recurrent pulmonary infection associated with aspiration of food. Studies by Dr. F. Mason Sones in the Department of Cardiology included retrograde aortography. Doctor Sones established the diagnosis of dysphagia luzoria with a retro-esophageal right subclavian artery arising from the left descending aorta.

On May 16, 1951, a left thoracotomy was performed and mediastinal dissection of the aorta and its major branches carried out. As assumed by Doctor Sones, the right subclavian artery originated in the posterior descending aorta, and passed between the esophagus and vertebral body to enter the right thorax. The vessel was isolated and divided between ligatures. During the course of the dissection, the thoracic duct was visualized and precautions were taken to avoid injuring the structure. There was no discernible injury and no escape of chylous fluid (fig. 2).

The immediate postoperative condition was satisfactory; however, on the fifth postoperative day an abrupt change occurred in the patient's condition. The diagnosis of left hydrothorax was made. Postoperative films prior to the fifth postoperative day showed no evidence of fluid in the left thorax. Aspiration revealed pure chyle in the left thorax; approximately 300 cc. was removed. The patient was placed on oral starvation; however, the chyle re-formed at the rate of approximately 400 cc. per day. Careful measurement of the fluid intake was made and adequate intravenous replacement instituted.

On May 26, 1951, a Foley bag catheter was inserted under local anesthesia and connected to water-seal suction. At the same time the patient was placed on skimmed milk feedings, as obliteration of the peripheral veins from the continuous intravenous feedings made this change mandatory. Free drainage of the chyle permitted re-expansion of the left lung and the daily total volume of fluid was easily measured. Average total volume per 24 hours for the first 3 days following institution of the continuous suction drainage was 798 cc. The character of the fluid was typical of chyle although an undetermined amount of pleural fluid was undoubtedly present. Approximately 4 days after closed suction, or 8 days after the discovery of the hydrothorax, the daily total output reduced to 510 cc. On May 31, 1951, a total output from the chest was 420 cc. and following this date there was a rapid diminution in the chyle flow. On June 4, 1951, approximately 12 days after the onset of the chylothorax, there was only 40 cc. of chyle delivered to the tube. The tube was then alternately clamped and opened every hour without change in the patient's general condition. Radiographic films showed complete expansion of the left lung and it was believed that pleural symphysis had occurred. The tube was then clamped for 36 hours with no observable change and removed on June 6, 1951.

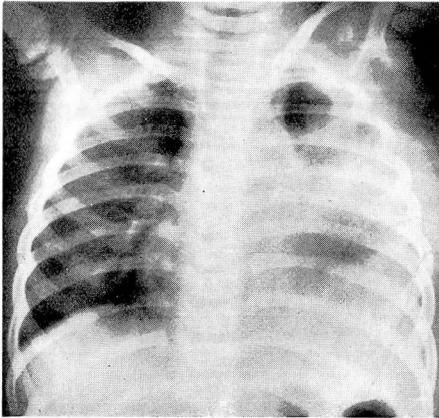
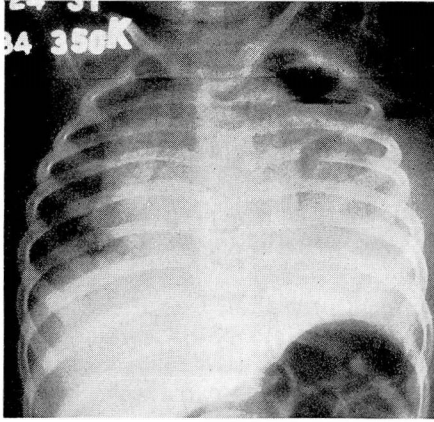
While significant chemical changes were observed during this entire period, the patient did not suffer appreciable weight loss nor did clinical dehydration occur at any time. The child has been seen on repeated occasions and appears to have recovered completely without residual.

### Discussion of Therapy

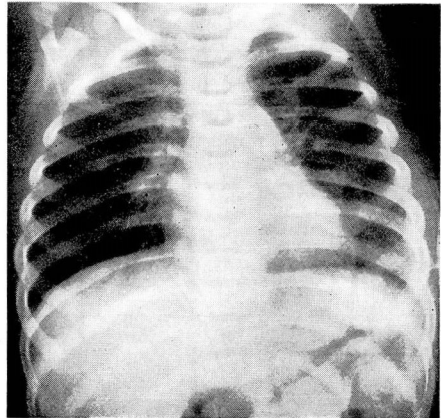
Treatment of chylothorax has included surgical ligation of the severed thoracic duct,<sup>1,3</sup> multiple thoracenteses with intravenous injection of the aspirated chyle,<sup>4</sup> oral starvation and periodic needle aspiration. In 1938, the literature revealed a mortality rate of 50 per cent in patients with chylothorax. The cause of death is usually attributable to the effects of dehydration and inanition.

## CHYLOTHORAX

(a)



(b)



(c)

FIG. 2. (a) Radiographic appearance of severe pneumochoylothorax after initial aspiration of 200 cc. of chyle. Note deviation of mediastinum to the right and obliteration of all lung markings on the operative side. (b) Roentgenogram made following institution of closed suction drainage by Foley bag catheter and water seal. (c) Final roentgenogram made one month after discharge from the hospital. There is minimal residual pleural thickening on the left.

The direct approach of surgical ligation has the advantage of being definitive; closure of the chyle fistula is obviously desirable. However, the disadvantages should not be overlooked. Exploration of the mediastinum under general anesthesia is a serious undertaking in this type of patient. Likewise, the problem of finding the chyle leak may be difficult; anatomic variations plus depositions of fibrin and clot may be factors which seriously handicap the surgeon. Possibly extensive mediastinal dissection with unsuccessful closure may convert the chylothorax into a bilateral process. Although indications

differ with the experience and ability of the individual surgeon, the diagnosis of chylothorax does not necessitate immediate surgical intervention.

Aspiration of chyle by thoracentesis is diagnostic and therapeutic. Relief of pressure produced by extensive chylothorax will prevent mediastinal compression and its accompanying serious cardiorespiratory disturbances. However, aspiration alone may be only a temporizing procedure since it can do little to retard re-formation of the intrapleural chyle. Actually tremendous quantities of chyle may be removed over the period of a week resulting in serious fluid and nutritional deficits. The hope of spontaneous closure of the chyle fistula during this time is not justified when the patient's condition shows progressive deterioration.

Intravenous replacement of aspirated chyle has been advocated as a supportive measure.<sup>4</sup> As might be anticipated, certain hazards may be encountered. Sudden death has been reported following the infusion of aspirated chyle.<sup>5</sup> As mentioned in the preceding paragraph, this course of management, coupled with aspiration, is predicated in anticipation of spontaneous closure of the fistula. For this reason oral starvation has been suggested as a means of reducing the chyle volume flow. While this apparently is not a definitive procedure, it is said to have been successful when employed by English surgeons in World War II. It appears, however, to be a forceful approach to a problem characterized by inanition; not unlike purgation in acute diarrhea.

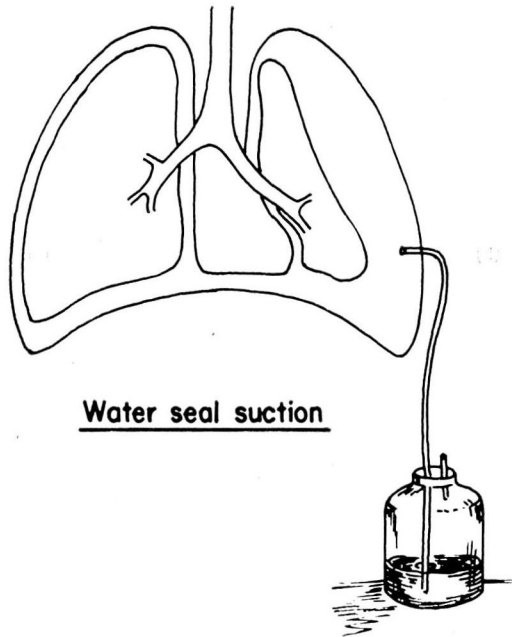


FIG. 3. Diagram of simple principle of water-seal suction drainage. Any form of intercostal catheter may be employed; the Foley bag catheter has been most successful in our experience.

Any treatment of chylothorax, both conservative (nonsurgical) and definitive, would have obvious advantages. A method employing closed suction drainage with supportive therapy has been used once, successfully, and is reported herein. Although conclusions cannot be drawn on the basis of one case, the rationale may be of interest. Since chylothorax is a rare complication, clinical impressions must be obtained without benefit of case series.

Chyle is an alkaline fluid and peculiarly resistant to bacteria; empyema has not been reported as an added complication. Chyle also is an irritant to the pleura and excites a fibrinous exudate over the uninvolved surface. Whereas a needle aspiration removes a part or most of the chyle, it is impossible to obtain the entire volume. Continuous suction drainage can evacuate the fluid as rapidly as it forms; more important, it permits continuous expansion of the lung allowing approximation of the visceral and parietal pleura. Obliterative pleuritis may rapidly produce a firm symphysis between the lung and chest wall. When this occurs the pressure potential of the chyle is less than that required to re-collapse the lung, i. e. continuous expansion of the lung with resultant pleural symphysis may act as a physiologic tampon in the chyle fistula.

The method of establishing a closed catheter drainage is simple. Under local anesthesia a stab wound incision is made, usually at the suspected level of the fistula in the posterior axillary line. A Foley bag catheter is inserted and connected by tubing to a water-seal suction jar (fig. 3). The amount of sterile water in the jar is measured carefully and the daily output is charted. Machine suction on the water trap is neither necessary nor desirable. Since the danger of empyema is remote, the tube may be left in place for considerable time. The degree of expansion or pressure of undrawn fluid may be determined by roentgenograms at intervals. If expansion is prompt and maintained, pleural symphysis should be well established within a week. After that time the status of fistula and pleural obliteration can be determined by periodic clamping of the tube.

In addition to the closed drainage, the nutritional requirements of the patient must be met. Emphasis on fluid and electrolyte balance is obvious; the need for protein supplement is likewise apparent. Employment of oral and parenteral routes of feeding will depend on the individual case; both procedures may be necessary.

#### References

1. Ehrenhaft, J. L. and Meyers, R.: Blood fat levels following supradiaphragmatic ligation of thoracic duct. *Ann. Surg.* **128**:38 (July) 1948.
2. Best, C. H. and Taylor, N. B.: *The Physiological Basis of Medical Practice*, ed. 2 Baltimore, William Wood and Company, 1939, p. 48.
3. Hodge, G. B. and Bridges, H.: Surgical management of thoracic duct injuries; experimental study with clinical application. *Surgery* **24**:805 (Nov.) 1948.
4. Bauersfeld, E. H.: Traumatic chylothorax from ruptured thoracic duct treated by intravenous injection of aspirated chyle. *J.A.M.A.* **109**:16 (July 3) 1937.
5. Whitcomb, B. B. and Scoville, W. B.: Postoperative chylothorax; sudden death following infusion of aspirated chyle. *Arch. Surg.* **45**:747 (Nov.) 1942.