

EOSINOPHILIC GRANULOMA, BILATERAL MASTOID INVOLVEMENT

A Case Report

HAROLD E. HARRIS, M.D. and DAVID M. SPENCER, M.D.*

Department of Otolaryngology

IN review of the literature it was found that xanthomatous lesions of the temporal bones are not unusual, but that only 3 cases of bilateral mastoid involvement have been reported^{1,2,3} since Schuller and Christian discussed, in 1915 and 1919 respectively, cases presenting a syndrome now known as Hand-Schuller-Christian's disease. Hand's name became associated with this syndrome because he reported one case in 1893 and another in 1921 which presented the clinical triad of diabetes insipidus, exophthalmos, and bony defects of the skull—the findings necessary to establish the diagnosis of Hand-Schuller-Christian's disease. He attributed this to tuberculosis, however.

In 1932 Greifenstein⁴ reviewed the 26 cases of Hand-Schuller-Christian's disease appearing in the literature up to that time and noted that the ear was involved in 12 of these cases. Not until 1935 did an abundance of literature on Hand-Schuller-Christian's disease or eosinophilic granuloma appear in the journals; several years later the true relationship between these two entities and Abt-Letterer-Siwe's disease was established.

The histopathology involved in this syndrome was defined in 1928 by Rowland⁵ who concluded that it consisted of a form of xanthoma involving the reticulo-endothelial system of certain areas of the skull. However, it was not until 1940 to 1948 that the close association of Abt-Letterer-Siwe's disease, Hand-Schuller-Christian's disease and eosinophilic granuloma, as variants of the same xanthomatous disease, was recognized.⁶

In view of the infrequent instances of bilateral mastoid involvement by eosinophilic granuloma found in the literature, it was felt that this case would provide an interesting report. In addition, a not unusual diagnostic error is demonstrated.

The patient, a 3 year old white girl who apparently had been in good health for the first 2 years of life, was seen in the Department of Neurosurgery of the Cleveland Clinic in September 1950. At that time a diagnosis was made of eosinophilic granuloma in the right parietal area of the skull. The roentgenologic diagnosis (fig. 1) was confirmed histologically at the time a cranioplasty was performed, the involved area removed, and the defect covered with tantalum. She was sent home and not seen again until January 11, 1951, at which time she was first observed in the Department of Otolaryngology. She had been brought into the Clinic because of a chronically draining wound behind her left ear. The history revealed that shortly following the previous hospital discharge, she developed a slight swelling behind the ear. The family physician felt that this was an infectious process as a result of the child's scratching this area, especially

*Former Fellow. At present a Resident at University Hospital, Cleveland.

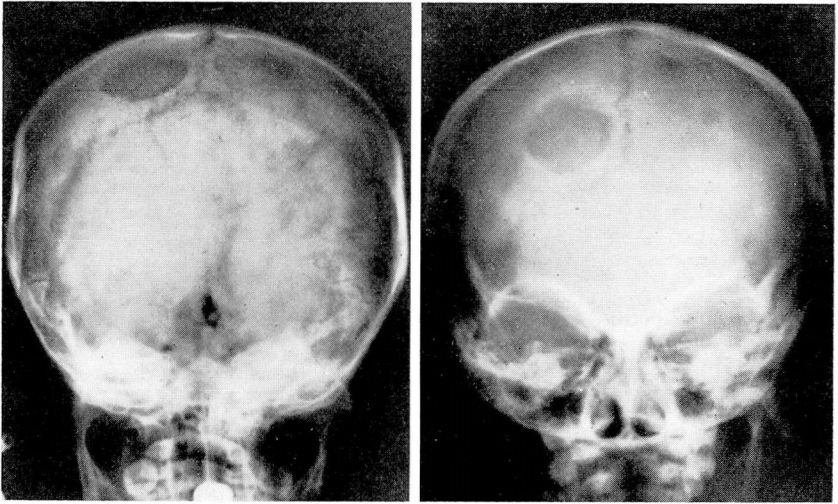


FIG. 1. Other portions of skull involved as shown by the circular area of radiolucency involving both inner and outer tables of skull in posterior parietal region.

in view of the fact that no evidence existed of otitis media and no history of otalgia. There was, however, neither fever, chills, nor pain. The mass was incised by the family physician and pus drained from the wound. The wound continued to drain serous material and showed poor healing tendencies. When seen in the Clinic, a draining fistula behind the left ear was observed. Also, considerable debris was encountered in both external auditory canals. After this debris had been removed, it was noted that there was a bulging of the posterior canal wall into the lumen of the left external auditory meatus. Mastoid x-rays were taken bilaterally which revealed almost identical destructive lesions. The x-rays were so similar that the possibility was considered an error had occurred in marking and the films were repeated with special attention that right and left films were obtained and correctly identified. The repeat films demonstrated radiolucent punched-out or destructive areas in both mastoid processes and both petrous ridges (fig. 2). This roentgenographic evidence, in addition to the previously obtained pathologic evidence at the time of the cranioplasty, would be adequate for diagnosis. However, on January 24, 1951, a biopsy was taken from the bulging area of the posterior canal wall of the left external auditory meatus. This was reported as follows:

“Pathologic diagnosis: eosinophilic granuloma (biopsy left external auditory canal).

Gross: Three fragments of tissue, averaging about 3 mm. in diameter.

Microscopic: Section reveals tiny fragments of tissue formed principally by granulation tissue containing frequent mononuclear cells with acidophilic and neutrophilic cytoplasm, nuclei oval, round or indented and occasionally with several nucleoli. Intermingled with these are cells, principally eosinophilic with segmented nuclei. Capillaries are less in evidence than in usual granulation tissue. Also present is a tissue fragment covered by well differentiated, keratinizing squamous epithelium, underlying tissue being infiltrated by many eosinophiles and a few histiocytes.”

Therapy consisted of seven x-ray treatments to each temporal bone, totalling

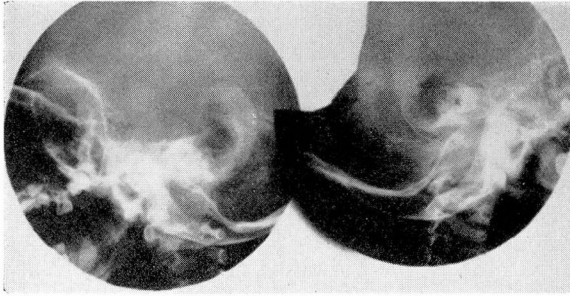


FIG. 2. Roentgenograms reveal large destructive areas in both mastoid regions resembling operative defects.

850 r each side. Approximately one week following completion of the x-ray therapy, the postauricular fistula was healed and the bulge in the left auditory canal wall had receded.

This child has been observed at numerous intervals, subsequently, and the left ear canal remains dry and the postauricular sinus tract is closed with no evidence of postauricular swelling. However, on January 10, 1952, the child returned because of a postauricular swelling and discharge from the right (opposite) ear. At that time, further x-ray therapy was given to the right mastoid region and one week later the discharge had subsided and the ear again appeared to be normal.

Summary

A case of eosinophilic granuloma is reported with the unusual finding of bilateral mastoid involvement, as proved on biopsy.

The roentgenographic findings in the mastoid bones resemble operative defects. The associated infection and swelling of the ear canals, as well as the postauricular sinus tract, responded well to x-ray therapy.

References

1. Schuknecht, H. F. and Perlman, H. B.: Hand-Schuller-Christian disease and eosinophilic granuloma of skull. *Ann. Otol. Rhin. and Laryng.* **57**:643 (Sept.) 1948.
2. Shea, J. J.: Xanthomatosis (Schuller-Christian disease); report of case with radiosensitive pathology in mastoid. *Laryngoscope* **48**:589 (Aug.) 1938.
3. Wood, V. V.: Bilateral xanthomatosis (lipoidosis) of mastoid; case report. *Ann. Otol., Rhin. and Laryng.* **46**:991 (Dec.) 1937.
4. Greifenstein, A.: Involvement of ear, accessory nasal sinuses and maxilla in generalized xanthomatosis. *Arch. f. Ohren-Nasen-u. Kehlkopfh.* **132**:337 (Sept.) 1932.
5. Rowland, R. S.: Xanthomatosis and reticulo-endothelial system. *Arch. Int. Med.* **42**:611 (Nov.) 1928.
6. Goodhill, V.: Histiocytic granuloma of skull (triphasic clinico-pathologic syndrome previously termed Letterer-Siwe's disease, Hand-Schuller-Christian's disease, and eosinophilic granuloma). *Laryngoscope* **60**:1 (Jan.) 1950.