

# GASTRIC CARCINOMA ASSOCIATED WITH GASTROENTEROSTOMY

H. S. BENNETT, M.D. and H. R. ROSSMILLER, M.D.

Department of Gastroenterology

CARCINOMA of the stomach is an uncommon complication in patients who have undergone gastroenterostomy. Gray and Lofgren<sup>1</sup> found only 17 cases of carcinoma in 825 instances where surgical exploration of a previously performed gastroenterostomy was undertaken. The infrequency of coexistent duodenal ulcer and gastric carcinoma has been repeatedly emphasized (Bockus,<sup>2</sup> Eusterman and Balfour,<sup>3</sup> Fischer et al<sup>4</sup>). Orringer,<sup>5</sup> in a recent review of the literature, was able to accumulate only 32 instances of gastric malignancy which developed following surgery for chronic duodenal ulcer.

Gastroenterostomy has been performed in the past as a definitive operation for benign or supposedly benign gastric lesions. One might expect that instances of gastric carcinoma associated with gastroenterostomy would be found in this group. Some of the gastric ulcers thought to be benign at the time of operation might have been, in reality, neoplastic. Furthermore, some authorities believe that a malignant change can occur in a benign gastric ulcer. It is surprising, therefore, to find little in the literature regarding such cases. Gray and Lofgren<sup>1</sup> in their large series, reported only 6 patients with carcinoma of the stomach in whom gastroenterostomy had previously been performed for presumably benign gastric ulcers.

We have recently studied 3 patients in whom cancer of the stomach and gastroenterostomy were found to be associated. We are reporting these cases because of their relative rarity and because they illustrate several interesting points in diagnosis.

**Case 1.** A 60 year old white male cook was admitted to the Cleveland Clinic November 5, 1951, complaining of anorexia, aerophagia and postprandial distention. These symptoms had begun only a few weeks previously. There was no weight loss, although food intake had been curtailed by postprandial distress.

The past history was significant in that, in 1929, a posterior gastroenterostomy had been performed elsewhere, presumably for a duodenal ulcer. Prior to operation the patient had experienced periodic epigastric distress relieved by food. There had been no recurrence of these symptoms. In 1938 a combined abdominoperineal resection had been performed for adenocarcinoma of the rectum. The lesion was successfully removed despite the fact that there was some extension to the perirectal fat. In 1944 it became necessary to carry out further resection of the sigmoid colon and to establish a new colostomy. No evidence of recurrent carcinoma was found.

Physical examination revealed no significant findings other than a functioning colostomy and a small sac of herniated omentum at the site of the original colostomy.

Laboratory studies showed the erythrocyte count to be 5,580,000 per cu. mm.; the leukocyte count to be 5400 per cu.mm. and the hemoglobin to total 13.5 Gm. per

hundred cc. Gastric analysis, after alcohol stimulation, demonstrated a total acidity of 36 units per hundred cc. with 18 units of free hydrochloric acid. The blood urea was 24 mg. per hundred cc.

A roentgenogram of the chest showed no abnormalities. X-rays of the stomach after a barium meal demonstrated narrowing of the distal two-thirds with polypoid change in the antrum (fig. 1). These changes were thought to represent an infiltrating neoplasm. A barium enema showed no abnormality of the colon.

An exploratory laparotomy was carried out and a large carcinoma of the stomach was found. There was extensive spread of the neoplasm throughout the peritoneal cavity, and ascites was present. The carcinoma was judged inoperable, and no palliative procedure was possible. A biopsy of the omentum showed "carcinoma, simplex, colloid in type." Postoperatively the patient was discharged for terminal care.

**Case 2.** This patient was first seen at the Clinic in September 1948 for gastroscopic examination only. He gave a history of epigastric distress of many years' duration. Gastroscopic examination revealed a linear ulcer of the lesser curvature surface of the antrum which had the appearance of a benign lesion.

In October 1948 the patient had an operation at another hospital during which posterior gastroenterostomy was performed and bilateral vagotomy done. His condition was apparently satisfactory until the fall of 1950 when postprandial epigastric pain developed which was relieved by antacids. The pain progressed in severity, the patient noted slight weight loss and experienced a general decrease in vitality.

At the time of admission on August 21, 1951, physical examination was normal except for a well healed right upper quadrant incisional scar. Routine urine analysis was essentially negative. There were 3,420,000 erythrocytes and 9850 leukocytes per cu. mm. and 8.8 Gm. of hemoglobin per hundred cc. Gastric analysis, after both alcohol and histamine stimulation, showed no free hydrochloric acid. Blood urea was 30 mg. per cent. Wassermann and Kahn tests were negative.

A roentgenogram of the chest was completely normal. A study of the stomach after a barium meal proved the stoma of the gastroenterostomy to be functioning and demonstrated antral deformity with probable ulceration (fig. 2). A malignant lesion was suspected by the roentgenologist.

Gastroscopic examination revealed narrowing and fixation of the antrum consistent with a diagnosis of infiltrating neoplasm.

Laparotomy was performed and an ulcerating but nonpenetrating carcinoma of the antrum of the stomach was found. This lay along the lesser curvature distal to a patent gastroenterostomy. The proximal duodenum was normal. The neoplasm was successfully resected, together with the lower two-thirds of the stomach, and a gastrojejunal anastomosis made. The resected neoplasm was found on histologic study to be a superficial adenocarcinoma with grade III dedifferentiation. No regional nodes were involved.

The patient made an uneventful recovery, and when last seen on February 21, 1952, appeared well although he complained of symptoms of a mild "dumping syndrome."

**Case 3.** A 50 year old service station attendant had experienced recurrent epigastric distress for 2½ years prior to admission to the Clinic. At the onset his symptoms consisted of postprandial distress relieved by vomiting. Gastric ulcer was diagnosed elsewhere and, 27 months prior to admission, posterior gastroenterostomy was performed. The patient was well until 12 months prior to entry when gastrointestinal bleeding began, as evidenced by tarry stools. Epigastric pain relieved by vomiting

recurred throughout the ensuing year. Symptoms were partially controlled by medical ulcer management but pain became progressively worse and the patient lost about 35 pounds. There were no pertinent physical abnormalities at the time of admission other than generalized abdominal tenderness.

Routine urine analysis showed no abnormalities. There were 10.8 Gm. per hundred cc. of hemoglobin and 9850 per cu. mm. leukocytes. The Wassermann and Kahn tests were negative. Blood urea was 30 and fasting blood sugar 83 mg. per hundred cc. Gastric analysis, following histamine stimulation, showed a total acidity of 56 units and a free hydrochloric acid of 42 units.

Roentgenograms of the chest and the kidney-ureter-bladder area were noncontributory. The gallbladder was visualized following administration of cholecystographic dye and found to be normal. Study of the stomach revealed a normally functioning gastroenterostomy. A bizarre mucosal pattern was observed in the distal portion of the stomach which was thought to represent carcinoma and the first portion of the duodenum was deformed.

Laparotomy was performed and a large neoplasm of the antral and pyloric areas was found. This was deeply ulcerated and appeared to arise from the posterior wall. The neoplasm had spread beyond the stomach and only a palliative resection was possible. Histologic examination of this tumor revealed scirrhous carcinoma of the stomach with lymph node metastases.

The patient was discharged on the eighth postoperative day.

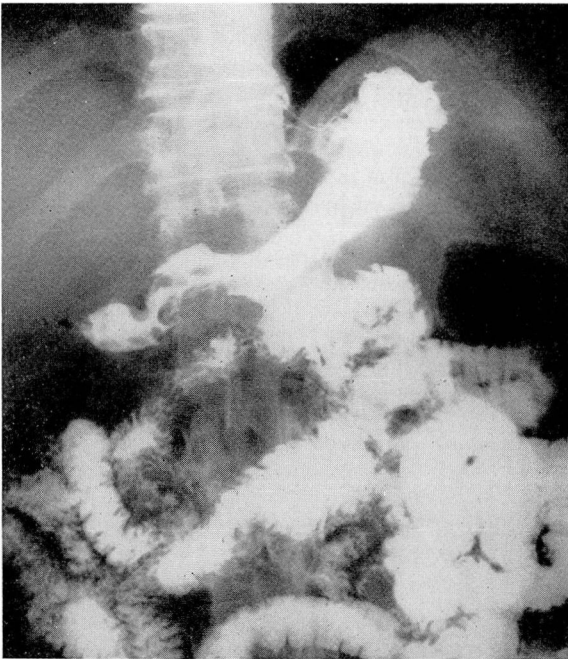


FIG. 1. Case 1. Roentgenogram of stomach. A functioning gastroenterostomy is demonstrated. Distal to this may be seen narrowing of the antrum and a large filling defect. This proved to be an inoperable carcinoma.

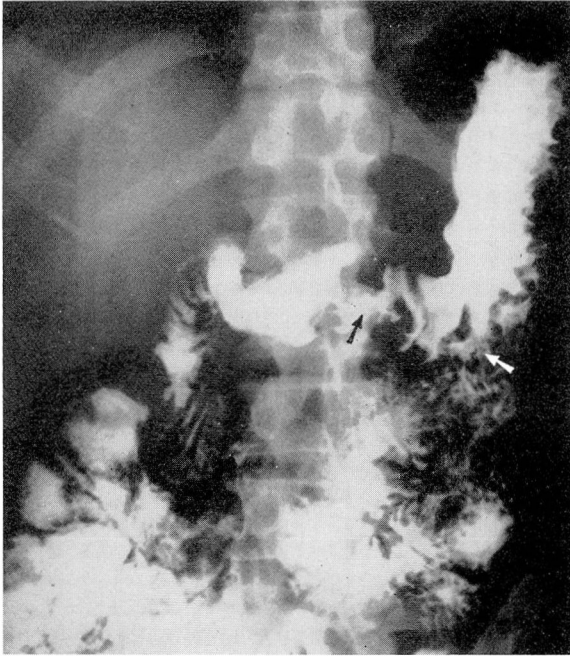


FIG. 2. Case 2. Roentgenogram of stomach. Arrow on right shows site of gastroenterostomy; that on left points to a large ulcerating neoplasm in distal portion of stomach.

### Discussion

It is common practice to minimize the possibility of a gastric neoplasm in a patient who has been shown to have a duodenal ulcer. Complications following gastroenterostomy are almost automatically considered to be of a more benign nature. Our first case demonstrates the fallacy of such thinking; here the diagnostic problem was simplified by the fact that the symptoms were of recent origin and did not resemble the typical pattern of peptic ulcer. This patient had no evidence of anemia or achlorhydria, which, had they been present, would have furnished valuable diagnostic clues. Lofgren and Gray<sup>1</sup> found either achlorhydria or a low free acidity in all of their patients who were in this group. X-ray studies of the stomach (fig. 1) were strongly suggestive of an extensive infiltrating neoplasm, and laparotomy confirmed this diagnosis. It is interesting that this patient developed a second malignant neoplasm of the gastrointestinal tract some years after having been cured of the first.

The second and third patients presented a more complicated problem. Here gastroenterostomies were performed for presumably benign gastric ulcers; in retrospect these may well have been malignant lesions. The rather vague and prolonged symptoms recited by the second patient did not suggest malignant disease. The diagnosis was established by a number of objective findings which included moderate anemia, achlorhydria following histamine

stimulation, and roentgenologic demonstration (fig. 2) of an ulcerating lesion in the antrum. Gastroscopic visualization of the antrum provided valuable collateral evidence.

The third case had several features suggestive of benign ulceration. The course was of more than 2 years' duration; the symptoms were periodic and responded to medical management. Gastrointestinal hemorrhage had occurred nearly a year prior to the final laparotomy. Of the objective data available, only the x-ray study of the stomach suggested the presence of neoplasm.

Lofgren and Gray<sup>1</sup> found that 7 of 11 patients who had gastroenterostomies for gastric lesions required further surgery within 4 years and in the majority of instances were proved to have carcinoma. Our second and third cases exhibited a similar course. The short interval between operations strongly suggests that the original lesions were malignant. These cases demonstrate graphically the danger of any operation short of gastric resection for gastric ulcer. All clinical evidence may indicate a benign lesion and the ulcer may appear benign to the surgeon, yet prove subsequently to be malignant. The diagnosis can only be made with certainty by the pathologist. Tissue diagnosis should be obtained of any gastric lesion for which surgery is necessary.

### Summary

Three cases of gastric carcinoma associated with gastroenterostomy have been presented and the diagnostic features discussed. Two of these patients illustrate the inadequacy of any procedure other than gastric resection in the surgical treatment of gastric ulcer.

### References

1. Gray, H. K. and Lofgren, K. A.: Significance of ulcerating lesion in stomach after gastroenterostomy. *Proc. Staff Meet. Mayo Clin.* **23**:454 (Sept. 29) 1948.
2. Bockus, H. L.: *Gastro-Enterology*, vol. 1. Philadelphia, W. B. Saunders Company, 1943.
3. Eusterman, G. B. and Balfour, D. C.: *The Stomach and Duodenum*. Philadelphia, W. B. Saunders Company, 1935.
4. Fischer, A., Clagett, O. T. and McDonald, J. R.: Coexistent duodenal ulcer and gastric malignancy. *Surgery* **21**:168 (Feb.) 1947.
5. Orringer, D.: Carcinoma of stomach following surgery for chronic duodenal ulcer. *Surgery* **28**:680 (Oct.) 1950.