

UROLOGIC PROBLEMS IN CHILDHOOD *

WILLIAM J. ENGEL, M.D.

The problems presented by diseases of the urinary tract in children have a right, I think, to be segregated from the other problems with which the urologist is confronted, not only because these diseases in childhood differ in many respects from those in adults, but also because attention is thus directed to lesions in the urinary tract in children which are all too often

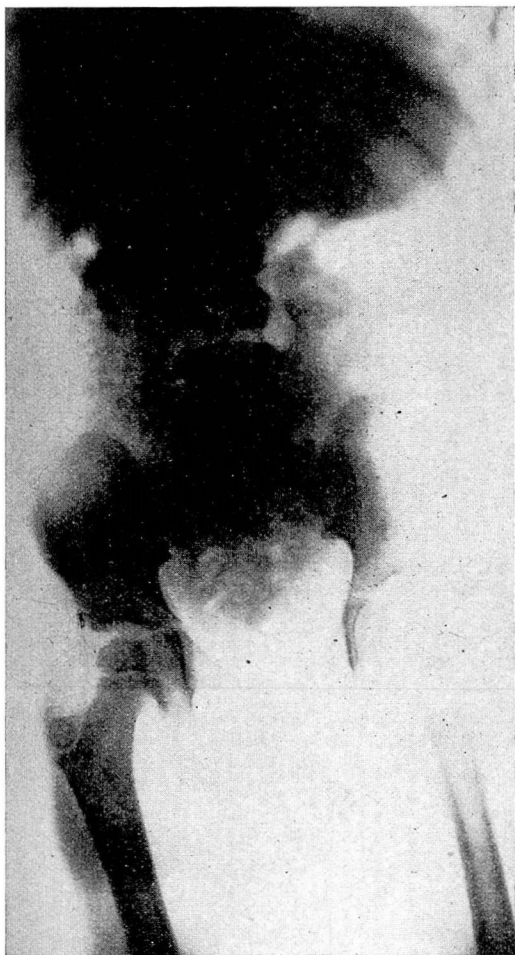

FIG. 1.—The patient was a girl, four and one-half years of age, who had had pyuria for three years.

Roentgenogram shows a large calculus in the right kidney.

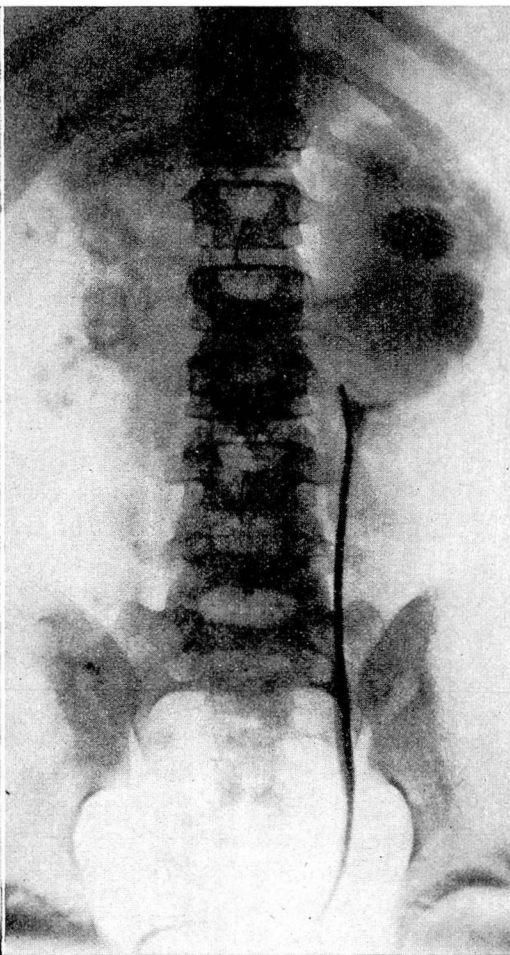
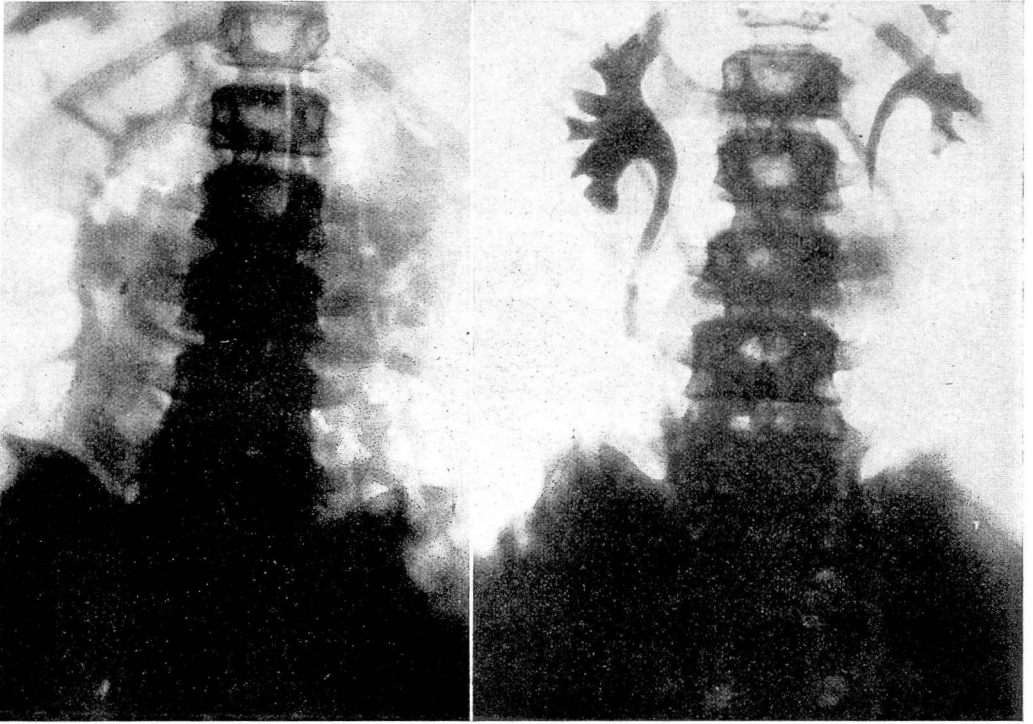


FIG. 2.—The patient was a girl nine years of age.

Roentgenogram shows calculous pyonephrosis of right kidney and hydronephrosis of the left kidney, due to an aberrant artery.

*Reprinted by permission from *Radiology*, Vol. 24:183-192 February 1935

UROLOGIC PROBLEMS IN CHILDHOOD



FIGS. 3A and 3B. The patient was a boy twelve years of age. FIG. 3A (*left*) Plain roentgenogram shows a shadow in the region of the right ureter. FIG. 3B (*right*). Intravenous urogram shows the shadow to be a calculus in the ureter. There is hydronephrosis of the right kidney.

overlooked. Many phases of urinary diseases in children might be discussed, but I have chosen to emphasize certain problems relating to the upper urinary tract.

Urologic diagnosis in infants and young children is rendered more difficult because of the impossibility of eliciting subjective symptoms accurately and because physical examination is so often unsatisfactory. The diagnostic methods, however, differ in no way from those employed in adults, and roentgenologic examinations play a major role in all cases. Every child who is suspected of having some disease of the urinary tract should have a

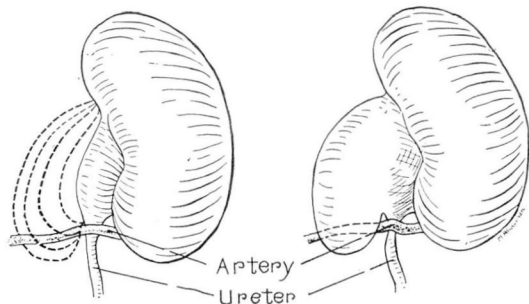
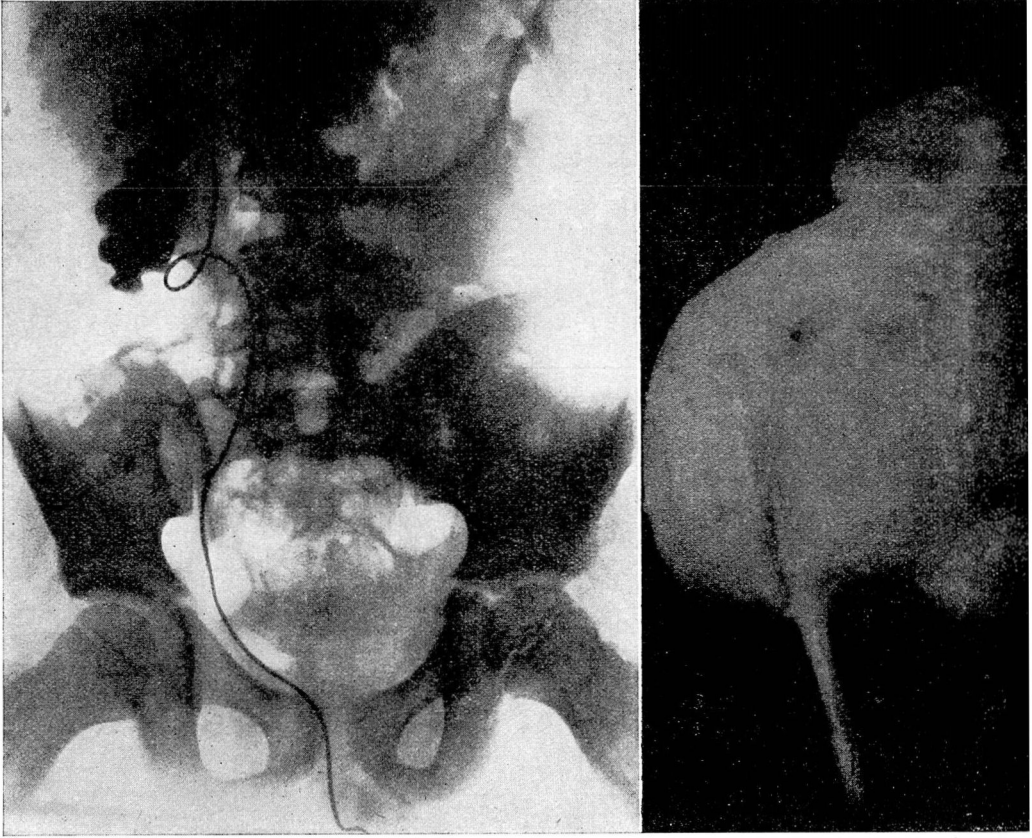

FIG. 4.—Schematic drawing, showing successive stages of dilatation of the kidney pelvis over an aberrant artery.



FIGS. 5A and 5B. The patient was a boy nine years of age. Fig. 5A (*left*). Retrograde pyelogram shows marked hydronephrosis and almost complete destruction of the kidney tissue. FIG. 5B (*right*) Photograph of specimen, showing marked hydronephrosis due to aberrant artery which is well demonstrated.

preliminary stereoroentgenogram of the kidneys, ureters, and bladder, followed by additional studies according to the individual indications.

When intravenous urography was introduced it was hoped that this would solve the problem of urologic diagnosis in children, but it has not completely met these expectations. Although it is employed more or less routinely as a preliminary investigation, it has been, on the whole, rather disappointing as regards final diagnosis and in many instances it has been necessary to resort to cystoscopy and retrograde pyelography before any final decision could be reached. This experience is supported by Campbell's recent report of 304 urograms in children, of which only 47.5 per cent were of diagnostic value and only 7 per cent furnished the

UROLOGIC PROBLEMS IN CHILDHOOD

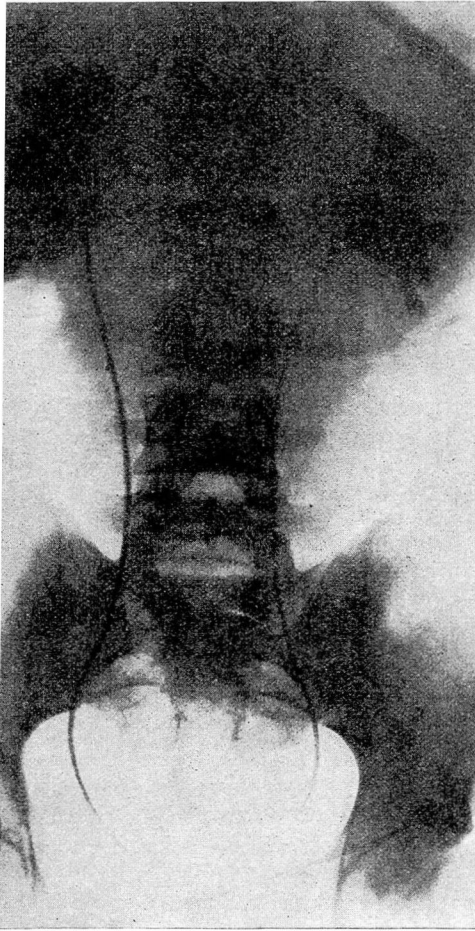

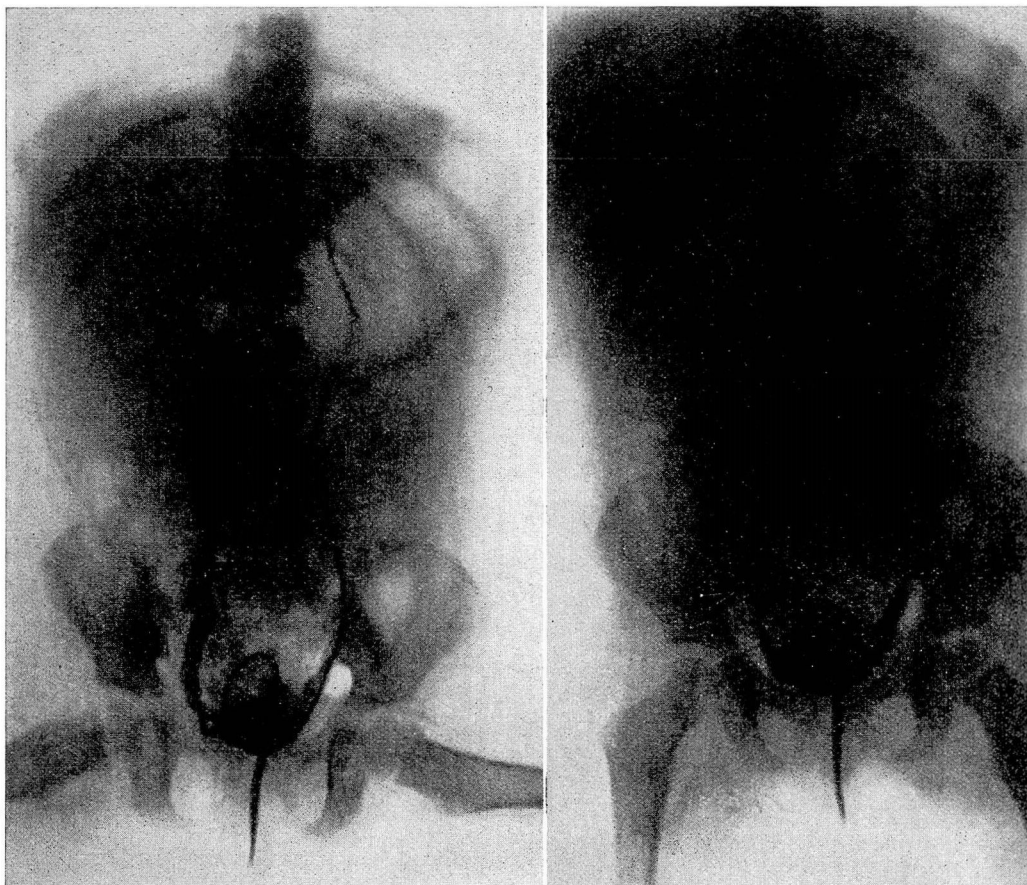
FIG. 6.—The patient was a boy sixteen years of age. Pyelogram shows bilateral hydronephrosis due to aberrant artery.

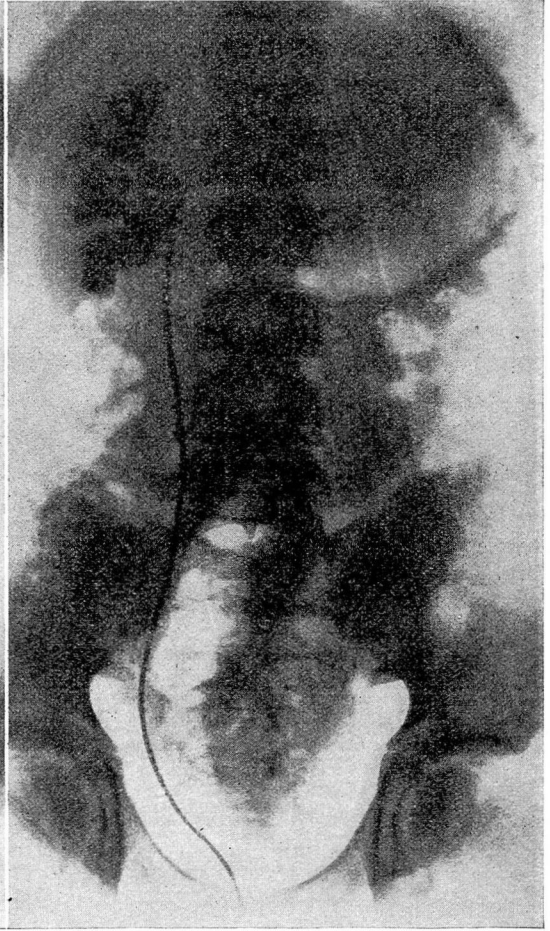

FIG. 7.—The patient was a boy fifteen years of age. Retrograde pyelogram shows hydronephrosis due to an aberrant artery. Complete relief of symptoms was experienced after conservative operation.

correct diagnosis without further study. I do not mean to underestimate the value of intravenous urography. It has been of tremendous assistance, but one must be prepared to proceed further in that considerable group of cases in which intravenous urography does not yield conclusive diagnostic evidence. There should be no hesitancy in proceeding to cystoscopy, ureteral catheterization, and retrograde pyelography. Cystoscopy can be safely carried out, no matter how young the patient, and in gentle hands does not increase the hazard.

I shall now discuss some of the specific problems presented by



FIGS. 8A and 8B.—This is a case of congenital megaloureter. The patient was a girl, three years of age, who had had chills and fever since she was four and one-half months of age. FIG. 8A (*left*) Right pyelogram. FIG. 8B (*right*). Left pyelogram shows bilateral dilatation of ureters. Bilateral vesicorenal reflux was demonstrated later by cystogram.

the different diseases of the upper urinary tract in children. These may be grouped under three headings: (1) urinary calculi; (2) upper urinary lesions of congenital origin, under which I have included aberrant arteries, congenital megaloureter, and ureterovesical stricture, and (3) kidney tumors.

URINARY CALCULI

Urinary calculosis is not common in children when compared with the incidence of this condition in adults. In a series of 1,388 cases of urinary calculi seen at the Cleveland Clinic there were 17 cases in children under fifteen years of age, or an incidence of 1.2 per cent. As in the case of adults, stones may occur anywhere along the urinary tract. In our group of cases there were seven in

UROLOGIC PROBLEMS IN CHILDHOOD

the kidney, seven in the bladder, one in the bladder and kidney, two in the ureter only, and one in the kidney, bladder, and ureter.

The clinical picture differs in no way from that seen in the adult. Pain, of course, is the outstanding symptom. In children, however, this is much more frequently associated with rather marked gastro-intestinal symptoms, such as nausea and vomiting, and often muscle spasm of the abdominal wall. This may lead to considerable confusion in diagnosis and an intra-abdominal lesion often is suspected in these cases. The findings of pus cells and red blood cells in the urine, however, should lead one to suspect the true nature of the trouble. Persistent pyuria, especially, should lead to the suspicion of kidney stones. In all cases in which this symptom is present, a plain roentgenogram should be made. This will show stones in the vast majority of instances (Figs. 1, 2, 3A, and 3B).

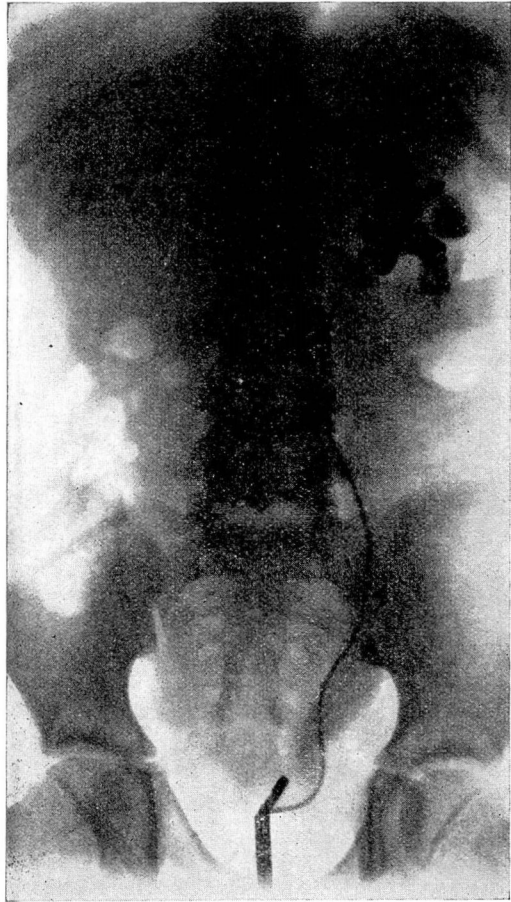
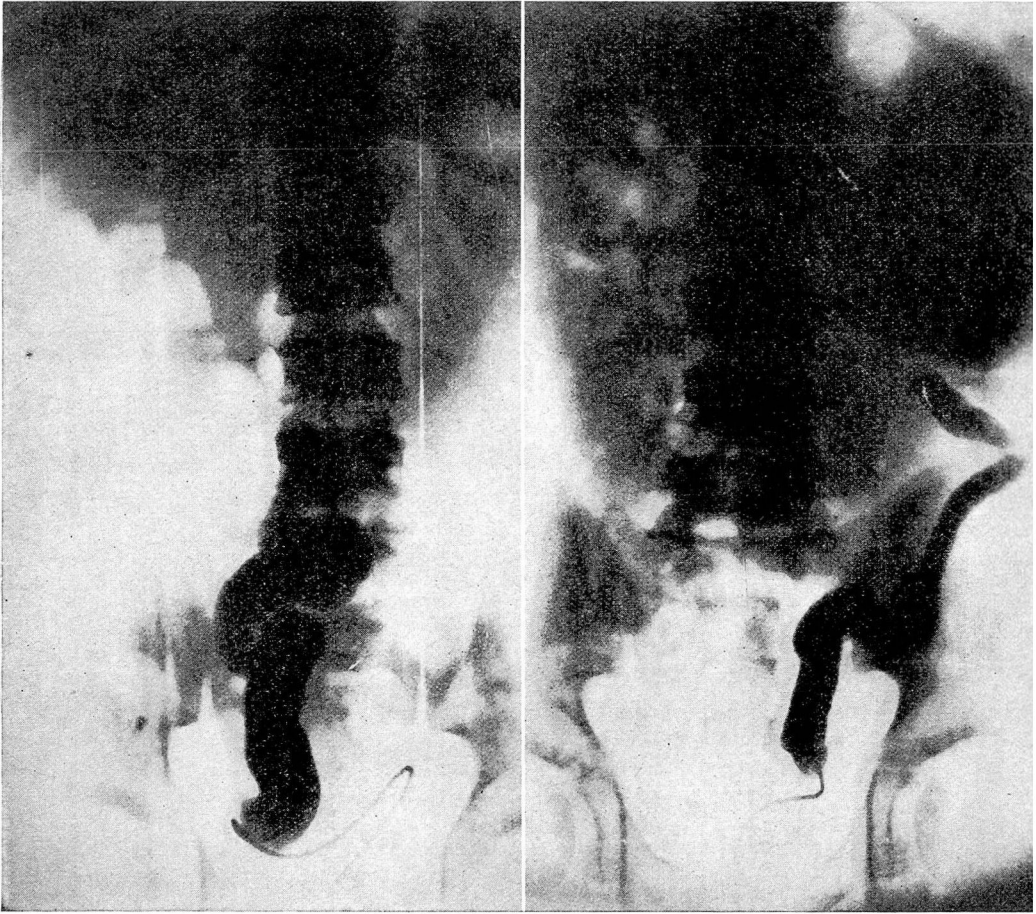


FIG. 9.—The patient was a boy eight years of age who had had recurrent attacks of chills and fever, associated with pyelitis, since he was six months of age. Retrograde pyelogram shows dilatation of the kidney pelvis and ureter with ureterovesical stricture.

When there is a stone in the bladder the diagnosis is sometimes confused by the presence of urinary incontinence and enuresis. Some neurogenic cause of these symptoms is often wrongly suspected and an erroneous diagnosis of cord lesion or spina bifida may be made. The intense dysuria, however, should always suggest the possibility of stone in the bladder. The diagnosis, of course, is made finally by the finding of stone shadows in the plain roentgenogram of the kidneys, ureters, and bladder. Al-



Figs. 10A and 10B.—The patient was a boy fourteen years of age. A (*left*) and B (*right*). Bilateral pyelograms, showing marked hydro-ureter and hydronephrosis (*left*). Obstruction in this case was due to congenital bilateral ureterovesical stricture.

though this diagnostic method is available to practically every practising physician, it is amazing to see how often urinary stone goes unrecognized in children.

With improved knowledge of diet and infant feeding the incidence of stone in children has shown a sharp decrease in those countries where it formerly was quite prevalent. The work of McCarrison, Osborn and Mendel, Higgins, and others, showing that urinary calculi develop in a large proportion of rats fed on a diet deficient in vitamin A, forms the basis of this improved dietary management. Much has been accomplished in the way of prevention of stone in children, but there are unquestionably other factors beside diet which enter into the production of uri-

UROLOGIC PROBLEMS IN CHILDHOOD

nary calculi, and until these are elucidated, we cannot hope that urinary lithiasis can be prevented.

Treatment of urinary stones in children is almost entirely surgical. The type of operation, of course, depends upon the requirements of the individual case. Even in the case of ureteral stone, cystoscopic manipulation is often impossible in children and ureterotomy should be performed at once. The surgical removal of the stone, however, does not discharge the obligation of the urologist and he should then look to prevention of recurrence. It is here that the proper diet and high vitamin A intake achieve great usefulness. These patients should receive a high vitamin, acid-ash type of diet, with the hope of forestalling recurrence of the calculi.

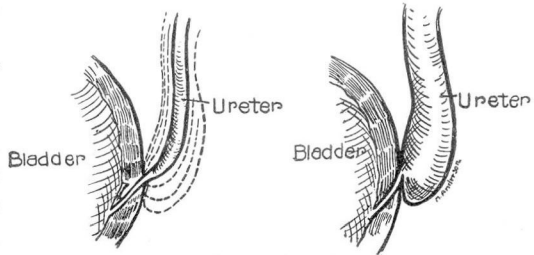


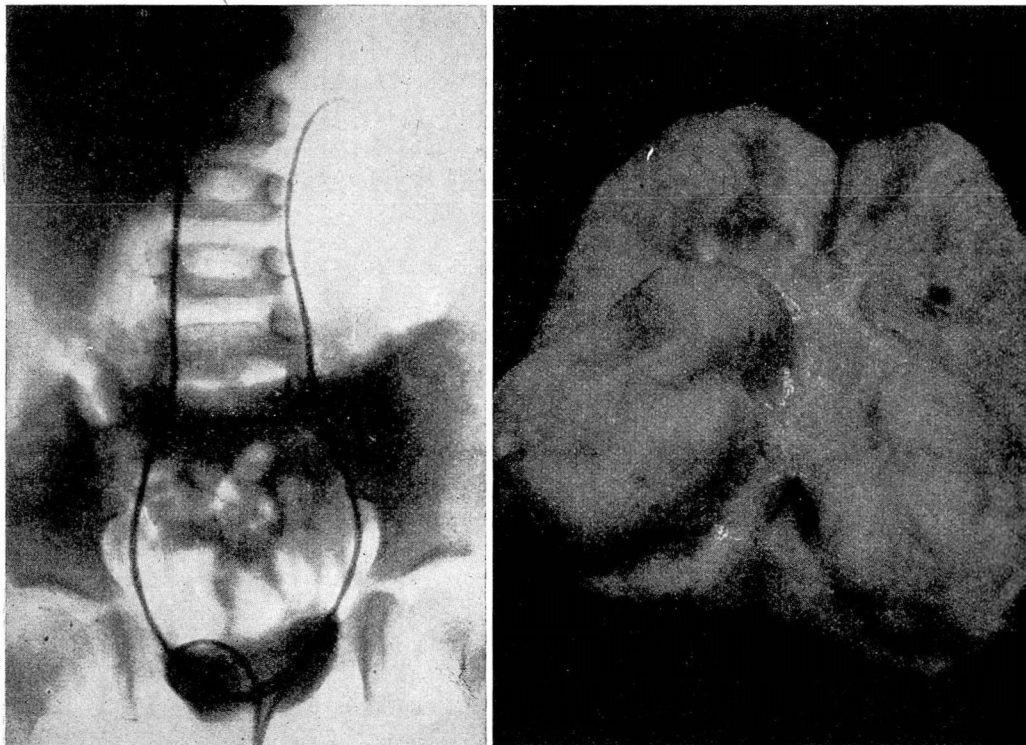
FIG. 11.—Schematic drawing, showing how dilatation of the ureter above a ureterovesical stricture may produce valve-like deformities.

URINARY LESIONS OF CONGENITAL ORIGIN

Hydronephrosis due to aberrant artery is a relatively common disease and its recognition in childhood is a thing earnestly to be desired. Symptoms are not likely to appear early; the youngest patient we have encountered was a six-year-old boy. The incidence of aberrant renal arteries is, of course, much higher than that of cases in which there is a resultant hydronephrosis. It has been estimated that aberrant renal arteries are present in about 20 per cent of all persons. Only 20 per cent of these, however, are at the lower pole and hence capable of producing urinary obstruction.

The embryologic explanation of the occurrence of aberrant vessels is that the kidney in its ascent to its final location receives its blood supply from successive levels, with obliteration of each previous artery. Failure of this process at the final level allows the vessel to remain patent, and if it is situated at the lower pole, is capable of producing urinary obstruction.

It would not appear that ptosis of the kidney or inflammatory stricture must be presumed in order to explain the production of hydronephrosis in these cases. These aberrant arteries are always associated with fibrous peri-ureteral bands, also of congenital origin, and the combination constitutes a fixed point which inter-



FIGS. 12A and 12B.—The patient was a girl three and one-half years of age, who, when she was admitted to the hospital, complained of hematuria, chills, and fever. FIG. 12A (*left*). Retrograde pyelogram shows a filling defect in the lower pole of the right kidney. FIG. 12B (*right*). Photograph of specimen removed showing a Wilms' tumor, involving the lower half of the kidney.

feres with normal peristalsis. This results in gradual dilatation until finally the pelvis becomes redundant over this fixed point and this establishes a vicious cycle which increases the amount of obstruction (Fig. 4).

These cases are overlooked with striking frequency, a failure of recognition which is caused, I believe, by the usual absence of positive urinary findings. In fact, many of our patients with aberrant renal arteries have had perfectly clear urine. In a young person, persistent kidney pain, often most severe in the morning and waning through the day, with tenderness over the affected kidney, should always suggest the presence of this lesion. The pain is usually a dull aching and very seldom appears as colic. Gastro-intestinal symptoms may predominate. There is, of course, no way to make a positive clinical diagnosis without the aid of the roentgen ray. An intravenous urogram should be the first procedure and in almost every instance will yield a positive

diagnosis. Of course, the intravenous urogram is of no value in those cases in which kidney function has been completely destroyed (Figs. 5A, 5B, 6, and 7).

Surgical intervention is demanded when this condition is recognized, and if the patient is seen before extensive kidney destruction has taken place, a conservative operation may be employed. We have preferred the simple division of the artery with or without plication of the dilated pelvis and have had completely satisfactory results by this method. All too often, unfortunately, the process has gone beyond the stage at which the conservative operation will suffice, and nephrectomy is required. In our series of 29 cases, nephrectomy was necessary in 50 per cent of the cases in which operation was performed.

Congenital megalo-ureter is a term applied to a small group of cases with bilateral ureterectasis which occurs in the absence of lower urinary obstruction. These cases must be differentiated from those with congenital posterior urethral valves, hypertrophied verumontanum, etc. That the condition must be congenital is apparent from the very early age at which it has been recognized, together with the fact that it may occur in the absence of any obstructive lesion. The exact mechanism of its production is not clear but it would seem to be due to some congenital neuromuscular failure, with persistence of a fetal type of ureter. It differs from hydro-ureter in obstructive lesions in that the latter is associated with hypertrophy of the ureteral musculature and marked tortuosity, an evidence of hyperperistalsis.

Urinary infection usually is responsible for bringing these patients for medical attention and this may appear when the child is very young. Recurrent infection is the rule, until the true nature of the disease is finally disclosed by a complete urologic investigation. At this time cystoscopy reveals wide patulous ureteral orifices which allow bilateral ureteral reflux. Injection of a pyelographic medium shows widely dilated ureters which, in the later stages, may be somewhat tortuous. Oddly enough, the kidney pelvis often shows only moderate dilatation, not at all comparable to the extent of dilatation in the ureter.

The treatment of this condition constitutes a real problem. Operation is of no avail and the task is to control the infection. Drainage by inlying ureteral catheter may be necessary in the more severe acute phases of infection, and periodic lavage of the kidney pelvis is at times a useful procedure. I have always felt, however, that a minimum of instrumentation should be em-

ployed, and that an attempt should be made to clear up the infection by means of a ketogenic diet and urinary antiseptics.

The prognosis in these cases is very bad and the patients almost never live to reach adulthood. There is a progressive kidney insufficiency, hastened by infection, and uremia is the terminal event (Figs. 8A and 8B).

Ureterovesical stricture presents quite a different problem in that a definite obstruction caused by a congenital stricture at the vesical end of the ureter is the cause of the ureterectasis. These strictures may be unilateral, as in the case presented here (Fig. 9), but bilateral lesions of this type also occur (Figs. 10A and 10B). Cystoscopic examination in these cases reveals a small ureteral orifice in contrast to the large patulous ureter of congenital megaloureter. An attempt at ureteral catheterization may be attended with some difficulty. Similar cases have been described as due to congenital valves in the ureter, and though this possibility must be granted, I have a feeling that many cases in which the condition is attributed to the presence of valves, simply represent the dilatation of the ureter above a stricture which results in a valve-like appearance (Fig. 11). It is true, of course, that this resulting deformity acts to increase the amount of obstruction already present.

Here again, it is the presence of infection which demands medical attention. The infection usually is ushered in by chills and fever, and varying degrees of kidney pain and tenderness are constant accompaniments. The finding of pus in the urine usually results in a diagnosis of pyelitis, but repeated incidents of this type finally bring the patient for thorough urologic study. The intravenous urogram usually suffices to determine the diagnosis. This shows a dilated ureter with constriction at the lower end and usually retention in the kidney an hour after injection of the dye. In some cases there may be delayed function and the differential phenolsulphonaphthalein test shows diminished function on the affected side.

The treatment consists in the surgical relief of the obstruction. Good results may be expected if the process is not too far advanced. The ureter may not return to its normal size, but if drainage is free the patient will be well and no further kidney damage will result. In late neglected cases, ureteronephrectomy may be necessary.

MALIGNANT TUMORS OF THE KIDNEY

Malignant neoplasms of the kidney in children present one of the most depressing problems in urology because there is so little

UROLOGIC PROBLEMS IN CHILDHOOD

we can claim to have accomplished for these poor unfortunates. Fortunately the incidence of these growths is not high, it having been estimated that only one child in 1,600 is affected by a kidney tumor. However, among malignant tumors occurring in children, 20 per cent are in the kidney and among all cases of kidney tumors, the incidence in children is about 12 per cent. At the Cleveland Clinic since 1920 we have records of 32 cases of kidney tumor in children, 16 of which have been verified by operation and pathologic examination.

It is not within the scope of this paper to discuss at length the theories regarding the pathogenesis or the pathology of these tumors, but a few remarks are pertinent to the subject. These growths are all mixed, undifferentiated tumors arising from embryonic tissue, and are characterized by very rapid growth. They present a varied pathologic picture and any one of a variety of forms may occur, depending upon the type of tissue which predominates. It is truly a problem of survival of the fittest and the strongest and most rapidly growing tissue elements take the field. This explains the many pathologic names applied to these tumors, but clinically they are a single entity, well known in their behavior, and may, from our standpoint, quite properly be grouped under one term — malignant kidney tumors of childhood.

These growths occur in very young children and have even been reported in fetuses and newborn infants. The vast majority make their appearance before the fifth year of life; some collected series show an incidence as high as 98 per cent, but in our group of cases only 70.8 per cent occurred in children under five years of age (Figs. 12A and 12B).

The presenting symptom or complaint is usually an abdominal tumor which has appeared rather suddenly and has grown rapidly. The longest history we obtained was of six months' duration and this patient had a very large inoperable tumor. Chills and fever are not uncommon and pain is a frequent complaint. Hematuria is a relatively infrequent symptom and occurred in only two of our cases.

The diagnosis usually offers no difficulty when one considers that about 90 per cent of the patients present themselves with a palpable tumor mass in the kidney region. Kidney tumor is by far the most common cause of a large tumor mass in a child. In the remaining 10 per cent of cases, hematuria, kidney pain, and the symptoms of urinary infection should direct one's attention to the urinary tract and further investigation and pyelograms disclose the true nature of the disease.

WILLIAM J. ENGEL

The results of treatment of these tumors must impress all who have seen any number of these cases as very discouraging. No matter what treatment is adopted, that is, operation, irradiation, or both, the outcome is nearly always fatal and this usually within a very short time. It is truly remarkable to see how some of these large tumors melt under irradiation therapy like fat before the fire, but this, unfortunately, does not improve the prognosis, for they recur rapidly and become more radioresistant.