

THE DIFFERENTIAL DIAGNOSIS OF CORONARY ARTERY DISEASE

Diseases Which Simulate Angina Pectoris and Coronary Thrombosis

A. CARLTON ERNSTENE, M.D.

During the past 15 years, there has been a progressive increase in the frequency with which the diagnosis of coronary thrombosis or angina pectoris has been made. This increase has resulted in part from an absolute increase in the incidence of coronary artery disease and in part from widespread diffusion of knowledge concerning its clinical features. In the great majority of cases, the presence of angina pectoris or coronary thrombosis is correctly recognized, but as a result of the popularity of these diagnoses, other diseases with similar symptoms undoubtedly are being included at times under the same classifications. Although such errors are not common, they are of importance because of their bearing upon prognosis and treatment. It is the purpose of this communication to review certain recent experiences in which other conditions were confused with or closely simulated coronary artery disease and to point out the significant features in the history and clinical findings upon which a correct diagnosis was, or might have been, established.

UPPER ABDOMINAL DISEASE

Early writers^{1,2} on coronary thrombosis directed attention to the fact that the disease might closely simulate acute surgical conditions in the upper abdomen, and the possibility of erroneously attributing the symptoms of coronary occlusion to upper abdominal disease has since been emphasized repeatedly. More recently, a few observers have pointed out the possibility that errors may be made in the reverse direction and have reported cases in which symptoms due to gall-bladder disease or perforated peptic ulcer suggested coronary artery disease.^{3,4,5} In the first of the two following case reports, symptoms due to cholelithiasis were attributed originally to coronary occlusion, while in the second, an esophageal hiatus hernia caused symptoms simulating angina pectoris.

Case 1. *Cholelithiasis with Pain Suggesting Coronary Thrombosis.*

A white, single woman, aged 35 years, was referred to the Clinic on April 11, 1935, with a diagnosis of coronary thrombosis. Four days earlier, severe pain had developed suddenly in the interscapular region while the patient was working at her desk. This pain was followed almost immediately by agonizing burning pain in the lower substernal region which radiated upward toward both shoulders and into the epigastrium and both upper abdominal quadrants. The pain was of such severity that the patient was unable to remain quiet. Walking and change in position had no effect. There was moderate dyspnea, and the patient noted that any attempt to take a deep breath increased the dis-

THE DIFFERENTIAL DIAGNOSIS OF CORONARY ARTERY DISEASE

comfort. Nausea developed soon after the onset, and the patient induced vomiting on three occasions but without relief. After four hours, she called her physician, who administered morphine. The pain subsided gradually during the next two hours, but a feeling of soreness was still present over the lower chest and epigastrium four days later. No jaundice had been noted, and the urine had remained of normal color. The past history was irrelevant except for the fact that during the preceding six months there had been three attacks of moderate epigastric pain associated with pain in the interscapular area. On each occasion, the symptoms had developed about one hour after eating and had been relieved in about ten minutes by taking soda and belching.

Physical examination revealed a moderately obese individual with no cyanosis or jaundice. The pupils reacted normally. The heart was not enlarged, and its rhythm and rate were normal. A faint systolic murmur was heard over the apex. There was no friction rub, and the heart sounds were of good quality. The blood pressure was 120 mm. systolic and 82 mm. diastolic. The lungs were clear. Slight tenderness was present in the epigastrium and below the costal margin in the right anterior axillary line. There was no peripheral edema. The temperature by mouth was 99.4° F.

The leucocyte count was 10,500 per c.mm. The urine was normal. The icteric index was 8. An electrocardiogram with a precordial lead in addition to the three conventional leads showed no abnormalities. Roentgenograms of the chest revealed no evidence of pathology in the heart, lungs or aorta.

Because of the patient's age, the occurrences of pain in the interscapular region, the normal electrocardiographic findings and the history of earlier, milder attacks not suggestive of coronary disease, it was concluded that the symptoms had not resulted from coronary thrombosis. Cholecystograms were advised. The gallbladder was not visualized but a single large calcium type stone was seen in the gallbladder area (Fig. 1).

Cholecystectomy was performed on May 1, 1935. The gallbladder contained a single spherical stone, 1.7 cm. in diameter. The patient has had no recurrence of symptoms.

Case 2. *Esophageal Hiatus Hernia Simulating Angina Pectoris.*
A white, single woman, aged 72 years, had experienced a sensation of fulness and pressure high in the epigastrium at irregular intervals for one year. The discomfort usually developed after the evening meal and was relieved in 20 to 30 minutes by drinking hot water and belching. Shortly after the first appearance of these symptoms, the patient began to experience attacks of numbness and severe aching pain over the top of the left shoulder, extending down the left arm for a variable distance. These symptoms likewise developed in the evening, but at first, the patient did not associate them with the abdominal discomfort. After a few weeks, however, she noted that the shoulder and arm pain always was accompanied by epigastric distress, although at times epigastric distress occurred without other symptoms. As in the case of the epigastric discomfort, drinking hot water and belching gave relief from the shoulder and arm pain. Neither type of pain was precipitated by exertion, although on a few occasions all symptoms had been brought on by bending forward acutely. For three or four years, the patient had experienced moderate dyspnea on walking rapidly, and six months before examination, she had been told her blood pressure was elevated.

Physical examination revealed a moderately obese individual. The left border of cardiac dullness was 1 cm. beyond the mid-clavicular line in the

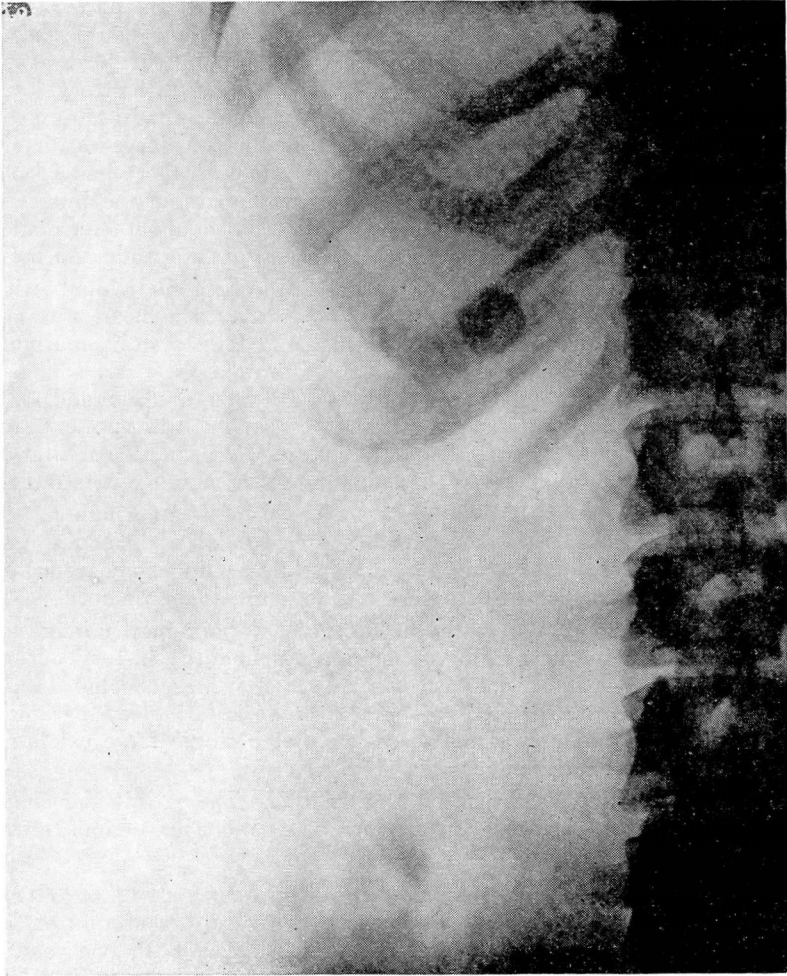

FIGURE 1, CASE 1.—Large gall stone in non-functioning gallbladder.

fifth intercostal space. The aortic second sound was moderately accentuated, and a short systolic murmur was heard over the apex and aortic area. The rate and rhythm were normal. There was moderate, diffuse thickening of the peripheral arteries, and the blood pressure was 160 mm. systolic and 84 mm. diastolic. The percussion note was dull over the base of the left lung up almost to the angle of the scapula, and the breath sounds and voice transmission were suppressed over this area. A moderate number of medium moist râles were heard over the base of both lungs. Abdominal examination was negative. There was no peripheral edema.

Examination of the blood and urine gave normal results. An electrocardiogram revealed nothing abnormal except for moderate left axis deviation.

Although the type of pain was suggestive of angina pectoris, there were certain features in the symptomatology which argued against the acceptance of

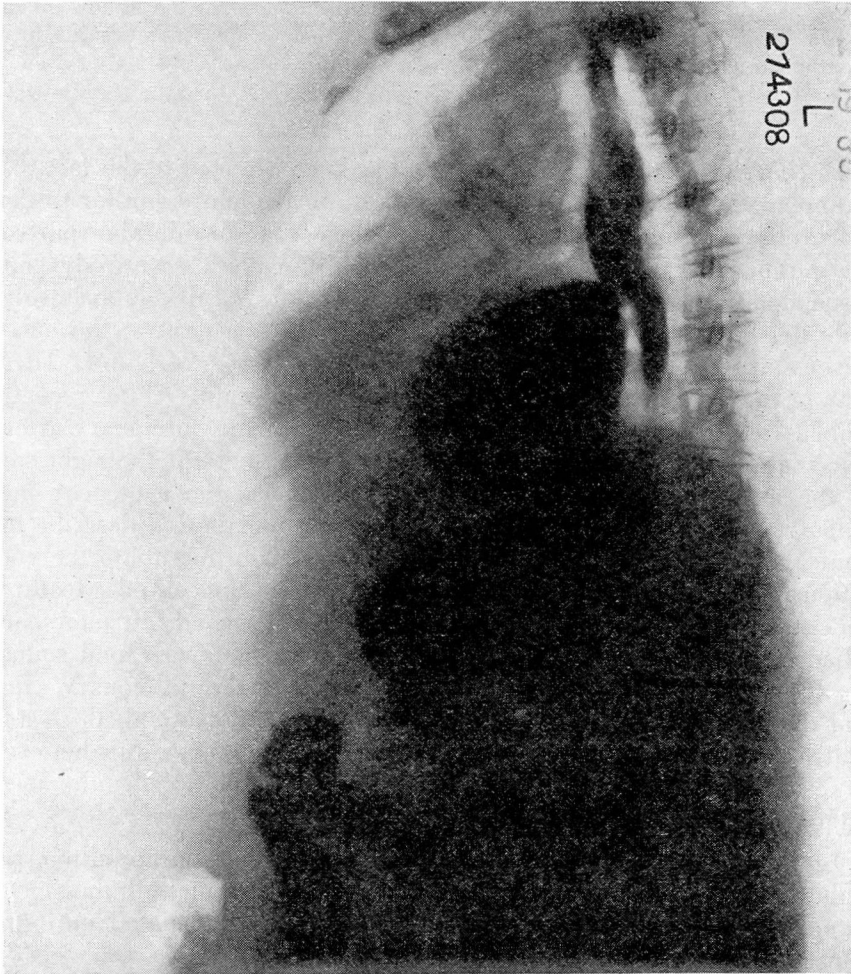


FIGURE 2, CASE 2.—Esophageal hiatus hernia with approximately two-thirds of stomach lying above the diaphragm. Lateral view.

this diagnosis. The most important of these were the lack of relationship between the attacks and exertion, the prompt relief experienced after drinking hot water and belching, and the fact that although the abdominal pain had been situated high in the epigastrium, there had at no time been radiation to the substernal region. It therefore was decided to investigate the gastro-intestinal tract. Roentgenologic examination after the administration of a barium meal revealed a large diaphragmatic hernia of the esophageal hiatus type with approximately two-thirds of the stomach lying above the diaphragm (Fig. 2). The herniation of the stomach was constant with the patient in all positions, and there was no retention of barium at the end of four hours. The esophagus appeared to be of normal length. Undoubtedly the epigastric pain resulted from distention by gas of the portion of the stomach lying above the diaphragm, while the pain over the left shoulder and in the left arm was due to irritation

of the central tendon of the diaphragm. The occurrence of the attacks in the evening probably was accounted for by the fact that the patient's evening meal was the largest of the day.

PULMONARY EMBOLISM

During the past few years attention has been directed to the fact that pulmonary embolism may give rise to a clinical picture similar to that of coronary thrombosis. Sudden occlusion of a considerable part of the pulmonary circulation characteristically causes severe dyspnea associated with retrosternal oppression and the rapid development of a state of shock. There may or may not be pleural pain at the onset. Fever and leucocytosis usually appear within the first 24 hours. There may or may not be blood-tinged sputum. McGinn and White⁶ recently emphasized the fact that sudden occlusion of a large pulmonary artery causes prompt dilatation and failure of the chambers of the right side of the heart and termed this cardiac disturbance the acute cor pulmonale. They report 9 cases of acute cor pulmonale and describe the clinical and electrocardiographic features which differentiate the condition from coronary thrombosis. The most important clinical features consist of an increased pulsation palpable in the second left interspace adjacent to the sternum, accentuation of the pulmonary second sound, the frequent occurrence of a gallop rhythm over the pulmonary area, and the occasional presence of a friction rub in the second, third and fourth interspaces adjacent to the sternum. The friction rub is believed to result from irritation of the pericardium by the dilated pulmonary artery and right ventricle.

In the case which follows, the symptoms, although due to pulmonary embolism, were highly suggestive of coronary occlusion, and the significance of certain of the physical signs was not appreciated until the appearance of the report of McGinn and White.⁶

Case 3. *Pulmonary Embolism Simulating Coronary Thrombosis.*
A white man, aged 65 years, who was known to have had chronic nonspecific prostatitis for several years, was admitted to the hospital on April 21, 1933, because of pain in the left lower chest posteriorly. The pain was increased by deep breathing and was accompanied by dyspnea and an unproductive cough. The symptoms had developed suddenly two days earlier.

Physical examination revealed dullness over the base of the left lung together with a faint pleural friction. The heart was not enlarged; its rhythm was regular, and no murmurs were heard. The aortic second sound was louder than the pulmonary second. The temperature by mouth was 100.4°F., the pulse rate, 96 per minute, and the blood pressure, 126 mm. systolic and 70 mm. diastolic. Roentgenologic examination of the chest showed a large area of consolidation in the lower lobe of the left lung. A diagnosis of pulmonary infarction was made. On the second day after admission, the patient began to raise blood-streaked sputum, and on the following day, he complained of pain over the inner aspect of the left thigh, approximately along the course

THE DIFFERENTIAL DIAGNOSIS OF CORONARY ARTERY DISEASE

of the great saphenous vein. It was concluded, therefore, that the patient had pelvic thrombophlebitis with extension to the femoral and great saphenous veins on the left. The pelvic thrombophlebitis presumably was the source of the pulmonary embolus.

The patient improved gradually until the thirteenth day after admission. At that time, after three days of normal temperature, he experienced sudden, constricting pain in the retrosternal region and over the left anterior chest. The pain was accompanied by dyspnea, orthopnea, restlessness and great apprehension. The pulse rate increased to 116 per minute and the blood pressure dropped to 106 mm. systolic and 60 mm. diastolic. The temperature rose to 101° F. within six hours and during the following four days ranged between 100° and 103° F. On the day after the appearance of these symptoms, examination revealed accentuation of the pulmonary second sound and a pericardial friction rub over the third and fourth intercostal spaces adjacent to the sternum. A few fine râles were present over the lung bases. The patient's color was of a dusky ashen hue. The leucocyte count was 14,100 per c.mm. The sputum was streaked with blood.

A diagnosis of extensive pulmonary embolism was made, and undoubtedly, this condition resulted in the development of the acute cor pulmonale of McGinn and White.⁶

The patient's condition was extremely serious for nearly 48 hours. He was kept in an oxygen tent, and morphine was administered subcutaneously on several occasions. The friction rub persisted for approximately 36 hours. The subsequent clinical course was uneventful, and the patient was discharged from the hospital six weeks later.

DISSECTING ANEURYSM OF THE AORTA

Dissecting aneurysm of the aorta gives rise to a symptom complex which closely resembles that of acute coronary occlusion. The condition is characterized by the sudden onset of severe pain in the anterior chest, often radiating to the back and legs, and usually described by the patient as crushing or tearing in quality. The pain usually lasts for 48 hours or longer and frequently is present to a greater or lesser degree until death occurs. At the onset, repeated injections of morphine give only partial and gradual relief. Fever and leucocytosis usually develop within 24 hours of the onset.

White, Badger and Castleman⁷ recently have discussed the differential diagnosis of dissecting aortic aneurysm and coronary thrombosis. They direct attention to the fact that in dissecting aneurysm, the severe pain is abrupt in onset in contrast to its more gradual evolution in coronary occlusion. The frequent radiation of the pain to the back and legs also is of diagnostic importance. Particular emphasis is placed, however, upon the maintenance of hypertension throughout the acute illness, the lack of diminution in the quality of the heart sounds and the absence of coronary T-waves in repeated electrocardiograms.

The following case, in which an erroneous diagnosis of coronary thrombosis was made, illustrates how closely dissecting aortic aneurysm may simulate coronary occlusion.

Case 4. *Essential Hypertension; Syphilitic Aortitis with Aneurysm of the Aorta; Dissecting Aneurysm of the Aorta with Rupture into the Left Pleural Cavity.* The patient, a white man, aged 58 years, had known of the presence of hypertension for six years and for the same length of time had been receiving conservative treatment for syphilis. On September 14, 1934, three days before admission to the hospital, severe crushing pain had developed suddenly in the lower left chest anteriorly. The pain did not radiate, and in spite of repeated doses of morphine sulphate, it was not entirely gone at the time the patient entered the hospital. There had been no definite dyspnea, but the patient had vomited several times during the first 12 hours of the illness and had been mentally confused from the onset.

At the time of admission to the hospital, the temperature by mouth was 100.4° F., the pulse rate, 100 per minute, and the blood pressure, 190 mm. systolic and 110 mm. diastolic. There was no cyanosis. The pupils reacted normally. The left border of cardiac dullness was 12 cm. from the midsternum in the sixth intercostal space. No increased dullness could be made out over the base of the heart. The cardiac rhythm was regular, and the sounds were of good quality. The aortic second sound was greater than the pulmonary second. A moderate systolic murmur was present over the apex. There was advanced sclerosis of the peripheral arteries. The lungs were clear. Abdominal examination gave normal findings. The tendon reflexes were brisk and equal.

The leucocyte count was 11,400 per c.mm. The urine contained a heavy trace of albumin, and microscopic examination of the sediment revealed a few white blood cells and an occasional hyaline cast. The Wassermann reaction of the blood was 4 plus. Electrocardiograms taken on the day of admission and two days later showed slight inversion of the T-wave in Lead I and moderate left axis deviation.

Shortly after the patient entered the hospital, the pain increased greatly in severity for a period of two hours. Gradual relief was obtained with one-fourth grain of morphine sulphate subcutaneously. On the evening of the fourth day after admission, severe pain again developed suddenly in the left lower chest and was accompanied by pallor, profuse perspiration and a rise in pulse rate to 124 per minute. One-fourth grain of morphine sulphate was given subcutaneously without relief, but after a similar dose 20 minutes later, the patient gradually became more comfortable. On the following day, he remained free from pain, but that night, shortly after midnight, he awakened restless and confused, and while attempting to get out of bed, suddenly died.

During the first three days in the hospital, the blood pressure ranged between 190 mm. and 210 mm. systolic and 110 mm. and 136 mm. diastolic. It then dropped rapidly and on the day before death, was 146 mm. systolic and 90 mm. diastolic. The leucocyte count reached a maximum of 12,600 on the second day after admission and then decreased to 8,200 on the fourth day after admission.

Necropsy. When the thorax was opened, the left lung was found to be compressed by a large postmortem clot which weighed 1,500 grams. About 300 cc.

THE DIFFERENTIAL DIAGNOSIS OF CORONARY ARTERY DISEASE

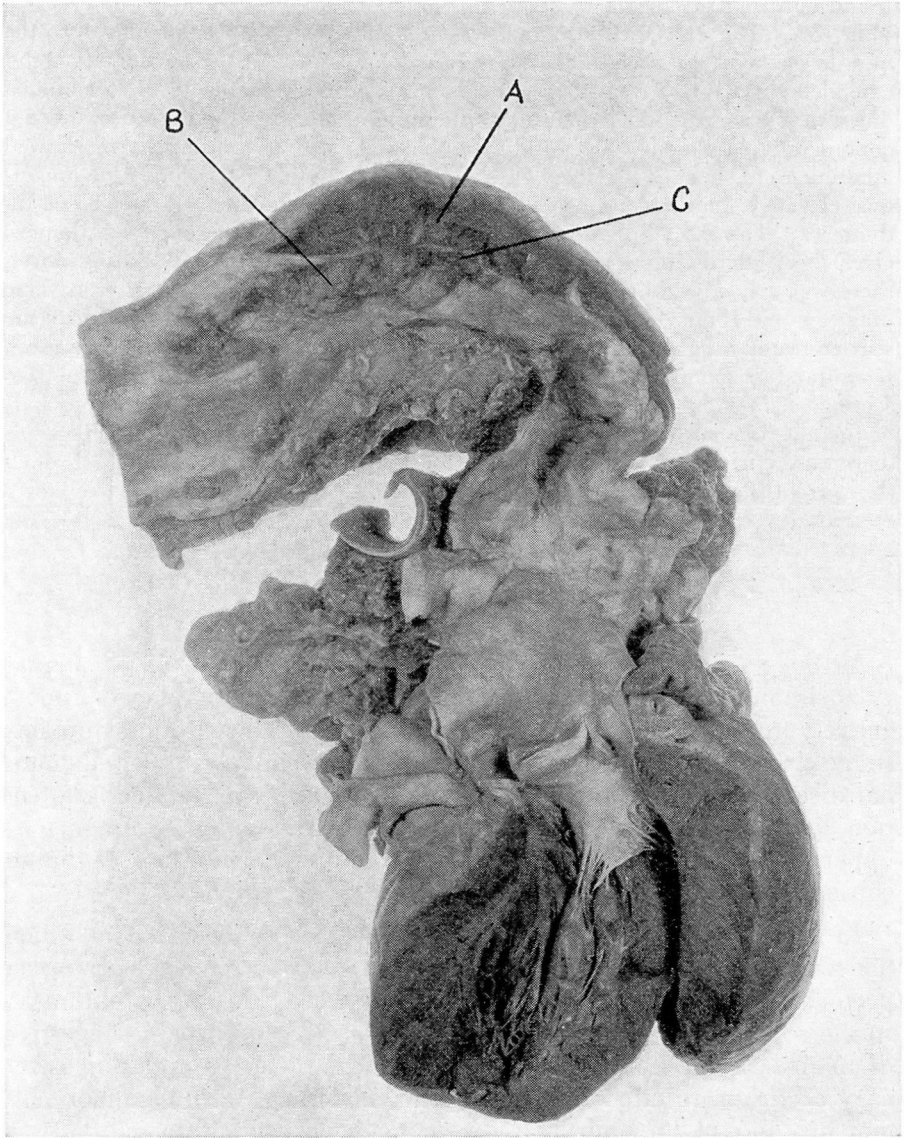


FIGURE 3, CASE 4.—Dissecting aneurysm of the aorta. The dissecting aneurysm containing the blood clot is shown at A and the aneurysmal dilatation at B. The laceration in the intima cannot be seen but is situated at C.

of unclotted blood also were present. The arch and upper portion of the descending aorta appeared to be greatly dilated. The pericardium was normal. The heart weighed 570 grams, and the walls of both ventricles were increased in thickness. The coronary arteries were patent throughout.

A. CARLTON ERNSTENE

Upon opening the aorta, a large blood clot, 1 to 3 cm. in thickness, was found splitting the media at about the junction of the inner and outer halves (Fig. 3). The clot was firm but was not adherent. It began above at the middle of the aortic arch, 8 cm. above the commissures of the aortic valve, and extended distally for a distance of 22 cm. Splitting of the media continued downward a short distance below the diaphragm, but this lower portion did not contain clotted blood. The intima of the arch and descending aorta showed atheromatous changes together with patchy, longitudinal striations and numerous elevated, indurated areas ranging from a few millimeters to 2 cm. in diameter. The ascending aorta showed only a few small atheromatous plaques. Over the postero-lateral aspect of the upper portion of the descending aorta, there was a localized aneurysmal dilatation measuring 3.5 cm. in its transverse diameter and 9 cm. longitudinally. The intima in this area presented extreme scarring and roughening, and at the upper margin of the area there was an irregular horizontal laceration, 2 cm. long, which communicated with the dissecting aneurysm. Externally, the left lung was adherent over the upper half of the aneurysmal dilatation, and just below the lower limit of these adhesions there was an irregular, horizontal laceration, 1.5 cm. long, which extended through the adventitia and communicated with the dissecting aneurysm. The aorta measured 7 cm. in internal circumference immediately above and below the aneurysmal dilatation, and 10 cm. at the midportion of the aneurysm.

SUMMARY

In the past, in discussions of the differential diagnosis of angina pectoris and coronary thrombosis, emphasis has been placed almost entirely upon the fact that these conditions might give rise to symptoms suggestive of some other pathologic state, particularly upper abdominal disease. Only of late have a few reports appeared directing attention to the possibility of erroneously interpreting the symptoms of upper abdominal disease and certain intrathoracic conditions as due to coronary artery disease.

In the present communication, four cases are summarized in which the symptoms closely resembled those of coronary thrombosis or angina pectoris. In the first case the symptoms were due to cholelithiasis. In the second, a large esophageal hiatus hernia caused pain suggestive of angina pectoris. In the third, a clinical picture simulating coronary occlusion resulted from pulmonary embolism with acute cor pulmonale, and in the fourth, a dissecting aneurysm of the aorta was mistakenly diagnosed coronary thrombosis. The cases illustrate the diagnostic significance of negative electrocardiographic findings and also indicate the importance of detailed analysis of the patient's symptoms and physical signs. In the future, diaphragmatic hernia, upper abdominal disease, dissecting aneurysm of the aorta and pulmonary embolism with acute cor pulmonale should be excluded before a diagnosis of angina pectoris or coronary thrombosis is made in patients presenting features not typical of coronary artery disease.

THE DIFFERENTIAL DIAGNOSIS OF CORONARY ARTERY DISEASE

REFERENCES

1. Herrick, J. B.: Clinical features of sudden obstruction of the coronary arteries, J.A.M.A., 59:2015-2020, 1912.
2. Levine, S. A. and Tranter, C. L.: Infarction of the heart simulating acute surgical abdominal conditions, Am. J. M. Sc., 155:57-66, 1918.
3. Robey, W. H.: The differentiation between gallbladder disease and coronary sclerosis in the middle aged, M. Clinics N. America, 8:1709-1718, May, 1925.
4. Barker, P. S., Wilson, F. N. and Coller, F. A.: Abdominal disease simulating coronary occlusion, Am. J. M. Sc., 188:219-224, August, 1934.
5. Hamman, L.: Remarks on the diagnosis of coronary occlusion, Ann. Int. Med., 8:417-431, October, 1934.
6. McGinn, S. and White, P. D.: Acute cor pulmonale resulting from pulmonary embolism; its clinical recognition, J.A.M.A., 104:1473-1480, April, 1935.
7. White, P. D., Badger, T. L. and Castleman, B.: Dissecting aortic aneurysm wrongly diagnosed coronary thrombosis, J.A.M.A., 103:1135-1139, October 13, 1934.