

# **SURGERY FOR MITRAL STENOSIS**

## **Part 1**

**F. MASON SONES, M.D.**

**Department of Cardiovascular Disease**

**DONALD B. EFFLER, M.D. and CHARLES S. BALLINGER, M.D.**

**Department of Thoracic Surgery**

**T**HE purpose of this report is to summarize our experience to date with the surgical treatment of mitral stenosis. Thirty-two patients have been operated upon and have been followed for 2 to 20 months after operation. Two patients died during the immediate postoperative period and a third, three months after operation. The remaining 29 have survived, and all but 1 of 17 who have been observed for longer than six months have shown definite functional improvement.

## **Pathology**

Functionally significant mitral stenosis is the pathologic end result of rheumatic mitral valvulitis and its subsequent healing. Its development requires many months. During the initial attack of rheumatic carditis, the clinical picture is dominated by the effects of myocardial damage, and mitral stenosis plays no role in altering circulatory dynamics. The first clinical manifestation of mitral valvulitis is the appearance of the apical systolic murmur of mitral insufficiency. In certain patients the auscultatory findings of "pure" mitral stenosis gradually evolve. In others, the features are those of uncomplicated mitral insufficiency, but the largest number present evidence of combined stenosis and insufficiency. With gradual healing of active myocardial lesions, the more stable pattern of chronic valvular disease becomes evident. These patients with fixed valve lesions are our primary concern.

Obstruction to blood flow across a narrowed mitral valve causes an elevation of pressure in the left auricle and the pulmonary veins, which is accompanied by a rise in pulmonary artery pressure. In many instances, the elevation of pulmonary artery pressure is simply the mechanical result of mitral valve disease. In other patients there is an associated, and often greater, obstruction to blood flow through the pulmonary arteriolar bed. Specimens taken for lung biopsy at the time of commissurotomy in the latter group of patients show medial hypertrophy and intimal sclerosis in the pulmonary arterioles. The physiologic objective of mitral commissurotomy is relief of pulmonary hypertension. The functional end result of surgical intervention will be determined

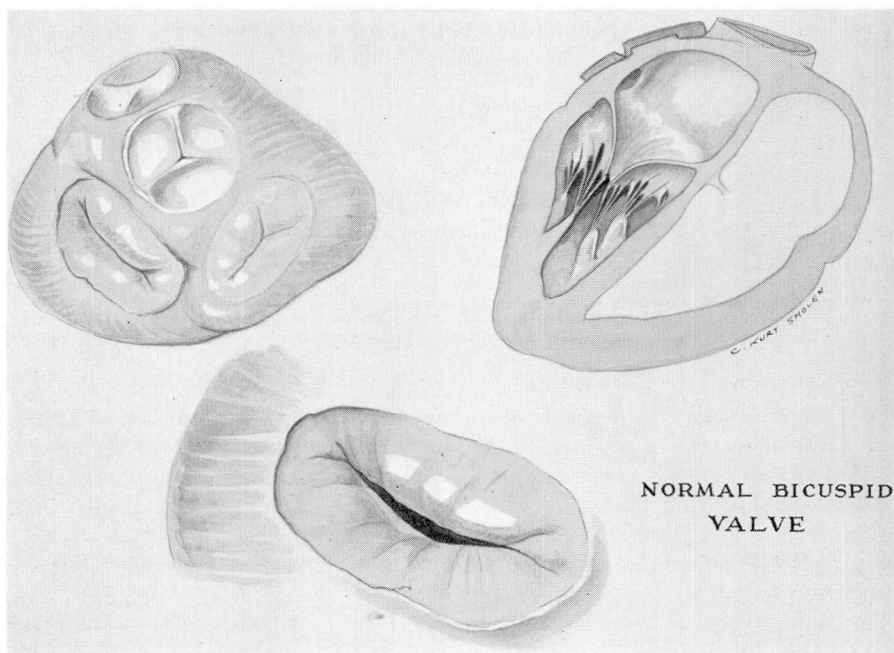


FIG. 1. Diagrammatic illustration showing topography and normal relations of mitral or bicuspid valve in the human heart.

by the degree to which these pulmonary vascular changes prove to be reversible, as well as by the increase in the size of the mitral valve orifice obtained.

### Classification of Mitral Stenosis

On the basis of clinical and laboratory findings, patients with mitral stenosis may be divided into four functional groups.

**Group I. Asymptomatic Patients.** These are persons with the auscultatory findings of mitral stenosis who are able to carry on normal activities without symptoms. There is no significant cardiac enlargement. There are no specific electrocardiographic changes.

**Group II. Patients with Symptoms Who Have Not Been in Congestive Failure.** These are divided into two sub-groups.

(a) **Left auricular stress.** These people are comfortable in the absence of physical or psychic stress. Unusual physical or emotional strain causes marked dyspnea, and occasionally attacks of pulmonary edema. Left auricular enlargement is always present, but over-all heart size may be within normal limits.

(b) **Pulmonary hypertension.** Fatigue and dyspnea are present at ordinary levels of activity. Orthopnea in varying degrees of severity is experienced from time to time, and hemoptysis is not uncommon. The heart size is increased

because of left auricular and right ventricular enlargement. Electrocardiographic evidence of right bundle branch block or right ventricular hypertrophy is usually present.

**Group III. Patients in Congestive Failure.** These show the signs and symptoms of the Group II patients and also present systemic congestive manifestations which can be controlled by proper treatment.

**Group IV. Patients with Intractable Congestive Heart Failure.** The manifestations of congestive failure persist in spite of all measures of therapy.

### Selection of Patients

Patients are selected for operation primarily on the basis of clinical evaluation of the disease. Cardiac catheterization has been routinely employed preoperatively. This has made possible objective measurement of the severity of abnormal resistance to blood flow through the pulmonary arteriolar bed and across the mitral valve orifice. It has been of value in dissociating subjective manifestations which are due to psychic factors from those due to organic disease. Similar studies made during the 3 to 12 postoperative months will be reported later.

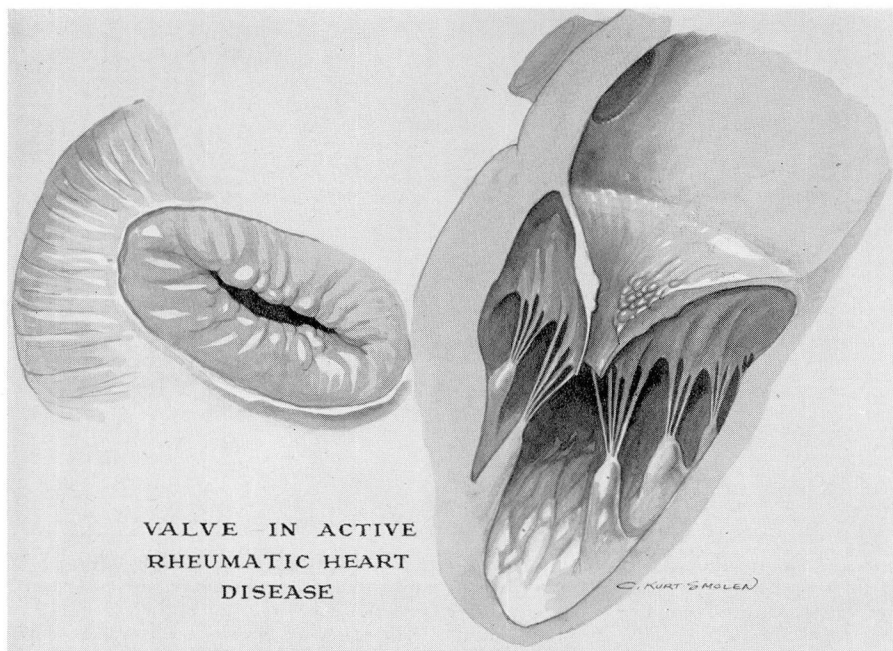


FIG. 2. Diagrammatic concept of mitral valve in active rheumatic heart disease. Valve edges become thickened by verrucous lesions associated with endocarditis. During this phase of the disease valve remains mechanically competent although the patient may be seriously ill.



At the present time operation is not advised in Group I patients. There is as yet no evidence that the prognoses of patients in this group are improved by commissurotomy. In Group IV patients, surgery is not recommended. The irreversible myocardial damage and secondary pulmonary vascular changes in this group cannot be significantly improved by surgical alteration of the mitral valve. Unless specific contraindications exist, all patients in Groups II and III are considered to be candidates for operation. The ideal candidates for operation are those in Group II.

### Contraindications

Contraindications to mitral commissurotomy which seem to have been well established are listed below in the order of importance. Further experience may eliminate some of these and add others.

- (1) Intractable congestive heart failure.
- (2) Active rheumatic carditis.

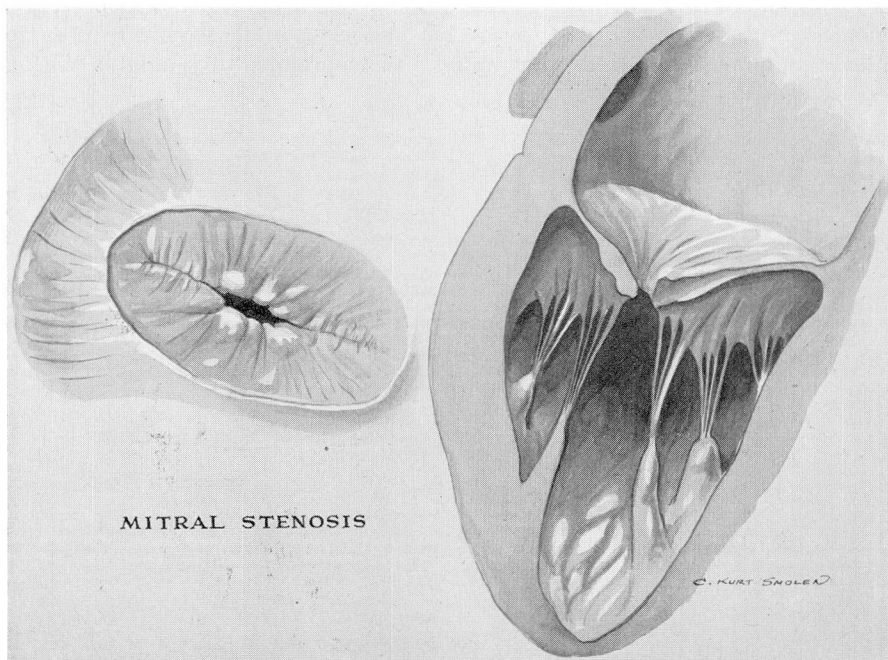


FIG. 3. Diagrammatic conception of valve in pure mitral stenosis, the so-called "buttonhole" or "fish mouth" valve classically described in mitral stenosis. Commissures are obliterated by avascular fibrous symphysis with central fixed lumen. On cross section of the valve observe that thickening and rigidity of valve is primarily in region of outflow tract. Where valve inserts on the ventricular and atrial wall there appears to be little residual disease. In this portion valve may be unusually thin and flexible.

NOTE: The artist did not attempt to depict the shortening and thickening of the chorda tendineae which usually accompany mitral stenosis.

- (3) Functionally significant aortic valve disease or mitral insufficiency.
- (4) Active bacterial endocarditis or systemic infections.
- (5) Recent (within six to eight weeks) systemic or pulmonary embolism.
- (6) Coronary heart disease with angina pectoris or previous myocardial infarction.
- (7) Co-existing disease which limits a reasonable estimate of life expectancy to less than five years.

Selection of the proper time for operation may be a difficult problem. It is believed that a period of two years should elapse after the last episode of rheumatic activity. Since the primary concern is the ultimate fate of the valve after surgery, any factor which favors further deformity should be eliminated. Active inflammation of the valve at the time of surgery may stimulate re-approximation of the cusps, whereas this is not anticipated in the avascular, fibrous stenosis of old rheumatic heart disease. In addition to the evaluation of rheumatic activity the factors of recent congestive failure and embolic accidents influence the timing of commissurotomy. Operation is an elective procedure and is never regarded as an emergency measure. Thorough control of all congestive manifestations, eradication of infection, and the maintenance of a stable cardiac rhythm are essential in preoperative preparation. The presence of auricular fibrillation, if the ventricular rate is controlled at resting rates of 70 to 80 beats per minute, does not add to the hazard of surgery. Digitalis is used to control the ventricular rate in the presence of auricular fibrillation and in the presence of congestive heart failure. It is not indicated preoperatively in Class II patients who have normal cardiac rhythm. The use of atropine before induction of anesthesia is contraindicated.

### Anesthesia

Safe anesthesia for surgery in mitral stenosis requires a technic which will give the most analgesia and amnesia for the least amount of anesthetic agent. The method employed at present utilizes endotracheal gas and oxygen under positive pressure. This is supplemented by local procaine (1 per cent) in the chest wall and intravenous procaine (2 per cent) given intermittently throughout the operation. Intravenous procaine has a double effect; it assists in control of cardiac arrhythmias by reducing the myocardial irritability, and it seems to enhance the effectiveness of the inhalation agents during light anesthesia.

The importance of positive pressure anesthesia deserves emphasis. Oxygen is the key to safe cardiac surgery. Positive pressure oxygen must be maintained in high levels of concentration from the period of induction throughout the operation, and until reaction has been complete. The lungs are kept expanded at all times even though this may make forcible retraction necessary during the operative procedure.

Pentothal sodium is employed only in the induction. The induction is performed in the patient's room and not in the operating pavillion. Apprehen-

sion in the patient with mitral stenosis will result in tachycardia and a consequent increase in pulmonary hypertension: When intubation has been effected and the patient is converted to the inhalation agents, little or no pentothal is required. With experience there has been a tendency to omit ether. In the presence of severe pulmonary hypertension and its secondary changes in the tracheobronchial tree, ether is a tracheobronchial irritant, and greatly increases the postoperative pulmonary secretions. The patient with mitral stenosis may be carried on an unbelievably light plane of inhalation anesthesia without jeopardizing the surgeon's exposure. The majority of patients will respond to auditory stimuli during all phases of the operation, including the time of the actual commissurotomy. The patients are usually wide awake at the time they are removed from the operating table to the recovery room.

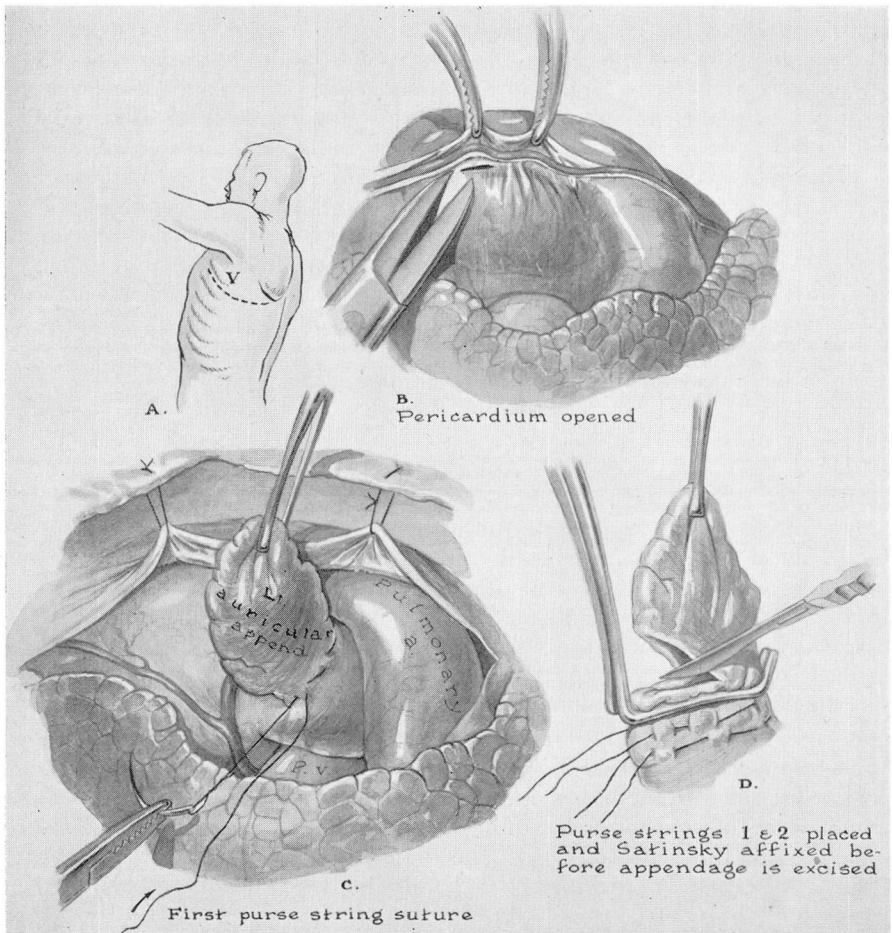


FIG. 4. Technic of operation is illustrated by diagram. (A), (B), (C), and (D) illustrate steps employed in performing auricular appendectomy.



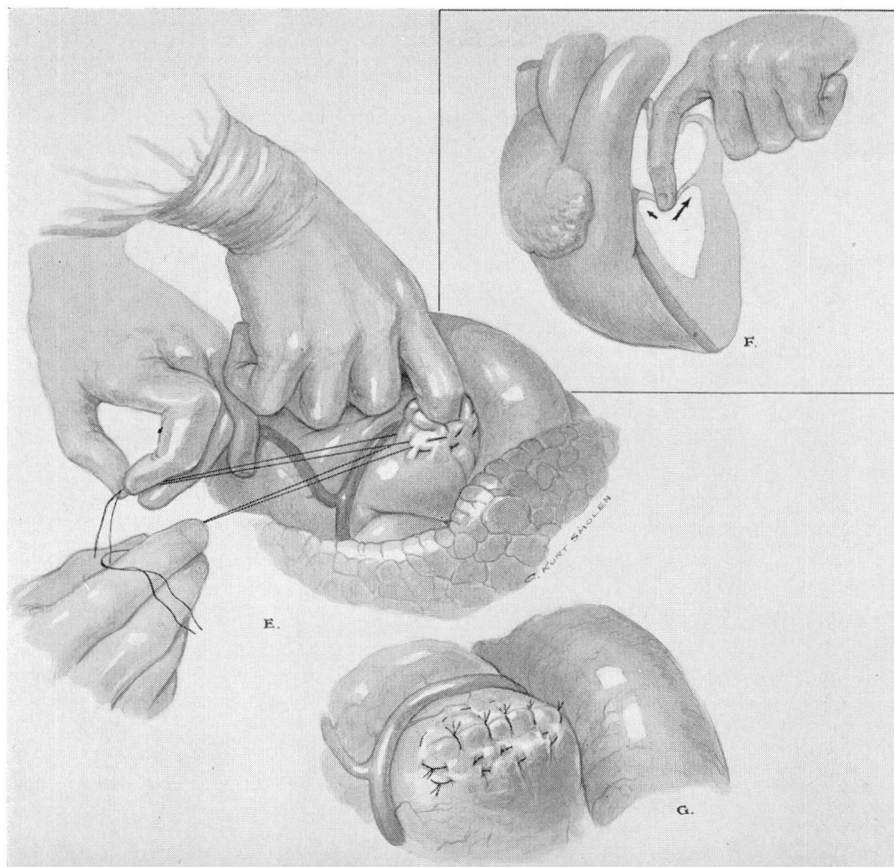


FIG. 5. (E) "Digital visualization" of diseased valve is accomplished with the aid of hemostatic purse string sutures around base of auricular appendage. (F) Cross section illustration showing range of examination by index finger. Arrows indicate lines of the two commissures of diseased mitral valve. (G) Obliterated auricular appendage following completion of procedure.

### Operation

A modified posterolateral approach is employed, usually removing the fifth rib or going through the fifth interspace (fig. 4A). The expanded lung is retracted by the assistant and the pericardium is incised generously, usually on a line posterior to the phrenic bundle, carefully avoiding injury to the phrenic nerve (fig. 4B). The auricular appendage is examined and two purse string sutures are placed around its base; the second is a precaution in the event of accidental breakage of the hemostatic suture (fig. 4C). A non-crushing angle-clamp is placed across the base of the appendage and the tip of the appendix amputated (fig. 4D). The appendage is then carefully inspected for the presence of thrombi. If thrombi are present the clamp is removed and

blood is allowed to gush through the severed appendix in order to wash any fresh mural thrombus out into the thoracic cavity. The cavity of the appendix is repeatedly lavaged with saline solution to prevent a fresh thrombus from forming and being pushed into the auricular cavity by the index finger. As the index finger is introduced into the auricle with release of the clamp, the assistant draws up the hemostatic purse string (fig. 5E). This permits an unhurried digital exploration of the auricle. The auricular chamber is palpated for septal defects, mural thrombi, and other abnormalities. The mitral valve is then carefully palpated. Considerable information may be obtained from this procedure. Mitral regurgitation produces a characteristic stream that is easily felt and may be evaluated quantitatively to some degree. Calcium is also easily identified and when present is handled carefully to prevent fracturing and subsequent embolic phenomena. The degree of stenosis can be determined accurately by the tip of the finger (fig. 5F). Usually the finger tip will completely occlude the stenotic valve and effectively interrupt the blood flow from auricle to ventricle. This digital occlusion is used later to determine the degree of patency obtained by the commissurotomy. The thickness and pliability of the valve are also important factors in estimating the extent of the disease process and the prognosis from the standpoint of operative correction. Obviously a thick valve with little pliability will never be an effective competent structure even though the commissure is reopened. Ideally the valve is opened bilaterally along the lines of the medial and the lateral commissures. However, when extensive calcification has obliterated one of these two landmarks a unilateral commissurotomy is usually sufficient.

Whether the commissurotomy is performed by finger fracture or by instrument depends entirely upon the judgment of the surgeon. With increasing experience we tend to favor finger fracture as a safer and more effective method. In many patients the auricular appendix is so small that it will barely admit the index finger, and the addition of an instrument therefore is not feasible. Also variations in the topography of individual hearts make accurate incision by "manual vision" subject to a certain range of error. Finger fracture has proved reliable and adequate in the majority of patients. At the completion of commissurotomy the valve is palpated to detect any regurgitant stream incidental to the procedure and to evaluate the outflow tract of the "restored" mitral valve. Usually the operation is concluded without producing regurgitation or increasing that which was already present. Ideally commissurotomy permits free motion of the valve leaflets with an increase in effective valve area of approximately 200 to 400 per cent. Whereas the tip of the index finger would occlude the stenosed lumen prior to operation, the valve will usually admit two fingers or more after commissurotomy is completed.

When the finger is withdrawn from the heart, the purse strings are brought up tightly and the stump of the auricular appendage is closed with vertical mattress silk sutures (fig. 5G). The pericardial incision is closed loosely to allow free drainage into the left pleural space. A biopsy is taken of the lung for histopathologic studies, and the chest is closed with closed catheter drainage.



The entire operation is carried out with continuous electrocardiographic monitoring. The importance of cooperation between the anesthetist, cardiologist, and surgeon cannot be overemphasized. Many of the arrhythmias that might seriously complicate the operative procedure are anticipated and avoided by continual observation of the electrocardiographic record. There have been no uncontrolled arrhythmias.

**Postoperative Management:** The average period of hospitalization postoperatively has been 14 days. Most patients are able to sit up and feed themselves by the third postoperative day, and are allowed bathroom privileges on the seventh to tenth days. At the time of discharge, a bed and chair regimen at home is advised for the first two weeks. The patient is then allowed to gradually increase physical activity, being careful to remain within his exercise tolerance. Fatigue and dyspnea are avoided under all circumstances. Maximal activity tolerance is usually attained by the third or fourth month after operation.

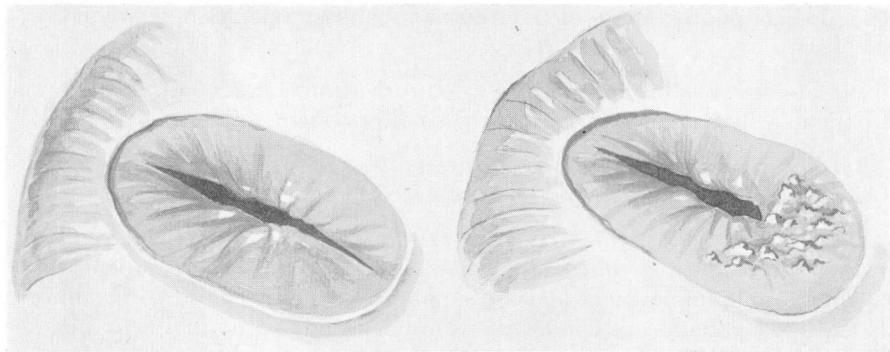


FIG. 6. A comparison with the diseased valves sketched in Fig. 3 will emphasize the increase in lumen<sup>8</sup> produced by commissurotomy. Valve depicted on the left has bilateral commissurotomy and represents the ideal surgical result. Valve depicted on the right illustrates a common finding when one commissure is replaced with superimposed calcareous deposits. Actually this calcium may resemble stalagmites. An attempt to fracture or cut through this portion of valve will increase the hazard of embolism by fragments of calcium. A generous incision in the opposite commissure will frequently suffice for a good clinical result.

A low sodium diet is advised for all postoperative patients during the first six to eight weeks. This is not necessary thereafter in Class II patients. Class III patients require salt restriction for longer periods of time, and in some instances this may be a permanent measure.

Occasionally during the first three months after operation there are recurring episodes of left anterior and lateral chest pain which may be quite distressing. These are not accompanied by evidence of pericarditis or pleuritis. The pain is usually aggravated by motion of the shoulder girdle but may be continuous. It is relieved by salicylates and codeine when necessary and disappears in one to four days. This problem has not been encountered after the fourth postoperative month.

All patients with sinus rhythm are given Pronestyl during the first three months after operation. It is then discontinued. No patient treated in this manner has developed auricular fibrillation after operation, although this was a frequent complication before Pronestyl was used.

## Results

Ten men and 22 women, aged 21 to 54 years, have been observed for from 2 to 20 months after operation. Two patients belonged to Class II(a); 11 were in Class II (b); 18 were in Class III, and one in Class IV.

Two patients died shortly after operation, one of cerebral embolism which occurred during operation, and one of hemorrhage and cardiac tamponade. The third patient who died after operation was the only Group IV patient in the series. This man had severe mitral insufficiency as well as mitral stenosis. He failed to improve and died three months after operation of pulmonary embolism.

No attempt has been made to evaluate the functional result of operation in patients who have not yet passed the sixth postoperative month.

Of 17 surviving patients who have been observed for longer than six months obvious functional improvement has occurred in 16.

Of 11 Class III patients, the single failure occurred in one who had been in congestive failure for longer than four years. Four Class III patients have returned to full employment and are supporting themselves and their families. Six Class III patients are housewives who have resumed normal activities.

All five patients in Group II (b) have shown satisfactory improvement. Despite increased levels of activity none has suffered hemoptysis or pulmonary edema. There has been no recurrence of nocturnal dyspnea or orthopnea.

The remaining patient in Group II (a) is now regularly employed as a truck driver. He is entirely asymptomatic.

There have been no embolic complications in any of the surviving patients.

## Summary

Preliminary clinical results in 32 patients with mitral stenosis, treated by mitral commissurotomy, are summarized.

Clinical criteria used in the selection of patients for operation and the contraindications to surgery are discussed.

The essential factors in pre- and postoperative management and the technic of operation are briefly described.