

ENDOMETRIOSIS OF THE BLADDER

A Report of Three Cases

CHARLES C. HIGGINS, M.D. and ELLIOTT E. STEARNS, M.D.

Department of Urology

A REVIEW of the literature reveals 68 cases of endometriosis of the urinary bladder. It is difficult to estimate the incidence of this lesion, since in the past cystoscopic inspection of the bladder has not been routinely employed in the presence of pelvic endometriosis.

Masson¹ in a review of the records of 576 patients in whom diagnoses of endometriosis had been established cited two instances in which vesical lesions were demonstrable; while Seitz² reported three patients with bladder involvement in 65 cases of pelvic endometriosis.

In a series of 530 consecutive cases of pelvic endometriosis observed at the Clinic, vesical lesions were present in three; a fourth instance, not as yet confirmed by biopsy, is not included. In reports reviewed in the literature, it is not stated whether cystoscopy was a routine procedure or employed only when symptoms deemed it advisable. In this series of 530 cases, cystoscopic examinations were performed only in patients with symptoms referable to the bladder. It is our purpose to report these three cases of vesical endometriosis and comment briefly on current therapeutic trends.

CASE REPORTS

Case 1. A woman, 43 years of age, Para I, gravida I, entered the Clinic in June 1952 with complaints of urgency, frequency, dysuria, and occasional severe pain following micturition. The symptoms had been observed for 15 years, beginning on the second or third day of each menstrual period and abating in approximately one week. Terminal hematuria had been noted on one occasion in May 1952, a month before admission. There were no other symptoms referable to the pelvis.

The past history was noncontributory except for her inability to become pregnant following the birth of one child.

General examination revealed normal findings.

A mid-cycle pelvic examination was normal except for a somewhat cystic left ovary. The intravenous urogram showed excellent function of both kidneys, while routine laboratory studies were normal.

On cystoscopic examination, clustered vesicles of various sizes were observed on the posterior wall of the bladder. The vesicles ranged in color from red through blue to a black tinge. A cup biopsy was performed and microscopic study of the tissue revealed endometriosis (fig. 1).

Following these reports, treatment was immediately instituted consisting of external roentgen therapy, 1000 r of 200 K.V. radiation to the anterior and posterior pelvic

fields, calculated to produce castration. With the cessation of the menses, the patient experienced complete relief of symptoms.

Cystoscopic examination approximately one month after treatment revealed only one extremely small vesicle located in the site previously occupied by the extensive lesion.

Case 2. A woman, 42 years of age, entered the Clinic in January 1951, complaining of pain in the region of the right kidney. The pain which previously consisted of attacks of renal colic had changed to a constant, steady, dull-aching character during the eight weeks preceding admission. She also experienced frequency, dysuria, and urgency. There was no history of hematuria, and she had noted no relationship between her symptoms and the menses. A pelvic operation had been performed elsewhere in 1930, the nature of which could not be determined. In 1950 an exploration of the right kidney had been undertaken elsewhere, the nature of which could not be ascertained; but the symptoms had persisted and menses ceased shortly after this surgical procedure. There was no history of pregnancy.

Physical examination revealed diffuse enlargement of the thyroid gland. The right kidney was palpable. On pelvic examination a firm fixed mass, 3 by 5 cm., was palpated in the right adnexal region. This was believed to represent the right ovary.

Intravenous urographic study demonstrated only impairment of function of the right kidney.

The routine laboratory studies were normal. *Escherichia coli* was isolated from the urine secured by catheterization.

The cystoscopic examination disclosed a flat irregular tumor, the size of a dollar, just above and encroaching on the right ureteral orifice. A No. 4 ureteral catheter encountered an obstruction 2 cm. from the orifice. Following cystoscopic survey, a specimen was secured for biopsy by means of the resectoscope, and a diagnosis of endometriosis established by microscopic study.

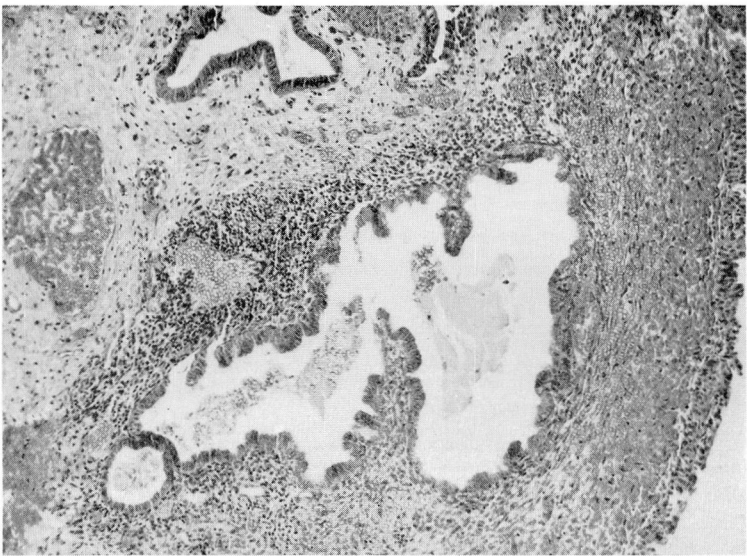


Fig. 1. Microscopic section showing area of endometriosis of bladder.

The treatment instituted consisted of external irradiation, 1000 r of 200 K.V. to the anterior and posterior pelvic fields; however, the pain in the right renal area persisted. Three months following the administration of roentgen therapy the right ureter was dilated and cystoscopic examination revealed a pronounced regression of the bladder lesion. Six months later a ureteral calculus, not demonstrable at the time of the initial examination, was removed, and the ureter again dilated. There was no residuum of the intravesical endometrioma discernible and the patient has remained free of symptoms for more than two years.

Case 3. The patient, a woman 31 years of age, Para 0, gravida 0, entered the Clinic in October 1946, complaining of suprapubic pain, urgency, dysuria, and frequency. The symptoms had been present for 20 months, beginning premenstrually and terminating with the onset of flow. She had never detected the presence of blood in the urine. Six months prior to admission a left salpingo-oophorectomy had been performed for endometriosis. Incomplete treatment for asymptomatic syphilis had been instituted in 1940.

The physical examination revealed a fixed, dilated, right pupil and moderate enlargement of the heart with a grade II aortic systolic murmur. The pelvic examination was normal.

The blood and spinal fluid Wassermann tests were positive. Other laboratory findings were normal.

Intravenous urographic studies demonstrated the function of the kidneys to be satisfactory. *Proteus bacillus* was isolated from the catheterized bladder urine.

Cystoscopic examination revealed a single bluish-colored vesicle, the size of a cherry, in the region of the left ureteral orifice. A specimen for biopsy was secured and on microscopic study demonstrated glandular structures with old hemorrhage. The lesion was observed to increase in size with each menstrual flow.

Treatment was begun with roentgen therapy, 1000 r, 200 K.V. to the anterior and posterior pelvic fields. The menses ceased but her symptoms persisted.

In July of 1949, approximately three years after entry, surgical intervention was instituted and an endometrioma of the bladder was resected. A remaining cystic portion of the left ovary was removed.

Following this procedure the symptoms were completely alleviated. She was again observed in 1953, four years later, at which time a hernia was repaired. There were no clinical symptoms referable to the bladder, and cystoscopic examination revealed normal findings.

DISCUSSION

In order to establish the diagnosis of endometriosis it is essential to investigate thoroughly patients with urinary tract symptoms. The symptoms of bladder involvement by endometriosis are variable and hematuria may not be present. Moore³ has stated it is evident in less than one third of the cases. In the three cases reported here, blood was detected in the urine in one instance; also it is obvious that hematuria may be masked by the menstrual flow. Any symptom of vesical irritation should be viewed with suspicion if it is concomitant with menstruation. Occasionally, symptoms subsequent to ureteral obstruction will be present (case 2) or pelvic pain may be the only complaint.

Generally, diagnoses will be facilitated by cystoscopic examination during the menstrual flow, viewing the bluish-colored vesicles on the bladder wall. In some instances the characteristic vesicles are not evident and the lesion resembles a primary tumor of the bladder (case 2).

Ockuly and Helwig⁴ believe that a diagnosis can be made in only a small per cent of the cases by biopsy. The cup biopsy is preferable to one secured by the resectoscope with coincident tissue destruction by the cutting current.

It is known that in general pelvic endometriosis, the symptoms frequently have no relation to the extent of the disease. Undoubtedly, this is also true in the bladder, but due to constant change in vesical dynamics, lesions in this location are often more symptomatic. Bladder lesions may coexist with generalized endometriosis involving other pelvic organs, or may occur without other evidence of the disease.

Numerous articles have appeared in the literature concerning the origin and nature of endometriosis,⁵⁻⁷ but in this paper we will not consider this aspect of the disease.

The approach to therapy for endometriosis of the bladder is not unlike that instituted for the disease when located elsewhere. Treatment must be individualized and planned to meet the patient's needs and interests.

In the past several years there has been an increasing trend towards conservatism in treating endometriosis, irrespective of its location. When selecting the therapeutic program not only should the physical status of the patient and the extent of the lesion be considered, but equally important are the age, marital status, parity, and the desire for pregnancy.

Isolated bladder lesions may often be treated with local fulguration, since malignant degeneration, although reported, is unusual and complete destruction may be accomplished. When the lesions are more extensive they may be amenable to local resection. In instances in which the lesion is in close proximity to the ureteral orifice or situated on the trigone, irradiation of the ovaries may be the most conservative approach in a woman who is near the end of menstrual life. However, if the same lesion occurred in a younger person, local resection with reimplantation of the ureter into the bladder might render it possible for the patient to achieve a much desired pregnancy and also avoid the sequella of castration.

When the diagnosis of endometriosis is made and other pelvic findings suggesting widespread disease are noted, it may be assumed that all are associated with endometriosis. However, this does not preclude the possibility of other coexisting pelvic disease. It would seem that the wisest course in a patient whose general condition is satisfactory consists of operative evaluation with resection of the pelvic or bladder lesions if possible. Removal of the ovaries will of course be followed by regression of the lesions. By open operation it is usually possible to perform the surgical procedure most compatible with the patient's needs and still combat the disease. An endometrioma of the bladder may be resected or localized lesions in the pelvis removed, permitting the menses to continue and pregnancy to be achieved.

In other instances, if surgery fails or if it is impossible to remove the ovaries and uterus, we may then employ irradiation secure in our knowledge of the entire situation. In a patient, who is a poor surgical risk, primary irradiation may represent the most conservative approach.

The newer medical treatments consisting of estrogen therapy, as proposed by Karnaky,⁸ and testosterone, cited by Schmitz and Towne⁹ and Siegler,¹⁰ may be of some benefit in selected cases.

Karnaky reported favorable results after the treatment of 37 women with large doses of stilbestrol. The rationale of this therapy is thought to be a suppression of the anterior pituitary gland with subsequent inhibition of ovarian function. Stilbestrol, however, carries with it the undesirable effects of nausea and complications of bleeding. Although it is effective in the relief of pain the obtaining of any remarkable regression of the disease is doubtful.

Testosterone is capable of suppressing ovarian activity and may be effective in controlling the bladder lesions; but it is mainly useful as a stopgap measure and utilized to postpone temporarily the need for more radical therapy. It is stated that this treatment is disadvantageous because in many cases, prolonged suppression of symptoms can not be maintained without masculinization.

In the three cases of endometriosis of the bladder reported here, roentgen therapy was advised on the basis of the following considerations:

Case 1. A nurse, 43 years of age, requested castration by irradiation of the ovaries. She was acquainted with the sequella of castration, but was opposed to surgical intervention. After consideration of the patient's personality and desires, roentgen therapy was employed.

Case 2. The patient was an emotionally unstable woman, 42 years of age, who had not menstruated during the year prior to admission. The endometrioma of the bladder encroached on the right ureteral orifice producing sufficient obstruction to impair the drainage of urine from the right kidney. As the menstrual life was already terminated, roentgen therapy appeared to be the treatment of choice.

Case 3. This woman, 31 years of age, had a diagnosis of syphilis made six years prior to our examination. The treatment was inadequate as evidenced by the blood and spinal fluid Wassermann tests being positive. Six months previously a left salpingo-oophorectomy had been performed elsewhere for endometriosis. Cardiac enlargement was present with a grade II aortic systolic murmur.

In view of these findings roentgen therapy was employed. In contrast to the results obtained in cases 1 and 2, pain and discomfort persisted. Three years later surgical intervention was required which afforded complete relief of symptoms.

It is interesting to note this patient was managed before the recent surge towards conservatism in the treatment of endometriosis.

SUMMARY

1. Three cases of endometriosis involving the urinary bladder have been discussed and conservatism in the management of these patients emphasized.

2. Local fulguration or open operation for endometriosis of the bladder are the treatments of choice.

3. Irradiation should be reserved for the patient who is a poor surgical risk, or upon failure of the previously mentioned treatment.

4. The role of estrogenic and androgenic therapy in these cases is as yet to be determined.

Acknowledgment

We wish to express our thanks to Dr. James S. Krieger of the Department of Gynecology for his comments.

References

1. Masson, J. C.: Surgical significance of endometriosis. *Ann. Surg.* **102**:819-833 (Nov.) 1935.
2. Seitz, L.: Die Klinik der Endometriosis. *Zentralbl. f. Gynak.* **57**:1-11 (Jan. 7) 1933.
3. Moore, T. C., Herring, A. L. and McCannell, D. A.: Some urologic aspects of endometriosis. *J. Urol.* **49**:171-177 (Jan.) 1943.
4. Ockuly, E. A. and Helwig, F. C.: Endometriosis of urinary bladder with report of case. *J. Urol.* **55**:464-469 (May) 1946.
5. Cullen, T. S.: Adenomyoma of the uterus. *J.A.M.A.* **1**:107-115 (Jan. 4) 1908.
6. Novak, E.: *Gynecological and Obstetrical Pathology with Clinical and Endocrine Relations*, ed. 2, Philadelphia, W. B. Saunders Co., 1947.
7. Sampson, J. A.: Perforating hemorrhagic (chocolate) cysts of ovary, their importance and especially their relation to pelvic adenomas of endometrial type. *Arch. Surg.* **3**:245 (Sept.) 1921.
8. Karnaky, K. J.: Use of stilbestrol for endometriosis; preliminary report. *Southern M. J.* **41**:1109-1111 (Dec.) 1948.
9. Schmitz, H. E. and Towne, J. E.: Treatment of pelvic endometriosis. *Am. J. Obst. & Gynec.* **55**:583-590 (April) 1948.
10. Siegler, S. L. and Bisaccio, J. R.: Endometriosis, clinical aspects and therapeutic considerations. *Am. J. Obst. & Gynec.* **61**:99-108 (Jan.) 1951.