

PECTUS EXCAVATUM: SURGICAL TREATMENT

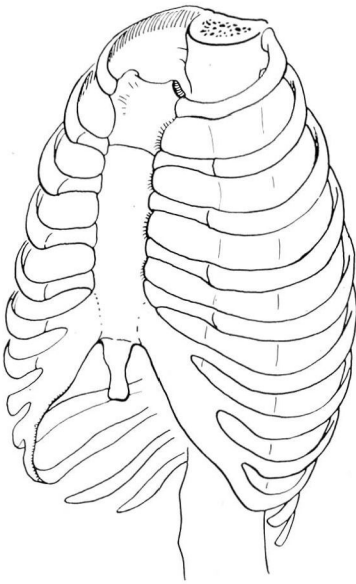
DONALD B. EFFLER, M.D.
Department of Thoracic Surgery

THE unsightly deformity of pectus excavatum, or "hollow chest," is an acquired lesion. It usually occurs in healthy infants who manifest no nutritional problems, contrary to the old concept that it followed childhood rickets. It may be recognized as early as the second month of life; more commonly the alert parent or pediatrician will detect the depression of the sternum in the infant of four to six months of age.

Pectus excavatum is a structural deformity that progresses in severity with body growth. It is caused by abnormal anatomic relationships between the central attachments of the diaphragm and the sternum.¹ In the anterior midline the diaphragm inserts on the xiphoid cartilage below or at its junction with the body of the sternum. When body growth progresses normally, the diaphragmatic attachment to the xiphoid is lengthened with the increasing anteroposterior diameter of the expanding thorax. If, for some reason, this attaching structure cannot lengthen adequately it will compromise the anterior growth of the xiphoid and the lower sternum. This may be visualized by considering the central attachment of the diaphragm as an unyielding, ligamentous guy rope between the soft, cartilaginous xiphoid and the vertebral column. When the thorax is contracted in expiration, the guy rope is slack and the deformity minimal or nonexistent; during full inspiration the diameter of the bony thorax increases and the guy rope becomes taut, restricting the anterior excursion of the xiphoid. In the infant this deformity, apparent only during inspiration, is first observed when he cries. As growth progresses the taut guy rope affects the full cycle of respiration and the xiphoid depression appears to deepen. Actually the bony thorax is growing away from the restricted lower end of the sternum (fig. 1).

There are secondary changes which appear as the pectus excavatum is established. The costal cartilages connecting the depression with the expanding rib cage are gradually "warped" into the depression. When the pectus excavatum causes severe depression, the anteroposterior shortening of the lower chest restricts the lower mediastinum. The result is a decided displacement of the heart and major vessels to the left of the midline. Whether severe mediastinal deviation associated with pectus excavatum is in itself clinically significant is debatable.

The cosmetic trauma of pectus excavatum in a child of school age and a young adult is significant.² The unsightly appearance of the sternal depression will inevitably arouse comments and curiosity from schoolmates and companions. These patients are reluctant to take part in athletic programs or other group activities where the chest deformity may be exposed. A feeling of physical



normal

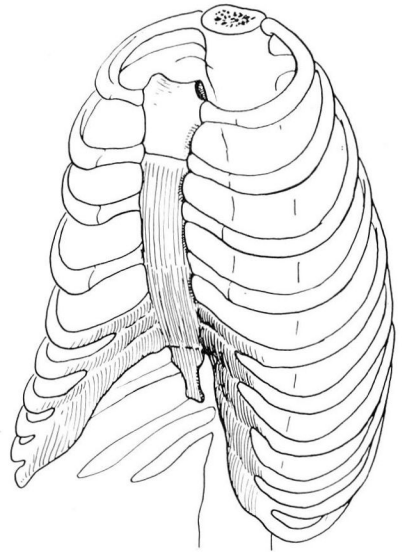
E. Kurt Smolen
1922pectus
excavatum

Fig. 1. A comparison of the normal bony thorax with that of pectus excavatum reveals the depression and associated costal flare. Only the anteroposterior diameter of the lower thorax is involved; compression and deviation of the mediastinum result.

inferiority and resultant personality impairment are frequently associated with pectus excavatum.

SURGICAL TREATMENT

There are two phases of corrective therapy in pectus excavatum: (a) *infantile*, and (b) *adult*. The treatment is surgical in both phases, but the extent of surgery required differs considerably.³ Therefore, early recognition and prompt correction are especially advantageous to the patient and his parents.

(a) The *infantile form* of pectus excavatum is corrected with minimal effort and the element of risk is correspondingly low. The ideal age for surgical intervention is four months.⁴ At this age the impending deformity may be recognized and evaluated; the rib cage is soft and there is no fixed disfigurement. The operation consists only of resecting the xiphoid cartilage and releasing any adjacent fibrous attachment between the diaphragm and the lower sternum.

Technic. The infant is kept in the supine position when open drop ether is administered. An incision is made in the midline, directly over the xiphoid depression, and carried down to the rectus sheath. The sheath of the rectus is divided in the midline, and the lower border of the xiphoid cartilage is grasped by hemostat and elevated. By dissection with scissors the xiphoid is cut away from all muscular and fibrous attachments; the junction between the xiphoid and the body of the sternum is identified and the cartilage transected at that level. The tip of the index finger is used to determine any restricting diaphragmatic attachments to the lower end of the sternum; usually there are none. One or two sutures are used to close the rectus sheath and several more employed for skin closure. The postoperative care is simple; only one or two days of hospitalization are necessary. The skin sutures may be removed in five days at the patient's home or in the office.

This simple operation releases the restricting diaphragmatic attachment to the lower sternum and xiphoid. Normal growth of the bony thorax is permitted, and unnecessary deformity of pectus excavatum is avoided.

(b) In the *adult form* of pectus excavatum the surgical correction taxes the ingenuity and patience of the surgeon. The fixed bony depression together with the flattened thorax and the flaring costal margins present a difficult problem. In many instances the deformity is so severe that anticipated improvement must be considered on a relative basis.

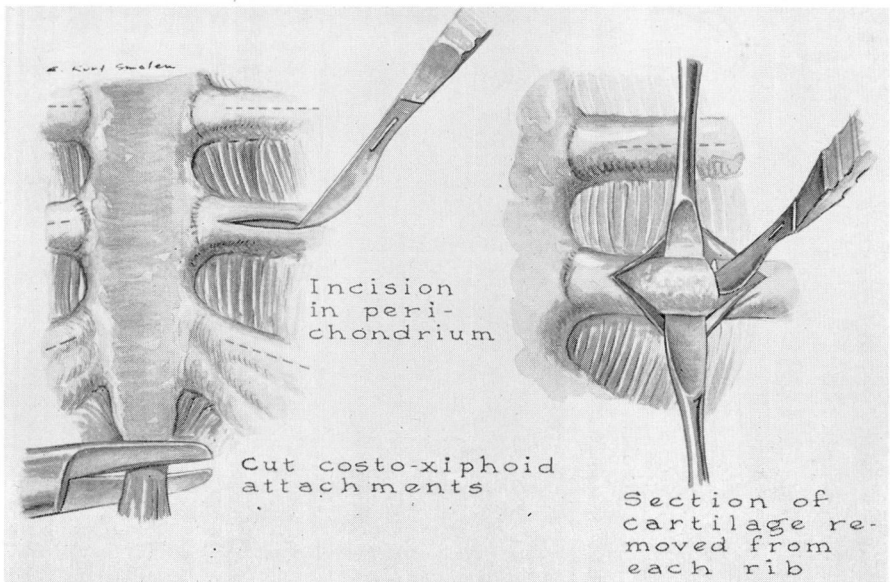


Fig. 2. After exposure through a midline incision the lower sternum is mobilized by partial resection of the costal cartilages and the xiphoid. Care is taken to preserve the perichondrium.

Technic. Endotracheal gas-oxygen anesthesia is employed. The patient is in a supine position. The incision is midline and extends the full length of the sternum. The skin edges are undermined, the plane of cleavage lying between subcutaneous fascia and pectoral muscles, from the midline laterally to the costochondral junctions. The pectoral muscles are incised directly over the third costal cartilages, and the perichondrium is cut along the long axis of the rib. The first and second cartilages are not disturbed. The perichondrium is carefully stripped from the cartilage and the cartilage excised from sternum to the bony rib. This process must be repeated for each of four to six pairs of cartilages (fig. 2). Emphasis is placed on the need for preserving the perichondrium, otherwise a soft chest wall will result on either side of the sternum. When properly preserved, the youthful perichondrium will regenerate cartilage.

Excision of eight or ten costal cartilages is a tedious surgical procedure. The surgeon is tempted to shorten the operation by breaking or transecting the

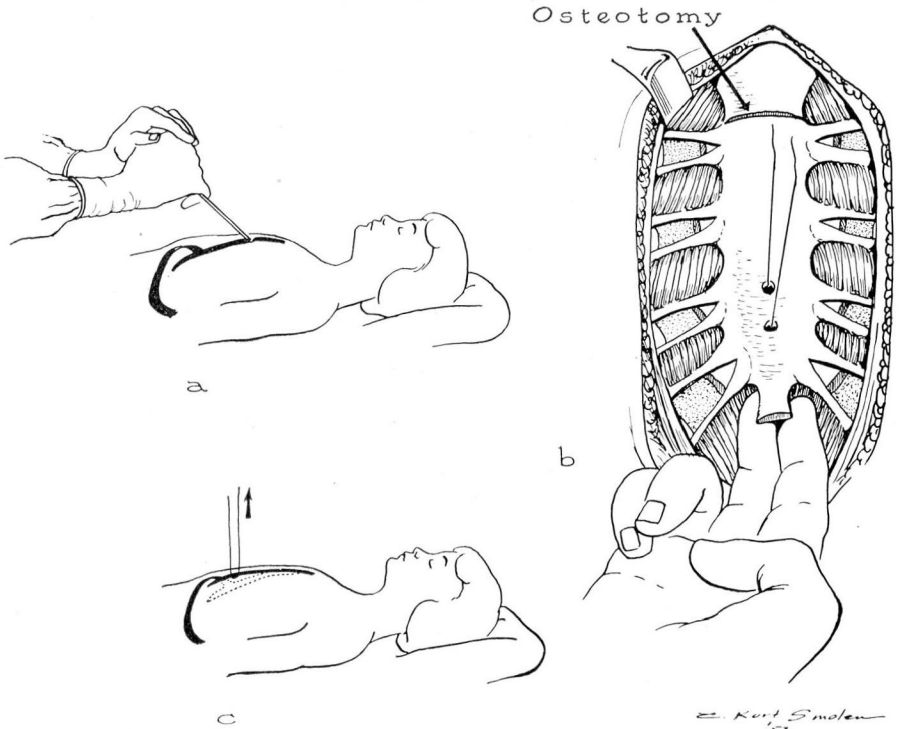


Fig. 3. (a) A wedge osteotomy is made in the anterior plate of the sternum below the manubrial junction. This may be done with bone chisel or bone saw. (b) A loop of wire is employed for continuous traction on the mobilized segment of sternum. Additional drill holes may be made if more wire loops are desired. (c) Elevation of the mobilized segment before closure of the wound indicates the degree of traction necessary. Usually rubber band traction is used to compensate for respiratory excursion.

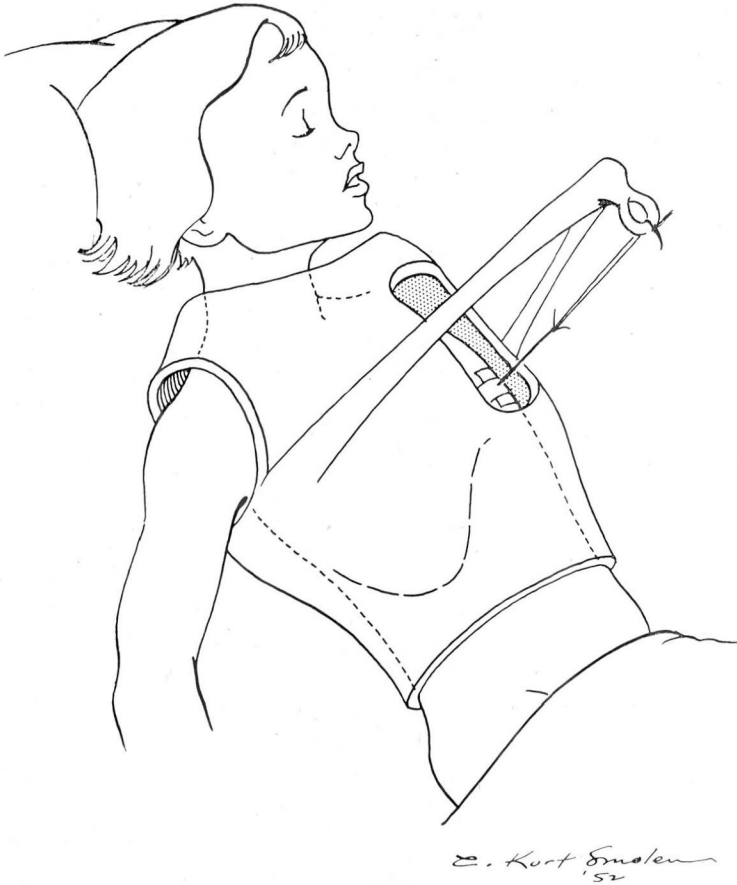


Fig. 4. Sketch of the plaster jacket and simple countertraction bar. A window is placed over the operative area for care and inspection. The single wire loop in this case is suspended by an ordinary rubber band.

cartilages and literally fracturing the sternum into place. The best cosmetic result will be obtained by complete removal of the "warped" cartilage which permits regeneration of new cartilage with normal contour.

After excision of the costal cartilages the xiphoid is disarticulated and removed. The retrosternal space is easily entered and the lower end of the sternum elevated by retractor. The flimsy mediastinal fascia and loose areolar tissue are easily separated from the posterior aspect of the sternum by blunt dissection. Mobilization of the deformed sternum is carried up to the second interspace where the sternal body and manubrium articulate. The level where the depression begins is selected and a transverse wedge osteotomy is performed through the anterior plate of the bone. This may be done with a saw or chisel

(fig. 3a). The sternum is then elevated to proper position for correction of the deformity.

Fixation is necessary during the early period of cartilage regeneration. A simple method of wire traction is now employed (fig. 3b). Methods employing rib struts, grafts, and internal fixation should be utilized with caution. By the simple measure of a wire loop through two drill holes in the lower sternum, a system of constant, rubber band traction has been used (fig. 3c). A light plaster jacket is made before the operation and is bivalved. A window is cut over the operative site and a bar for countertraction incorporated in the cast (fig. 4). The light cast permits prompt ambulation of the patient and also affords protection to the chest wall. Traction is maintained for three or four weeks, and the wire loop is then removed. In active children the jacket may be worn as a protective vest for an additional period of time.

One detail that deserves special mention is the accurate evaluation of the defect before surgical correction is attempted. Fluid may be poured into the hollow defect while the patient is supine and the amount accurately measured. This is sometimes difficult in the very small child. Radiographic studies are valuable; of these, the true lateral projection in both expiration and inspiration will be most helpful. Accurate measurement of the deformity will assist in evaluating the operative procedure.

SUMMARY

Pectus excavatum is an acquired lesion and may occur in an otherwise healthy person. The deformity is primarily of cosmetic significance and to a lesser degree impairs health or well being. The degree of deformity is directly dependent upon the fixation of the terminal sternum and the xiphoid cartilage.

Correction of pectus excavatum is a surgical procedure and two methods of correction are described. Selection of the type of operation depends on the age of the patient and the degree of sternal fixation.

References

1. Brown, A. L.: Pectus excavatum (funnel chest) anatomic basis; surgical treatment of incipient stage in infancy; and correlation of deformity in fully developed stage. *J. Thoracic Surg.* 9:164-184 (Dec.) 1939.
2. Ravitch, M. M.: Operative treatment of pectus excavatum. *Ann. Surg.* 129:429-444 (April) 1949.
3. Sweet, R. H.: *Thoracic Surgery*. Philadelphia, W. B. Saunders Co., 1950, p. 99.
4. Jones, J. C.: Personal communication.