

INTERMITTENT CLAUDICATION OF THE HIP

FAY A. LeFEVRE, M.D.

Department of Cardiovascular Disease

GEORGE S. PHALEN, M.D.

Department of Orthopedic Surgery

and

VICTOR G. deWOLFE, M.D.

Department of Cardiovascular Disease

INTERMITTENT claudication has long been recognized as one of the earliest and most frequently encountered symptoms of peripheral vascular disease. It is the purpose of this report to stress the importance of this disease as a cause of localized, intermittent, hip pain.

A cramp-like pain in the calf which occurs during walking and is promptly relieved by rest is almost certain to be correctly attributed to some interference with the normal arterial circulation of the lower leg. Because of the frequent association between pain in the calf and occlusive arterial disease, the term "intermittent claudication" has become almost synonymous with this particular symptom; however, typical intermittent claudication may occur in any muscle or group of muscles if the arterial blood supply is insufficient to permit their normal active use. It most frequently involves the calf for several reasons. These muscles have a relatively large volume yet receive their blood supply through arteries of relatively small caliber. Involvement of these arteries, especially the sural and peroneal arteries, is extremely common in peripheral vascular disease. The gastrocnemius and soleus muscles (triceps surae) are the chief plantar flexors of the foot at the ankle joint and are constantly used in walking. When the arterial blood supply to the triceps surae is insufficient to permit the muscle group to continue the vigorous contractions required by a normal amount of walking, running or climbing, claudication develops and is relieved only by cessation of movement.

Intermittent claudication at a level higher than the calf is not a new clinical syndrome. Numerous authors,¹⁻⁹ in discussing thrombosis and embolism of the aorta and iliac arteries, have mentioned that their patients sometimes complained of pain in the muscles of the lower back, hips or thighs. Homans¹⁰ in 1939 mentioned the extension of the pain of peripheral vascular disease into the upper thigh and buttocks simulating a sciatic neuritis. In discussing the syndrome of intermittent claudication, Samuels¹¹ stated that there might be a shooting pain in the buttock of the affected side occurring as a solitary symptom or accompanied by claudication in the legs or feet.

Arteriosclerosis obliterans and thromboangiitis obliterans are the two most common causes of intermittent claudication, although any other condition, local or systemic, which significantly reduces the arterial blood supply to a group of muscles may produce this symptom.

Obliterative arterial disease is seldom considered in the etiology of localized pain in the hip; however, it is an important cause of this symptom. The status of the peripheral circulation in the lower extremities should be ascertained in every patient who complains of pain in the low back, hip or thigh. For example, if a patient is found to have definite impairment of circulation in the right leg and only complains of pain in the right hip, it is possible that the vascular insufficiency alone may be the cause of the pain. This is further substantiated if there is evidence of a better circulation in the opposite limb, and the patient has no complaints referable to this hip or leg. A careful history will enable the physician to decide whether or not the patient has true intermittent claudication of the hip.

During the past five years we have seen 47 patients with occlusive arterial disease involving the abdominal aorta or iliac arteries. The extent of the disease was demonstrated by aortography in 30 of these patients; 26 had typical intermittent claudication involving the hip, thigh or low back area without pain in the calf region.

The following two cases are typical of those studied in this series.

CASE REPORTS

Case 1. A 49 year old businessman was seen at the Clinic on July 27, 1949, complaining of aching in the hips and low back that began after he walked two blocks and that was relieved by rest.

Physical examination was noncontributory. The lower extremities had good pulsations at all levels and there were no physical signs of arterial insufficiency.

X-ray of the lumbosacral spine showed calcifications believed to be in the abdominal aorta and the pelvic vessels. There were hypertrophic bone changes. The examiner believed that the patient's symptoms were due to degenerative joint disease.

Two years later his symptoms had become slightly more severe and he was re-examined. He said that after he walked one block the pain started in his hips and buttocks and progressed into his legs and feet. His feet were always cold and occasionally became numb following exercise. There was no impotency.

Examination revealed the temperature and nutrition of the feet to be good. There were moderate pallor on elevation and rubor on dependency. The venous filling time was 30 seconds bilaterally; this is delayed time consistent with peripheral arterial insufficiency. All pulses were absent except an extremely weak right femoral pulse. Oscillometric readings showed only faint pulsation in the thighs. X-rays again revealed aortic and pelvic calcifications. An aortogram (fig. 1) showed complete obstruction of the aorta just below the level of the renal arteries. The origin of the left renal artery appeared to be slightly narrowed.

He was placed on conservative medical management and has not returned for further treatment.

Case 2. A 62 year old man, a laborer, was first seen at the Clinic on January 29,

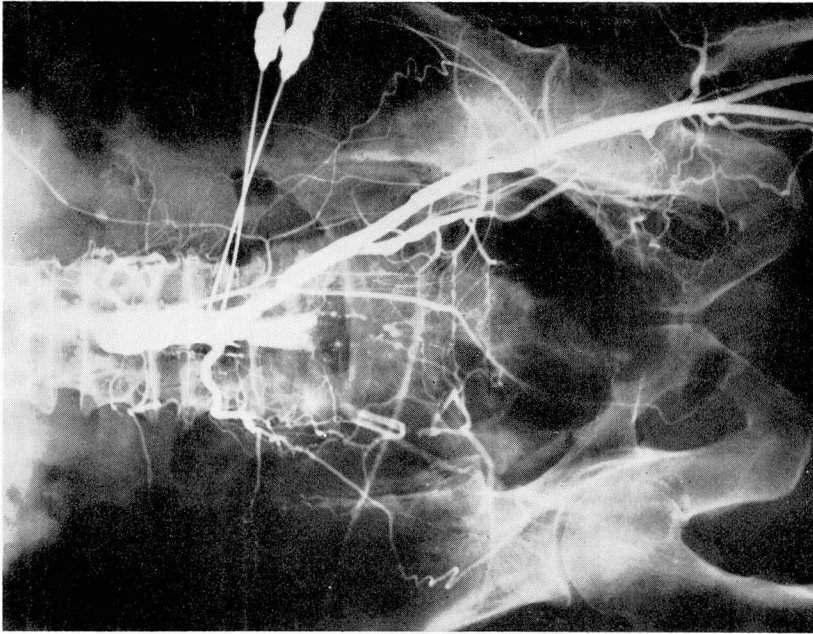


Fig. 2. (Case 2) Aortogram showing occlusion of right common iliac artery at origin. Excellent collateral circulation is demonstrated.

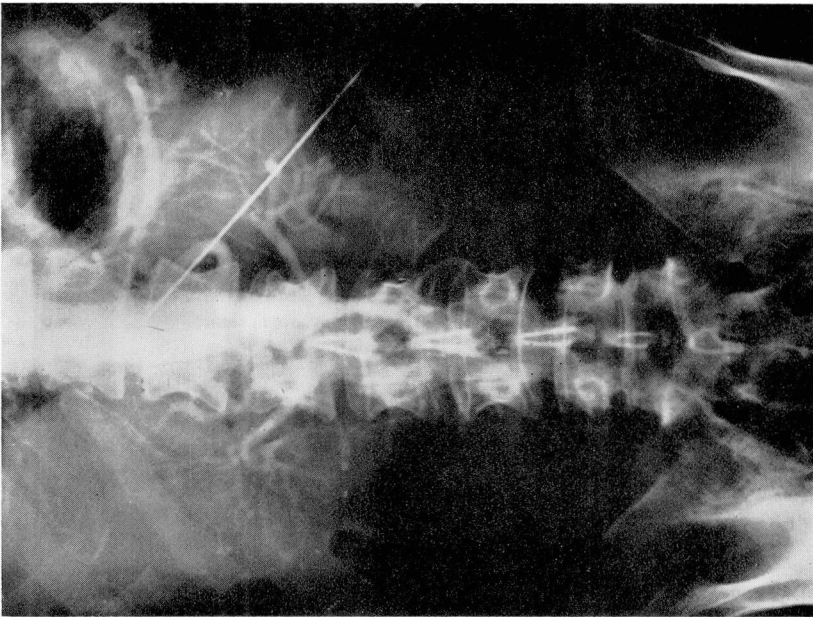


Fig. 1. (Case 1) Aortogram showing complete obstruction of aorta below level of renal arteries.

1952, with a complaint of pain in the right hip and buttock. It had first occurred three months before while he was walking. It had begun suddenly, forcing him to rest, whereupon it subsided in two minutes. Following this, the same discomfort was occasionally incited by prolonged standing or lying on his left side. Then, in addition to the hip pain, he began to experience a weakness in the leg and a numbness down the posterior aspect of the thigh and calf and lateral aspect of the foot. Coughing, straining or motions of the back did not aggravate his discomfort.

After roentgenographic examination, he was told he had osteoarthritis of the spine.

In December of 1952, approximately one year after the initial examination, the patient was seen by a neurosurgeon who noted slight atrophy of the right gluteus muscle and a diminished right ankle jerk. A diagnosis of osteoarthritis of the spine with nerve root compression at S₁ due to a spur or a possible ruptured intervertebral disk was made.

The patient was hospitalized for further study. The spinal fluid was negative. Two diskograms were obtained in December and January and these showed degenerated disks at L₄-L₅ and L₅-S₁, but no protrusion. The pain was not reproduced. A myelogram was negative.

There was no history of diabetes or heart disease.

Physical examination showed a well-developed and well-nourished man. Blood pressure was 190/100 which later fell to normal. A complete examination was noncontributory except for the findings in the lower extremities. There was good nutrition of both feet which were warm and of healthy color. On elevation of the extremities a moderate pallor of the right foot occurred and on dependency a slight rubor. The venous filling time was normal. The peripheral pulses on the left were present and full. On the right only a faint femoral pulsation was felt. Oscillometric examination was normal on the left but abnormal on the right, showing absence of pulsation except for a faint deflection in the thigh.

Laboratory studies including red and white blood counts, hemoglobin, blood sugar and serology were negative. X-rays of the chest and pelvis appeared normal. There was no evidence of calcification of the pelvic arteries. An electrocardiogram was not obtained.

An aortogram (fig. 2) obtained on January 29, 1953, showed occlusion of the right common iliac artery at its origin. There was excellent collateral circulation through the fourth lumbar artery with refilling of the common iliac artery below the block just above the level of the bifurcation into external and internal iliac arteries. There were moderate narrowing of the external iliac artery and slight irregularity of the terminal aorta. The visualization on the left was normal except for some irregularity of the common iliac artery.

On January 30, 1953, one year after the initial examination, a bilateral lumbar sympathectomy from L₁ to L₄ and endarterectomy of the thrombus in the right common iliac artery were done. The patient made an uneventful postoperative recovery.

Approximately two months postoperatively the patient stated that he no longer had pain on walking but had some fatigue in the right thigh after one block of walking, but this was improving. He estimated his improvement to be 75 per cent.

DIAGNOSIS

Intermittent claudication of the hip is not a diagnosis in itself, but rather a symptom of peripheral vascular disease. Arteriosclerosis obliterans is the most common cause of this symptom. Either the abdominal aorta or the iliac arteries

or both may be involved. Occasionally, roentgenograms of the pelvis will reveal more or less extensive calcification in these vessels, but the simple presence of this calcification does not necessarily indicate the presence of claudication. Extensive calcification of the Mönckeberg's type does not usually give rise to symptoms of peripheral vascular disease. The extent of the occlusive arterial disease was demonstrated by aortography in 30 patients in this series. This is a safe procedure and has been invaluable as a diagnostic aid in this group.

Various orthopedic and neurosurgical conditions must be considered in the differential diagnosis of intermittent claudication of the hip. These diseases may be readily differentiated through evaluation of the status of the circulation in the lower extremities of those patients who complain of pain in the low back, thigh and leg.

Hypertrophic arthritis of the hip (*malum coxae senilis*) is an extremely common cause of pain in the hips of patients more than 50 years of age. These patients complain of pains in the muscles about their hips which are aggravated by activity and relieved by rest. However, some restriction of movement of the hip joint always accompanies this pain and roentgenograms reveal the typical cystic and sclerotic changes in the acetabulum and the head of the femur. Although there may be evidence of some arteriosclerosis of the vessels of the involved extremity, there is usually none of any severe impairment of the peripheral circulation.

A localized fibrositis or a simple nonsuppurative bursitis is the most common cause of pain in the hips of patients younger than 50 years. Eighteen or more different bursae have been described about the hip joint, but of these only four are of clinical importance: iliopectineal, ischiogluteal, superficial trochanteric and deep trochanteric. Patients with bursitis have extreme tenderness immediately over or adjacent to the bursa and passive movement of the hip joint usually aggravates the pain. Frequently, those with fibrositis have "trigger points" or areas of extreme tenderness either in the muscle bellies or at the tendinous attachments of muscles to bone. Local infiltration of these tender areas with a dilute solution of novocain will usually give immediate relief from pain.

A protruded intervertebral disk in the lower lumbar region may simulate a true intermittent claudication of the hip. Two of the patients in this series were first diagnosed as having a protruded intervertebral disk and were referred for surgical treatment. It is true that any pressure or irritation of the fifth lumbar or first sacral nerve root may produce pain in the posterior hip area, radiating down the leg in the course of the sciatic nerve. The pain due to a protruded disk is almost always aggravated by bending, lifting, coughing or straining. In contradistinction to intermittent claudication of the hip, the pain associated with a protruded disk is not necessarily dependent upon movement for its production or aggravation. A protruded disk usually produces some alteration in the deep tendon reflexes in the involved lower extremity; and there may also be characteristic sensory changes and muscular weakness in the leg.

Any of the malformations and diseases involving the structures about the

hip may be accompanied by some intermittent pain in this area. The restriction of passive movement in the hip by muscle spasm, bony abnormality or incomplete fibrous ankylosis and the presence of an adequate peripheral circulation in the lower extremity readily differentiate these conditions from intermittent claudication of the hip.

SUMMARY

Pain in the low back, hip and thigh may be of vascular origin due to occlusive arterial disease involving the abdominal aorta or iliac arteries. Intermittent claudication of the hip may be mistaken for various orthopedic and neurosurgical diseases. A careful history of the character and duration of the pain and a careful examination of the peripheral circulation will always differentiate true intermittent claudication of the hip from any other disorder producing low back pain, hip pain or sciatica. Aortography is a valuable diagnostic aid.

References

1. Leriche, R. and Morel, A.: Syndrome of thrombotic obliteration of aortic bifurcation. *Ann. Surg.* **127**:193-206 (Feb.) 1948.
2. Greenfield, I.: Thrombosis and embolism of abdominal aorta. *Ann. Int. Med.* **19**:656-668 (Oct.) 1943.
3. Elkin, D. C. and Cooper, F. W., Jr.: Surgical treatment of insidious thrombosis of aorta; report of 10 cases. *Ann. Surg.* **130**:417-427 (Sept.) 1949.
4. Boyd, A. M. and Jepson, R. P.: External iliac thrombosis. *Brit. M. J.* **1**:1457-1460 (June 24) 1950.
5. Ortner, A. B. and Griswold, R. A.: Chronic occlusion of bifurcation of aorta. *Arch. Surg.* **61**:793-803 (Nov.) 1950.
6. Boyd, W. M.: Thrombosis of terminal aorta with aortitis and periaortitis. Report of 2 cases treated by aortectomy, lumbar sympathectomy and vena caval ligations. *Rocky Mountain M. J.* **47**:936-943 (Dec.) 1950.
7. Goodwin, J. F. and Petrie, E.: Insidious thrombosis of the abdominal aorta. *Brit. Heart J.* **13**:554-560 (Oct.) 1951.
8. Kekwick, A., McDonald, L. and Semple, R.: Obliterative disease of the abdominal aorta and iliac arteries with intermittent claudication. *Quart. J. Med.* **82**:185-200 (April) 1952.
9. Elliott, R. V. and Peck, M. E.: Thrombotic occlusions of aorta as demonstrated by translumbar aortograms. *J. A. M. A.* **148**:426-431 (Feb.) 1952.
10. Homans, John: *Circulatory Disease of the Extremities*. New York, MacMillan Co., 1939, p. 330.
11. Samuels, S. S.: *Management of Peripheral Arterial Diseases*. New York, Oxford University Press, 1950, p. 345.