

CLINICAL MANIFESTATIONS OF IDIOPATHIC HYPOPARATHYROIDISM

Report of a Case

RAY A. VAN OMMEN, M.D.
Department of General Medicine

IDIOPATHIC hypoparathyroidism is an infrequently diagnosed disease with a high morbidity and a low mortality. Although secondary hypoparathyroidism became a prominent clinical entity with the advent of thyroid surgery, the primary spontaneous type continues to be uncommon. The scarcity of reported cases of idiopathic hypoparathyroidism was brought into focus by Steinberg and Waldron¹ in 1952 when in their complete review of the literature they were able to find only 51 cases to which they added one case of their own. They adhered to the following criteria for the diagnosis of the disease: (1) low serum calcium level; (2) high serum inorganic phosphorus level (greater than 5.0 mg. per cent for adults and 7.0 mg. per cent for patients under 16 years of age); (3) absence of renal insufficiency; (4) normal bones on roentgenograms (in order to exclude infantile rickets or adult osteomalacia); and (5) chronic tetany. The following case presents many of the classic signs and symptoms of the disease.

CASE REPORT

A 58 year old, white, married woman was first admitted to the hospital on June 10, 1952, because of recurrent convulsive seizures during the preceding 27 years. The seizures were thoroughly characteristic of grand mal attacks except for an occasionally associated period of confusion and disorientation lasting for hours or for days which at times required emergency hospital care. The convulsions occurred three or four times yearly, and in between the more severe episodes she experienced frequent tightness and spasm of the muscles of the extremities. These painful spasms lasted for hours or for days and often confined her to bed or chair. Subsequently, the joints became very stiff, leading to marked limitation of motion, particularly of the hip joints. She had been aware of occasional wheezing in the throat, probably due to laryngeal spasm.

The patient also had noted failing vision for at least 15 years, and almost complete blindness had developed during the preceding four to five years, requiring extraction of a cataract from the right eye in January 1952.

Her dental condition had deteriorated in early adulthood, and she was edentulous at 30 years of age. Other complaints consisted of intermittent dysuria, hematuria, and pain in the right flank during the preceding five years.

The family history disclosed that childhood convulsions had occurred in four of the patient's ten children. In two of the four children available for study, normal blood calcium determinations were found.

Physical examination revealed a well-developed, obese woman, who appeared chronically ill and older than her stated age. The temperature and pulse rate were

normal. The blood pressure was 154/86. The skin was dry and the hair coarse. There were generalized muscular rigidity and spasm, great limitation of motion in the hips, and crepitation of the large joints. The joints of the right hand appeared ankylosed in a position of carpopedal spasm, a condition which had been present and stationary for approximately six years. Chvostek's and Trousseau's signs were positive. Ophthalmoscopic examination revealed an aphakic right eye. There was an almost mature cortical cataract of the left eye. Fundusoscopic examination revealed bilateral early papilledema. The remainder of the examination was essentially normal.

The serum calcium content was 4.9 mg. per 100 cc. and the serum phosphorus 6.8 mg. per 100 cc. An alkaline phosphatase determination was 5.6 Bodansky units. Pretreatment blood urea measurements were repeatedly within normal limits, and the urea clearance was normal. The urinalysis showed a heavy pyuria, and cultures of a catheterized urine specimen yielded a growth of *Esch. coli*. The hemogram was normal as were the serum proteins, serology, and plasma cholesterol.

A roentgenogram of the chest was essentially normal. An intravenous urogram revealed blunting of the calyces of the right kidney with retention of dye, suggestive of chronic inflammatory change. X-rays of the skeletal system showed degenerative changes in the lumbar spine, hips, and right knee. There was no demineralization of the bones. Roentgenograms of the skull were normal, and no intracranial calcifications were visualized.

The initial electrocardiogram was reported as showing a prolonged Q-T interval consistent with hypocalcemia.

The effect of the intravenous administration of 200 units of parathyroid hormone on the serum calcium and phosphorus is shown in figure 1.

Response to Parathyroid Hormone

	Fasting	After 200 U. Parathyroid Hormone I.V.			
		1 hr.	2 hr.	3 hr.	4 hr.
Calcium mg. %	8.2	8.6	8.6	8.9	9.2
Phosphorus mg. %	6.1	4.9	4.7	4.5	4.3

Fig. 1. The characteristic response of the serum calcium and phosphorus levels after the injection of parathyroid hormone in idiopathic hypoparathyroidism.

An electroencephalogram was reported as being borderline normal with no definite evidence of epilepsy or focal cortical lesion.

Initial treatment consisted of 6 drams of equal parts of calcium lactate and calcium carbonate daily with vitamin D, 150,000 units in divided doses. As illustrated in figure 2, the combination even with increased doses of vitamin D did not raise the serum calcium to satisfactory levels.

Dihydroxycholesterol promptly brought the serum calcium within normal range and

the electrocardiogram reverted to normal. The patient was given a high calcium—low phosphorus diet from the onset of therapy.

The urinary tract infection was successfully treated with antibiotics. Extensive physical therapy to the joints resulted in considerable improvement. At the time of her discharge on July 23, 1952, the patient was instructed to do her own daily Sulkowitch test in order to reduce the likelihood of overtreatment.

She returned to the Clinic on September 17, 1952, and reported marked subjective improvement. There had been no convulsions or other symptoms of tetany. The serum calcium was 10.2 mg. per 100 cc. and the Sulkowitch chart revealed the reactions had remained 2 plus on most occasions. She was much more alert mentally, was walking with the aid of a cane, and was beginning to do some of her own housework. A cataract was extracted from the left eye on September 22, 1952, and the patient had an uneventful recovery. When last seen on February 10, 1953, eight months after the initial visit, rehabilitation of the joints was progressing rapidly. Fundusoscopic examination revealed normal optic discs, and the serum calcium was within normal range. The therapy program remained unchanged. A communication from the patient on December 22, 1953, stated that she was feeling very well and was continuing her treatment schedule.

DISCUSSION

The etiology of idiopathic hypoparathyroidism is unknown. No hereditary factor has been established although three reported cases occurred in siblings.² Theories concerning the relationship of birth trauma and infection have been advanced. There appears to be no significant difference in the incidence between the sexes, but the onset of symptoms appears to be somewhat earlier in women. Symptoms usually appear in the first or second decade, the average age being approximately 17 years. The average time between the onset of symptoms and the time of diagnosis is about eight years. In some instances the diagnosis is delayed for considerably longer periods. One patient¹ had complained of symptoms for 31 years, and our patient had had symptoms for 27 years prior to the recognition of the underlying disorder.

The most commonly noted clinical manifestation of idiopathic hypoparathyroidism is chronic tetany. It is a prominent symptom in 78 per cent of the cases reported in the literature. Generalized convulsions are reported in 52 per cent of the cases and many are misdiagnosed as idiopathic epilepsy. Laryngeal spasm and bronchial spasm are commonly associated tetanic equivalents. The Chvostek's and Trousseau's signs are positive. In some patients, grand mal convulsions are accompanied by increased spinal fluid pressure and papilledema, and these findings may suggest the presence of a brain tumor.^{3,4} Papilledema is found in about 14 per cent of patients with idiopathic hypoparathyroidism and has been occasionally observed in surgical hypoparathyroidism. The papilledema usually regresses following therapy.

Although some authors, including Gotta and Odoriz,⁵ report that there are characteristic electroencephalographic changes in this disorder, it is not generally accepted that these changes are diagnostic of hypocalcemia. Following therapy, the electroencephalogram may or may not return to normal.

In idiopathic hypoparathyroidism, as in uncontrolled postoperative hypo-

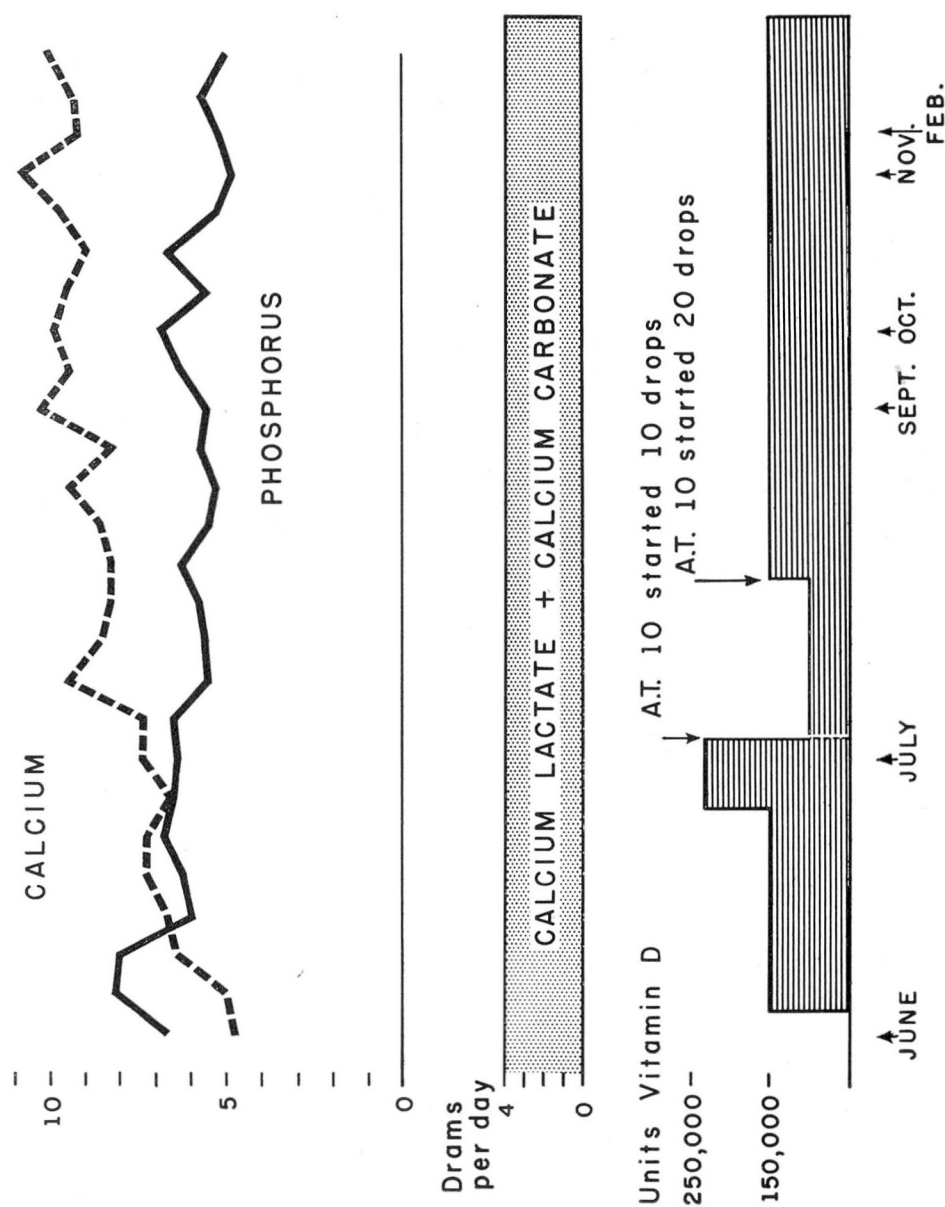


Fig. 2. Treatment chart of a patient with idiopathic hypoparathyroidism showing the serum calcium and phosphorus levels in relationship to therapeutic agents.

parathyroidism, cataracts are a common complication, occurring in about 50 per cent of the cases. Cataracts may develop even in extremely young patients having this disorder. Early diagnosis and adequate treatment to maintain the serum calcium in normal range are essential to prevent this complication.

Defects in dentition are a common accompaniment and have been recorded in one third of the cases. Other ectodermal dysplasias have been reviewed by Dietrich, Rice and Luton.⁶ The nails are frequently brittle, deformed, and show horizontal grooving. Adequate therapy causes prompt disappearance of these defects. The skin is often dry and rough, closely resembling that of a patient with myxedema. The hair is observed to be sparse and dry in 25 per cent of the reported cases.

Roentgenograms of the skeletal system are usually normal. Occasionally there may be some generalized increased density of bone. At times cerebral calcifications are present, most commonly in the region of the basal ganglia. These changes are believed to be due to the deposition of a basophilic homogeneous material in and about the media and adventitia of the smaller cerebral arteries, with subsequent calcification of the deposits.⁷ Subcutaneous calcification is rarely observed.

The electrocardiogram shows the typical findings of hypocalcemia with prolongation of the Q-T interval and normally shaped T wave.

Of the laboratory findings, hypocalcemia and hyperphosphatemia are the constant and diagnostic features. The average of the lowest serum calcium levels reported in previous cases is 5.6 mg. per 100 cc. and the highest serum phosphorus levels averaged 8.2 mg. per 100 cc. prior to treatment. The alkaline phosphatase determination is consistently normal.

There have been few opportunities for postmortem studies of this disease. Two cases showed complete absence of parathyroid tissue,^{4,8} and a third, on microscopic study,⁹ showed the parathyroid glands to be completely replaced by fat. This meager material supports the thesis that idiopathic hypoparathyroidism represents primary parathyroid failure. In contrast, a condition designated as pseudo-hypoparathyroidism, first described by Albright and his associates¹⁰ in 1942, represents not a deficiency in parathyroid hormone but rather a lack of response of the kidney to adequate concentrations of the hormone, i.e. end-organ failure. The administration of parathyroid hormone to patients with parathyroid deficiency causes phosphate diuresis and a fall in serum phosphorus with a rise in serum calcium which is in accordance with the concept of the primary site of action of this hormone. In pseudo-hypoparathyroidism, these changes do not occur, suggesting that there is an adequate amount of circulating parathyroid hormone and that the primary defect is a failure of end-organ response. This observation forms the basis for the use of the Ellsworth-Howard test¹¹ in differentiating these two conditions. Biopsies of the parathyroid glands of two patients with pseudo-hypoparathyroidism also support the basic physiologic difference in the etiologies of the two conditions.¹² In one case, glandular tissue appeared to be normal, and in the other it appeared to be hyperplastic. Reynolds and his associates¹³ have pointed out that in pseudo-hypoparathyroidism there is a tendency to shorter stature, shortening

of the long bones and metacarpals, and a greater incidence of metastatic calcification and mental deficiency. Fortunately, both of these diseases respond to therapy with dihydrotachysterol.

Treatment

The treatment of idiopathic hypoparathyroidism consists of measures to increase the serum calcium and, if necessary, to reduce the serum phosphorus. Maintenance of the serum calcium level within normal range is of primary importance for the prevention of cataracts and the control of tetany. The cornerstone of therapy is the administration of large doses of oral calcium. This can be accomplished by mixtures of calcium lactate and calcium carbonate powder, whereas the commercial wafers of dicalcium phosphate are totally ineffective in any practical dosage range. The calcium powder in doses of five to ten drams is dissolved in approximately one quart of boiling water, and the solution is taken in four divided doses each day. The serum phosphorus level is of lesser importance except for its indirect effect on calcium metabolism and the serum calcium level. Reduction of the phosphate concentration within the intestine promotes a favorable effect on calcium absorption. The serum phosphorus can be partially controlled by dietary measures and the administration of aluminum hydroxide to increase phosphorus excretion in the stool.

Large doses of vitamin D or dihydrotachysterol, which is often more effective, are prescribed with the supplemental calcium salts. The major action of dihydrotachysterol is to promote phosphorus diuresis and its secondary effect is to increase calcium absorption from the gastrointestinal tract. Vitamin D primarily increases calcium absorption in hypoparathyroidism. Although parathyroid hormone is true replacement therapy, it is not used because it is ineffective over long periods of time due to the development of antihormones. In addition, parathyroid hormone is expensive and requires parenteral administration.

SUMMARY

A case of idiopathic hypoparathyroidism is reported, and the clinical features and treatment of the disease are reviewed.

References

1. Steinberg, H. and Waldron, B. R.: Idiopathic hypoparathyroidism: Analysis of 52 cases, including report of new case. *Medicine* 31:133-154 (May) 1952.
2. Sutphin, A., Albright, F. and McCune, D. J.: Five cases (three in siblings) of idiopathic hypoparathyroidism associated with moniliasis. *J. Clin. Endocrinol.* 3:625-634 (Dec.) 1943.
3. Berezin, S. W. and Stein, J. D.: Idiopathic hypoparathyroidism; case simulating epilepsy and brain tumor. *J. Pediat.* 33:346-351 (Sept.) 1948.
4. Drake, T. G., Albright, F., Bauer, W. and Castleman, B.: Chronic idiopathic hypoparathyroidism; report of six cases with autopsy findings in one. *Ann. Int. Med.* 12:1751-1765 (May) 1939.

5. Gotta, H. and Odoriz, J. B.: Electroencephalogram in hypoparathyroidism with tetany and epilepsy. *J. Clin. Endocrinol.* **8**:674-686 (Aug.) 1948.
6. Dietrich, F. S., Rice, M. L., Jr. and Luton, E. F.: Clinical manifestations of idiopathic hypoparathyroidism; report of one case. *Ann. Int. Med.* **37**:1052-1063 (Nov.) 1952.
7. Camp, J. D.: Symmetrical calcification of the cerebral basal ganglia; its roentgenologic significance in diagnosis of parathyroid insufficiency. *Radiology* **49**:568-577 (Nov.) 1947.
8. Leonard, M. F.: Chronic idiopathic hypoparathyroidism with superimposed Addison's disease in child. *J. Clin. Endocrinol.* **6**:493-506 (July) 1946.
9. Cantarow, A., Stewart, H. L. and Morgan, D. R.: Chronic idiopathic parathyroid tetany. *Endocrinology* **24**:556-564 (April) 1939.
10. Albright, F., Burnett, C. H., Smith, P. H. and Parson, W.: Pseudo-hypoparathyroidism —an example of "Seabright-bantam syndrome"; report of three cases. *Endocrinology* **30**:922-932 (June) 1942.
11. Ellsworth, R. and Howard, J. F.: Studies on physiology of parathyroid glands. Some responses of normal human kidneys and blood to intravenous parathyroid extract. *Bull. Johns Hopkins Hosp.* **55**:296-308 (Nov.) 1934.
12. Albright, F. and Reifenstein, E. C., Jr.: *The Parathyroid Glands and Metabolic Bone Disease; Selected Studies.* Baltimore, The Williams and Wilkins Co., 1948, pp. 398.
13. Reynolds, T. B., Jacobson, G., Edmondson, H. A., Martin, H. E. and Nelson, C. H.: Pseudohypoparathyroidism: report of case showing bony demineralization. *J. Clin. Endocrinol.* **12**:560-573 (May) 1952.