

KERATOACANTHOMA: HISTOPATHOLOGIC CRITERIA FOR DIAGNOSIS

PHILIP SKIRPAN, M.D.*

and

JOHN R. HASERICK, M.D.

Department of Dermatology

KERATOACANTHOMAS appear as firm, white, keratotic nodules on the skin of the face or of the dorsum of the hand. They are characterized by rapid growth to maximum size and benign biologic behavior. On microscopic examination, under high-power magnification they possess some of the features of low-grade, superficial squamous cell carcinoma, and under low-power magnification they resemble to a degree molluscum contagiosum.

The disparity between the architecture and the behavior of keratoacanthomas has attracted the worldwide attention of dermatopathologists who have proposed numerous descriptive names for the lesions. For the most part their nomenclature reflects the superficial, benign nature of this group of tumors. Freudenthal¹ first suggested "keratoacanthoma"; MacCormac and Scarff² in their report of ten cases suggested "molluscum sebaceum"; and Poth³ suggested "tumor-like keratoses." A recent LANCET editorial⁴ noted the 76 cases described by Beare⁵ and suggested the name "molluscum pseudocarcinomatousum."

In an effort to establish definitive histopathologic criteria as a basis for the diagnosis of keratoacanthoma, we undertook a comparative histopathologic study of the biopsy specimens from the 14 cases of the lesion seen here since 1948.

Materials and Methods

Of approximately 42,000 surgical specimens screened for the presence of low-grade squamous-cell epitheliomata, 377 qualified; however, only 14 of the latter were lesions with both the macroscopic and the microscopic findings consistent with a diagnosis of keratoacanthoma.

Clinical Features

The diagnosis of keratoacanthoma was confirmed in ten men and four women. In seven patients the lesions occurred on the hand or wrist, and in the remaining seven they were present on the face: ear (two), lip (two), jaw (one), nose (one), and forehead (one). The ages of the patients ranged from 51 to 73 years, the average age being 59 years; eight patients were in the sixth decade. Five patients had associated or unrelated dermatologic complaints. The lesions had been present from four weeks to nine months, and were variously described

* Fellow in the Department of Pathology.

TABLE
Data on 14 Patients Having Keratoacanthoma

Age (yr.)	Sex	Site of Lesion	Duration of Lesion	Associated Skin Lesions	Treatment	Follow-up Period (mo.)
51	M	Hand	3 mo.	Contact dermatitis	Excision	None
52	F	Left hand	5 mo.	None	Excision	52
52	M	Wrist	2 mo.	Previous excision similar nodule	Excision	27
53	F	Hand	Not known	Contact dermatitis	Excision	1
53	F	Skin behind ear	4 mo.	None	Excision	18
53	M	Forehead	2 mo.	None	Excision	18
58	M	Jaw	4 mo.	None	Excision	31
58	M	Wrist	2 mo.	Infectious eczematoid dermatitis	Excision	7
63	M	Hand	9 mo.	None	Excision	31
63	M	Lower lip	6 wk.	None	Excision	14
64	M	Lip	1 yr.	None	Excision	46
71	M	Ear	2 mo.	Epithelioma of hand treated by x-ray 1941	Excision	9
72	M	Hand	Not known	None	Excision	67
73	F	Nose	4 mo.	None	Excision	3

by different observers as white, firm, hard, round, well-demarcated, warty, keratotic, crusted or scaled nodules that were about the size of a pea. All of the lesions were treated by surgical excision. No recurrences were noted in 13 patients followed from 1 to 67 months; in one patient there was no follow-up (table).

Histopathology

The lesion was characterized histopathologically by: (1) projection above the plane of the adjoining epidermis; (2) hyperkeratosis of the adjoining epidermis; (3) a central crater, with overhanging edges in some instances; (4) pseudo-epitheliomatous hyperplasia marginally and acanthotic, squamous-cell carcinoma-like nests centrally; and (5) a slight-to-moderate chronic inflammatory reaction in the surrounding corium. In addition, the squamous-cell nests contained prominent intercellular bridges, central keratinization, little central necrosis, and few mitotic figures. Periodic acid-Schiff stain⁶ failed to reveal the presence of fungi. However, the cells of the stratum granulosum and the squamous-cell nests contained prominent, cytoplasmic, periodic acid-Schiff positive granules. In contrast most of the cells of the squamous-cell nests in overt carcinomas did not contain such granules. The most significant points differentiating them from squamous cell carcinomas were:

- (A) The central crater and verruciform appearance.
- (B) The superficial resemblance to molluscum contagiosum.
- (C) The completely differentiated appearance of the hypertrophic squamous-cell elements.

(See figures 1, 2 and 3).

DISCUSSION

The concept of benign, squamous-cell carcinoma-like lesions of the skin is not new, but it rarely has been discussed in the American literature. In 1936, MacCormac and Scarff² reviewed ten cases of molluscum sebaceum that were easily eradicated by excision or the use of CO₂ pencil; they described the nodule as a hemisphere that remains stationary in size (approximately that of a small nut), is centrally depressed and has an adherent scale. They reported that the lesion occurred with equal frequency in both sexes.

Poth³ excellently described a case of tumor-like keratoses that occurred as multiple nodules on the skin of the hand following exposure to sun and sea water. Grossly, the tumor appeared round, firm, translucent, and pearly. Tissue sections were examined by a number of pathologists whose diagnoses varied: "exuberant verruca vulgaris" (H. Montgomery); "dyskeratosis and hyperkeratosis" (U. J. Wile); and "squamous-cell carcinoma, Grade I" (R. C. Wanstrom and G. H. Belote). Discussing Poth's case, Montgomery calls attention to the presence of epithelial proliferation and regular pearl formation in other instances of pseudo-epitheliomatous hyperplasia, including bromoderma, blastomycosis, and the edges of nodular ulcerative syphiloderm. Wile's description of the histopathologic changes in this case is exceptionally clear, and

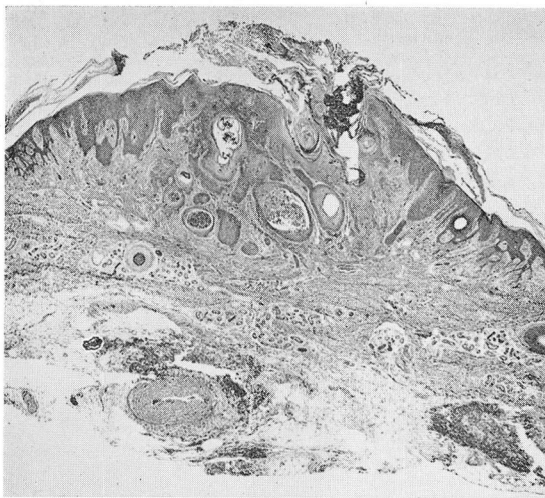


Fig. 1
(X 14)

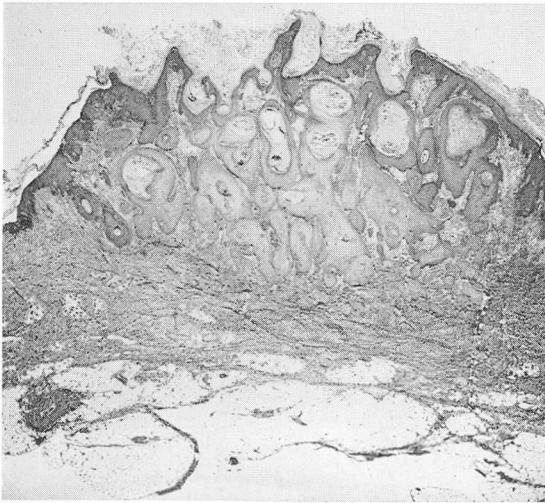


Fig. 2
(X 9)

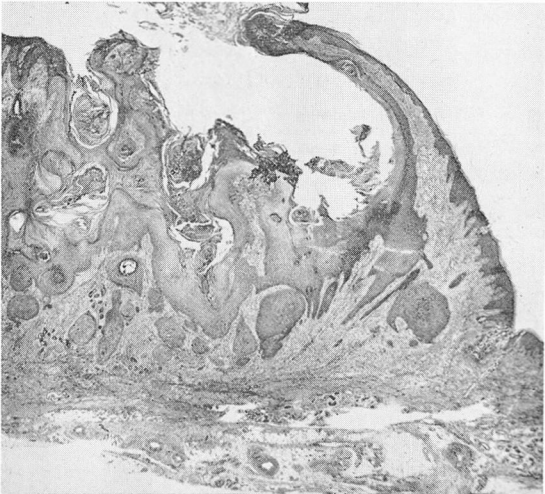


Fig. 3
(X 14)

Figs. 1, 2, and 3. Three examples of keratoacanthoma. Note central crater and verruciform appearance, molluscum architecture, and well-differentiated squamous-cell elements.

illustrates the marked degree of differentiation of the lesion by noting the conspicuousness of the stratum granulosum, and the large prickle cells with well-exhibited spines. In Poth's case all of the tumors involuted spontaneously eight months after their appearance; no treatment was instituted.

Beare⁵ in reviewing 76 cases of molluscum sebaceum pointed out that the stretched epithelium in the outer area of the tumor tempts one to make a diagnosis of malignancy.

The etiology of the lesion is not known. Attempts to demonstrate inclusion bodies or fungi have been unsuccessful in our cases. Poth could not transmit the tumor to laboratory animals, nor could he reproduce it in a patient by cutaneous inoculation of extracts of tumor. A viral etiology has not been established.

The prognosis is always excellent, and the lesions have never been known to recur, as cited by Poth,³ Smith,⁷ Musso and Gordon.⁸ The clinical observation of the limited growth potential of these rare lesions, their benign and at times regressive course indicate they are separate and distinct from squamous cell carcinoma. The term *keratoacanthoma* is an appropriate designation. The diagnosis can be established on the basis of the histopathologic criteria set forth.

SUMMARY

The clinical and histopathologic findings in 14 cases of keratoacanthoma are presented. The lesion, which is similar to "molluscum sebaceum" or "molluscum pseudocarcinomatousum" described in the British literature, is a benign squamous-cell growth of unknown etiology. It is characterized by a verruciform appearance and a superficial resemblance to the lesion of molluscum contagiosum. Histologic features of differentiation from squamous cell carcinoma are outlined.

References

1. Freudenthal: Cited by Poth, D. O.³
2. MacCormac, H. and Scarff, R. W.: Molluscum sebaceum. *Brit. J. Dermat.* **48**: 624-626 (Dec.) 1936.
3. Poth, D. O.: Tumor-like keratoses; report of case. *Arch. Dermat. & Syph.* **39**: 228-238 (Feb.) 1939.
4. Editorial: Molluscum pseudocarcinomatousum. *Lancet* **2**: 816-817 (Oct. 17) 1953.
5. Beare, J. M.: Molluscum sebaceum. *Brit. J. Surg.* **41**: 167-172 (Sept.) 1953.
6. Hotchkiss, R. D.: Microchemical reaction resulting in straining of polysaccharide structures in fixed tissue preparations. *Arch. Biochem.* **16**: 131-141 (Jan.) 1948.
7. Smith, J. F.: Case of multiple primary squamous-celled carcinomata of skin in young man, with spontaneous healing. *Brit. J. Dermat.* **46**: 267-272 (June) 1934.
8. Musso, L. and Gordon, H.: Spontaneous resolution of molluscum sebaceum. *Proc. Roy. Soc. Med.* **43**: 838-839 (Nov.) 1950.