

BENIGN ULCERS OF THE GREATER CURVATURE OF THE STOMACH

Report of Two Cases

CHARLES H. BROWN, M.D.
Department of Gastroenterology

and

ANTHONY D. INTRIERE, M.D.*

BENIGN ulceration along the greater curvature of the pars media of the stomach is uncommon. Levin and associates¹ collected from the literature 20 cases of histologically proven benign ulcers of the greater curvature and added one case of their own in 1949. Griffin² found 32 cases of proven benign ulceration along the greater curvature in the literature to 1954, and added three cases: two of which were in the antrum and one in the pars media of the stomach. Danstrom, Lowry and Colvert³ recently reported five cases, all verified by microscopic study. This makes a total of 40 cases of benign, histologically proven, gastric ulcer along the greater curvature, exclusive of autopsy studies, which have been reported.

The percentages of gastric ulcers along the greater curvature that prove to be malignant vary considerably in different series. Silk and associates⁴ reported 18 patients with ulcers along the greater curvature, 10 of which were benign and 8 malignant. They commented that benign ulcer along the greater curvature often is associated with duodenal ulcer or with benign ulcer along the lesser curvature of the stomach. Boudreal and associates⁵ in a study of autopsy material reported that 47 of 247 gastric ulcers were on the greater curvature and that 23 of these (49 per cent) were malignant. Smith and associates⁶ reported that of 12 ulcers described by the pathologist as being along the greater curvature, 8 were malignant; thirteen additional ulcers, however, were described by the roentgenologist as being along the greater curvature. These reports suggest that there is a high ratio of malignancy in ulcerative lesions along the greater curvature of the stomach.

Recently we have observed two patients with benign ulceration along the greater curvature of the pars media of the stomach. Because of the uncommon occurrence of such lesions, and because of the problem as to whether treatment of these lesions should be medical or surgical, we are reporting these two cases.

* *Fellow in the Department of Internal Medicine.*

CASE REPORTS

Case 1. A 54-year-old man was first seen at the Cleveland Clinic on March 9, 1951, because of epigastric distress that occurred one hour postprandial. The discomfort had been consistently relieved by food and antacids. Ten days prior to examination, the patient had noted two black stools. The past history revealed that in 1943 a thyroidec-tomy had been performed for hyperthyroidism, and that in 1947 he had had a duodenal ulcer that had responded promptly to medical treatment.

Findings on physical examination were normal. Laboratory studies revealed the hemoglobin to be 14 Gm./100 ml. Gastric analysis, with alcohol as a stimulant, showed 32 units of free and 46 units of total acidity. On roentgenographic examination of the stomach an ulcer crater, 1.2 cm. in diameter and .7 cm. in depth, was visualized along the greater curvature of the pars media; there was an incisura opposite the ulcer crater and the duodenal bulb was deformed (Fig. 1, a and b). An ulcerating neoplasm was suspected.

Surgical treatment was advised, and on March 26, 1951, 15 days after initial examination, a subtotal gastric resection was performed. At operation, two gastric ulcers, each 8 mm. in diameter, were apparent. Each ulcer was "punched out" with concave, yellowish-tan, irregular bases and with the mucosa heaped up at the edges. A bandlike area of depressed, congested, gastric mucosa connected the two ulcers, one of which was situated 1 cm. from the lesser curvature on the posterior wall, and the other of which was located along the greater curvature. Multiple microscopic sections disclosed no evidences of malignancy.

The patient had an uneventful postoperative course until two months after the gastric resection when he suddenly developed acute appendicitis. A gangrenous appendix was immediately removed. When the patient was last seen on September 12, 1954, more than three years after the gastric resection, he was well although he had some dietary idiosyncrasies.

Comment: In view of the observation of Silk and his associates⁴ that benign ulcer of the greater curvature often is associated with duodenal ulcer or with benign ulcer of the lesser curvature, the history of duodenal ulcer and the second ulcer near the lesser curvature in this patient are interesting.

Case 2. A 60-year-old woman was admitted to the hospital on March 19, 1954, with a two-month history of postprandial bloating and belching. Three weeks before admission she had developed nausea and vomiting. Her appetite had been poor and she had lost 20 pounds in weight.

Findings on physical examination were essentially normal but the blood pressure was 200/120 mm. Hg. Laboratory studies showed a moderate anemia: hemoglobin was 9.2 Gm./100 ml.; red blood cell 4,140,000, and white blood cell count 7400 per cu. mm. Stools were positive for occult blood. Gastric analysis, with alcohol as a stimulant, showed 26 units of free and 36 units of total acidity.

Roentgenographic studies (Fig. 2, a and b) were reported as follows: the chest was normal except for a slight cardiac enlargement. The stomach was distended and contained food. The distal part of the stomach, for an area of about 5 cm. was markedly constricted in its entire circumference. A small ulceration was thought to be present at the proximal part of this constricted area on the greater curvature. Diverticulosis of the colon was the only abnormal finding on cholecystograms and barium enema studies. The preoperative diagnosis was: annular ulcerating neoplasm of the prepyloric part of the stomach.

Surgical treatment was advised, and subtotal gastric resection was performed on March 25, six days after admission. Gross examination of the stomach revealed four

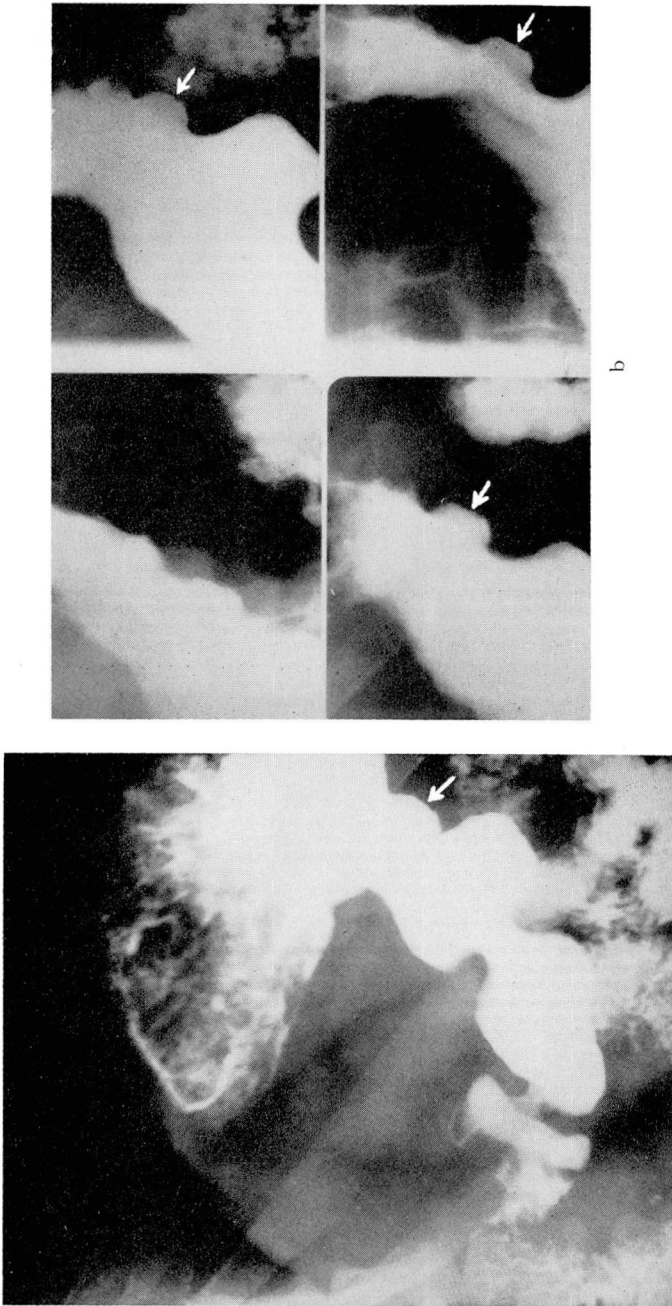


Fig. 1. (Case 1) Benign gastric ulcer.

a. Roentgenogram showing ulcer (arrow) along the greater curvature of the mid-portion of the stomach. The ulcer near the lesser curvature is not visualized. b. Multiple spot films showing the ulcer along the greater curvature (arrow). Again the ulcer near the lesser curvature is not visualized. There is a suggestion of a meniscus sign and an apparent filling defect just distal and proximal to the ulcer. The appearance and the location of the ulcer suggested that it was malignant.

The roentgenograms were supplied through the courtesy of Dr. John R. Hannan, 10515 Carnegie, Cleveland, Ohio.

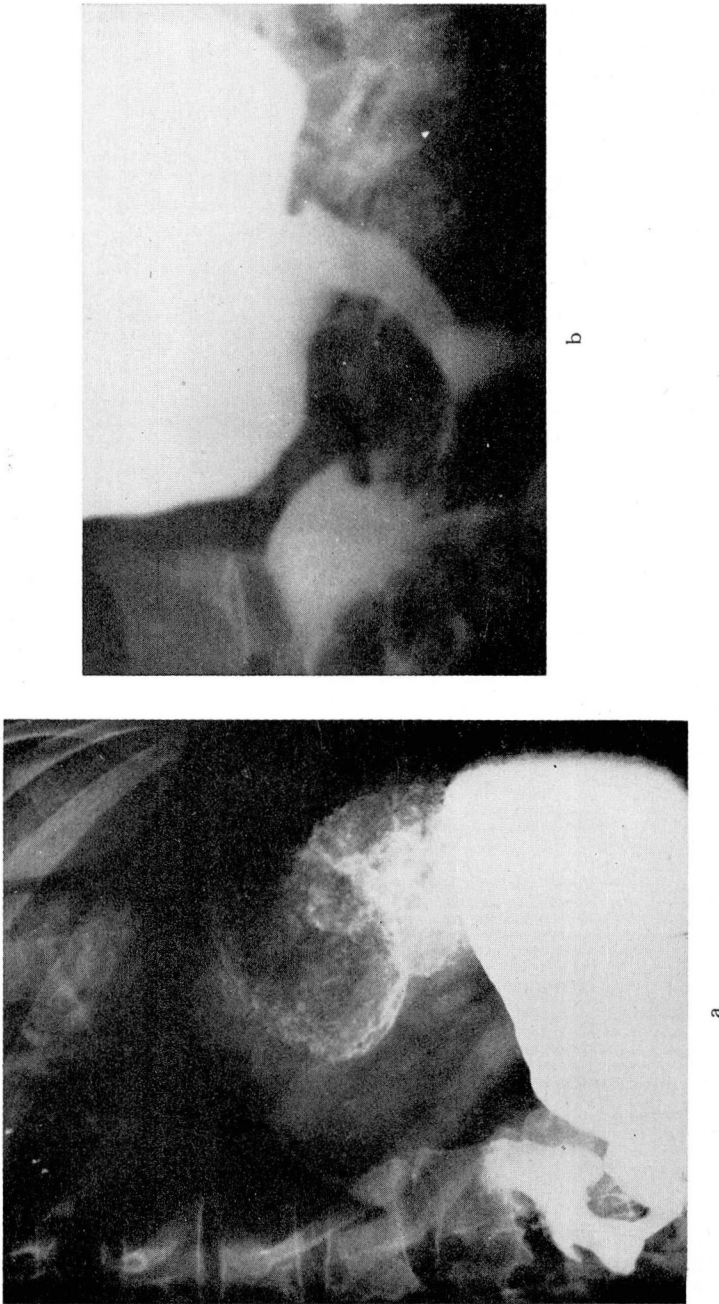


Fig. 2. (Case 2) Multiple benign gastric ulcer.

a. Barium meal roentgenogram showing marked deformity of the distal antrum, suggesting an annular constricting neoplasm.
 b. Spot film of the antrum of the stomach showing marked narrowing of the antrum, most compatible with neoplasm. The four gastric ulcers are not visualized. Ulceration in the stomach may cause marked antral spasm and even gastric retention due to the spasm, even though the ulcer may be in the upper two thirds of the stomach. The spasm of the antrum, as in this case, may simulate carcinoma.

ulcers. Two ulcers (2 cm. and 2.5 cm. in diameter, respectively) were situated on the greater curvature of the stomach just proximal to the antrum. The other two ulcers, each 0.3 cm. in diameter, were "kissing" ulcers, one located on the anterior wall and the other on the posterior wall just proximal to the antrum. Multiple sections of the ulcers revealed no evidence of malignancy, nor was there any evidence of malignancy in the antrum or in the pylorus.

The patient was discharged from the hospital ten days after the operation. She had an uneventful postoperative course and when last seen, six months after surgery, was entirely asymptomatic.

Comment: The deformity in the antrum of the stomach, which on roentgenographic study was strongly suggestive of malignant neoplasm, resulted from spastic phenomena secondary to the four gastric ulcers. Marked spasm of the antrum of the stomach, and even gastric retention, can occur in association with an ulcer higher in the stomach. We have seen several patients each of whom had gastric retention caused by spasm of the pylorus and antrum that was associated with gastric ulceration near the cardia of the stomach.

Of the four ulcers in this patient, only one had been roentgenographically visualized.

DISCUSSION

Each of these patients had benign ulceration along the greater curvature of the pars media of the stomach, and each had multiple gastric ulcers, one having two and the other four. In each case, the multiplicity of the ulcers was discovered only at operation and their benign nature subsequently was established by histologic study. Both patients had been advised to undergo surgery because of indications of possible malignancy on roentgenographic and other clinical examinations. Gastrosopic examinations were not performed because we believed that, on the basis of other evidence, surgery was warranted regardless of possible gastrosopic findings.

We have shown previously that malignant transformation of benign gastric ulcers does occur, but that such transformation is rare.⁷ The problem of gastric ulcers is not whether a specific ulcer will become malignant, but whether it is malignant now—that is, the differential diagnosis of benign and malignant ulcers. For typical benign ulcers along the lesser curvature, we believe that a trial of adequate medical treatment with a careful follow-up is indicated.⁸

Many authors, (e.g. references 9, 10, 11) advocate surgical treatment for every lesion of the greater curvature of the stomach because of the high incidence of malignancy. Bockus¹¹ stated that a benign ulcer niche rarely projects from that region in the usual roentgenograms, and he advocated considering and treating all such lesions as malignant. Kennedy and Beck⁹ stated that only after histologic examination of the resected lesion is it possible to determine diagnostically that ulceration of the greater curvature of the stomach is benign.

The possibility of gastric malignancy of the greater curvature cannot be excluded or confirmed by roentgenographic examination, by gastrosopic examination, or even by inspection of the stomach at operation. We have seen several cases in which frozen sections at the time of operation showed no evidence

of neoplasm, but permanent sections later disclosed the carcinoma. Consequently, if any findings from clinical, roentgenographic or gastroscopic examination are suggestive of neoplasm, surgical treatment should be advised. The high incidence of carcinoma along the greater curvature necessitates that all such lesions be regarded and treated as malignant.

SUMMARY AND CONCLUSIONS

1. Benign ulcer along the greater curvature of the pars media of the stomach is uncommon.

2. Two cases of benign ulcer of the greater curvature are presented. Both patients had multiple gastric ulcers.

3. Because of the high incidence of neoplasm and the low incidence of benign ulcer along the greater curvature of the stomach, we believe that surgery is indicated for all lesions located in that region.

References

1. Levin, E., Kirsner, J. B., Clark, D. and Palmer, W. L.: Benign ulcer of the greater curvature of the stomach (report of a histologically proven case). *Gastroenterology* **13**: 166-169 (August) 1949.
2. Griffin, B. G.: Benign ulcer of the greater curvature of the stomach. *Gastroenterology* **27**: 178-182 (August) 1954.
3. Danstrom, J. R., Lowry, D. C. and Colvert, J. R.: Benign gastric ulcer of the greater curvature. *Am. J. Roentgenol.* **72**: 426-431 (Sept.) 1954.
4. Silk, A. D., Blomquist, O. A. and Schindler, R.: Ulcer of the greater gastric curvature. *J.A.M.A.* **152**: 305-307 (May 23) 1953.
5. Boudreal, R. P., Harvey, J. P., Jr. and Robbins, S. L.: Anatomic study of benign and malignant gastric ulcerations. *J.A.M.A.* **147**: 374-377 (Sept. 29) 1951.
6. Smith, F. H., Boles, R. S., Jr. and Jordan, S. M.: Problem of the gastric ulcer reviewed: study of 1000 cases. *J.A.M.A.* **153**: 1505-1508 (Dec. 26) 1953.
7. Brown, C. H., Fisher, E. R. and Hazard, J. B.: Relation between benign ulcer and carcinoma of stomach; report of eight cases of malignant transformation. *Gastroenterology* **22**: 103-111 (Sept.) 1952.
8. Brown, C. H.: Benign ulcer and carcinoma of the stomach. *J. Am. Geriatrics Soc.* **1**: 177-189 (March) 1953.
9. Kennedy, G. R. and Beck, E.: Benign ulcer of the greater curvature of the stomach. *Am. J. Surg.* **76**: 429-433 (Oct.) 1948.
10. Matthews, W. B.: Peptic ulcers involving the greater curvature of the stomach. *Ann. Surg.* **101**: 844-855 (March) 1935.
11. Bockus, H. L.: *Gastro-enterology*. Vol. 1, Philadelphia, Saunders and Co., 1946, p. 420.