

SURGERY FOR METASTATIC NEOPLASTIC DISEASE IN THE LUNG

Review of 38 Cases

LAURENCE K. GROVES, M.D., and DONALD B. EFFLER, M.D.

Department of Thoracic Surgery

METASTATIC neoplastic disease in the lung ordinarily is not a surgical problem. The consideration of surgery arises only under exceptional circumstances. The lungs are a common site of metastatic neoplasms. This frequency is readily explainable on anatomic and physiologic bases. Roentgenography offers unique ability to screen the lungs for disease of many types, and has certainly served to emphasize the frequency of pulmonary metastatic neoplastic disease. The routine use of roentgenograms of the chest in the follow-up of patients having cancer reveals a significant number of metastases, and also the great increase in the use of periodic survey films brings to light a large group of pulmonary neoplasms, a number of which turn out to be metastatic from latent primary tumors. Also a diffuse pulmonary lesion may on occasion prove to represent atypical neoplastic disease.

We have performed thoracotomies on a number of patients having metastatic disease in the lung. In an effort to define the surgical indications and to evaluate the results, we have reviewed the findings in 38 cases in which neoplastic tissue considered to be metastatic in origin (Table 1) was obtained. A number of additional cases have been excluded in which histopathologic findings were indeterminate as to primary source of the lesion, and the clinical picture was consistent with primary bronchogenic neoplasm. A review of these 38 cases has permitted the definition of the broad surgical indications discussed below, and we believe that the results justify the continued use of surgical treatment in carefully selected patients.

Indications for Surgery

The indications for surgery in these patients can be broadly grouped as follows:

1. *Diffuse or multicentric disease (biopsy as a planned minimal procedure for diagnosis or confirmation of suspected diagnosis).*
2. *Solitary, circumscribed, "coin" lesion.*
3. *Suspected solitary neoplastic metastasis.*
4. *Presumed primary pulmonary neoplasm.*
5. *Metastatic neoplastic lesions obstructing a bronchus (operation, usually clearly for palliation only).*

Table 1.—*Analysis of 38 cases of metastatic neoplastic disease in the lung*

Operative procedure	No. of cases	Indications for surgery, no. of cases				
		Diffuse or multicentric disease	Solitary, circumscribed, "coin" lesion	Suspected solitary metastasis	Presumed primary neoplasm	Metastatic obstruction of bronchus
Lung biopsy as a planned minimal procedure	9	9	—	—	—	—
Exploratory thoracotomy with biopsy	11	—	—	2	9	—
Lobectomy or lesser resection	11	—	2	7	—	2
Pneumonectomy	7	—	—	4	1	2
TOTAL	38	9	2	13	10	4

All of the cases in this series can be classified in one of the above categories. There are, however, two additional situations which are worthy of mention in a discussion of this general subject: (1) a patient may have two separate primary carcinomas, and a history of malignancy elsewhere does not preclude the development of a primary bronchogenic carcinoma; (2) a pulmonary neoplastic lesion may be primary and the lesion elsewhere metastatic, a situation most frequently encountered at craniotomy.

The operative procedures performed in our 38 patients may be grouped as follows:

1. *Lung biopsy as a planned minimal procedure—9 patients*
2. *Exploratory thoracotomy with biopsy—11 patients*
3. *Lobectomy or lesser resection—11 patients*
4. *Pneumonectomy—7 patients*

ANALYSIS OF CASES

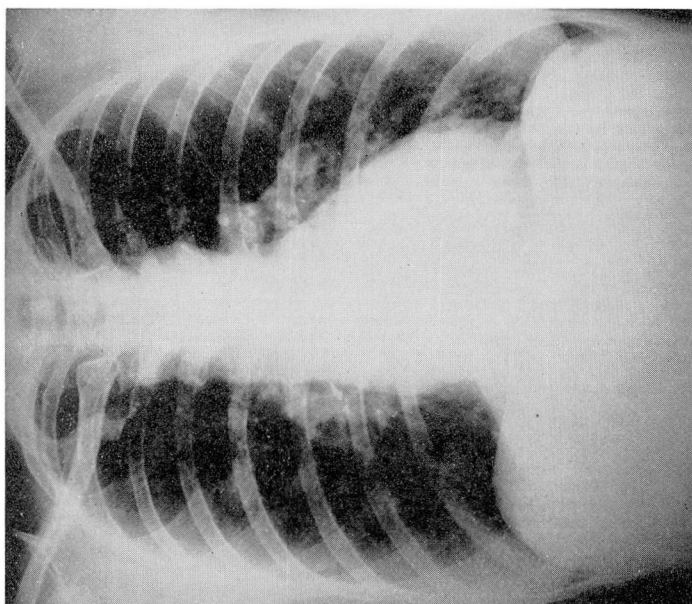
Diffuse or Multicentric Disease

Nine patients in our series underwent lung biopsy. Our procedure for biopsy is to make a small anterior intercostal thoracotomy, after local anesthesia with endotracheal intubation and mild general analgesia. For the past several years we frequently have employed this procedure for diagnostic purposes. Of the nine patients, five had had treatment for previous malignancy at a site other than the lungs, and biopsy was performed for definitive diagnosis because the clinical and roentgen findings were indeterminate. Two of the five patients had had removal of a carcinoma of the breast five and seven years, respectively, before lung biopsy; one patient had had an abdominoperineal resection for carcinoma of the rectum five years before; one had had irradiation therapy for carcinoma of the cervix one year before; and one had had an adenocystic salivary tumor removed 11 years before lung biopsy (Fig. 1).

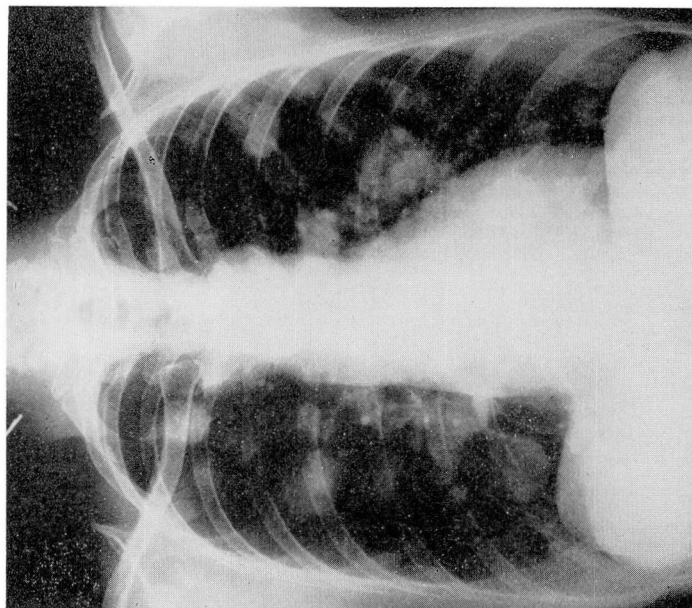Two other patients of the nine had multiple bilateral nodular densities throughout both lung fields, but in each the primary source of the metastasis was obscure. In each instance, histoplasmosis had been considered as a possible diagnosis. Biopsy in one of these patients, a 27-year-old man, showed an undifferentiated malignant neoplasm consistent with alveolar soft-part sarcoma¹ (Fig. 2). The other patient had an adenocarcinoma; the primary source of which never was found; postmortem examination was not performed.

The remaining two patients probably had primary bronchogenic adenocarcinoma with hematogenous metastases throughout both lung fields. However, the preoperative roentgenograms in one of these patients revealed a diffuse parenchymal infiltration that was believed to represent a pneumoconiosis (silicosis) (Fig. 3).

Lung biopsy had no significant therapeutic value for these patients (with the possible exception of one who had metastatic carcinoma of the breast, whose



(a)



(b)

Fig. 1. Roentgenograms obtained in 1951 (a) and in 1955 (b). (The patient had had an adenocystic parotid tumor removed in 1940). In 1951 a lung biopsy confirmed that the pulmonary nodules were histopathologically identical to the original tumor. The patient has no symptoms in the chest, but has pain from local recurrence at the primary site.

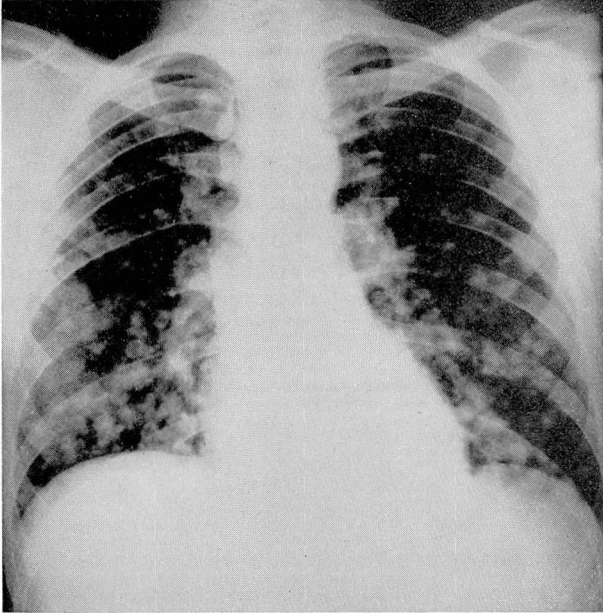


Fig. 2. Roentgenogram in a completely asymptomatic 27-year-old man. Diagnostic lung biopsy showed an alveolar soft-part sarcoma, and the patient subsequently died of disseminated neoplasm.

condition briefly improved on hormonal therapy); however, we believe that this minimal operative procedure had great diagnostic and prognostic value. In several instances, the histopathologic findings were a distinct surprise.

Solitary, Circumscribed, "Coin" Lesions

Approximately 50 per cent of coin lesions are found to be malignant when no calcium is apparent on roentgenograms.² Some of these malignancies are metastatic. The problem of an asymptomatic solitary lesion of the chest is being thought of more and more in terms of an aggressive surgical approach. Most of the patients who had circumscribed lesions in this series had a recent history of extrapulmonary malignancy, and are grouped in the category of *Suspected Solitary Metastasis*. However, in two patients the history of malignancy was not elicited until after removal of the pulmonary metastasis; these two cases are examples of the so-called *coin* lesion.

One of these patients, a 68-year-old woman, was found to have an oval mass, 4 cm. in diameter, in the left upper lobe, on roentgenograms taken because of recent minor hemoptysis. Papillary adenocarcinoma was found in the resected lobe. Ten years previously the patient had undergone hysterectomy, and on further investigation it was learned that a carcinoma, probably of ovarian

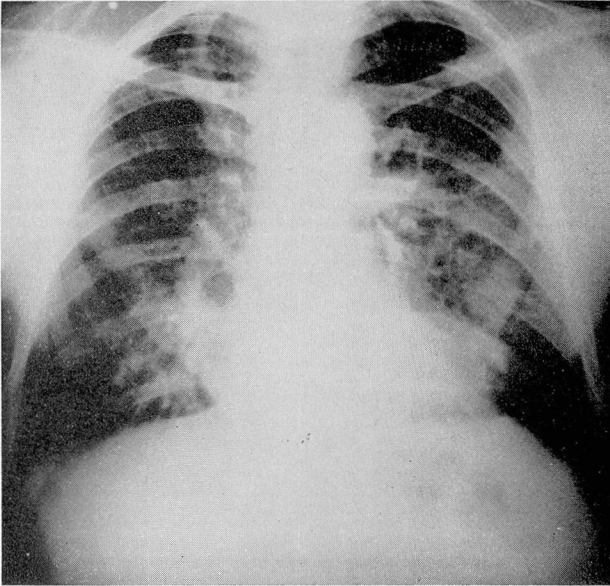


Fig. 3. Preoperative roentgenogram showing diffuse parenchymal infiltration believed to represent silicosis. The histopathologic findings were adenocarcinoma, probably of bronchogenic origin with hematogenous metastasis.

origin, had been removed at that time. The histopathologic material of both operations was subsequently compared and found to be identical. The patient is well two and one-half years following lobectomy.

The other patient underwent removal of a large solitary nodule from the left lower lobe. On histopathologic examination, the nodule proved to be a hemangiopericytoma. On reviewing the history and histopathologic material previously obtained, it was found that 13 years before thoracotomy a lesion of identical nature had been removed from the skin of the patient's back. Two years after thoracotomy, 15 years after the initial operation, a much smaller nodule was removed from the right lung, that also was identical to the original skin lesion.

Suspected Solitary Metastasis

In 13 of the 38 patients who underwent thoracotomy, the chief surgical indication was hope for cure of suspected solitary metastasis. Four of the 13 patients underwent pneumonectomy, seven lobectomy or lesser resections, and two only an exploratory thoracotomy with biopsy. Ten of the 13 patients had apparently solitary lesions, 1 had two lesions in the same lobe, and 2 each had a solitary lesion on each side. The two who underwent only exploration with biopsy were found at the time of surgery to have multiple, very small lesions, in addition to the larger readily apparent ones.

We believe that the minimal resection that allows total removal of a

metastatic lesion with a margin of normal tissue on all sides generally is indicated. However, in 4 of the 13 patients pneumonectomy proved necessary because of technical or anatomic considerations. One of the four patients was an operative mortality; he died after a right pneumonectomy had been performed for two oval lesions in the right upper lobe, which had appeared two years after a laryngectomy for carcinoma of the hypopharynx. Hilar nodes of the resected specimen at pneumonectomy were involved with metastatic cancer, and at postmortem examination adrenal and renal metastases were found. Two patients underwent pneumonectomy four, and five and one-half years, respectively, after combined abdominoperineal resections for rectal carcinoma. One of the two patients died ten months after pneumonectomy, of cerebral metastases; the other was well two years after pneumonectomy but subsequently was lost to follow-up. The fourth patient in the pneumonectomy group was operated upon three years after hysterectomy for adenocarcinoma. She died of spinal metastases nine months after pneumonectomy. Thus, in this small group, three of the four patients who underwent pneumonectomy were known to have had residual carcinoma at the time of death.

A more optimistic picture is seen in those seven patients who underwent lobectomy or lesser resections. Six still are living, but in three of these the postoperative follow-up has been less than a year. The one patient who died was a 24-year-old man who had a very large solitary lesion in the left lower lobe and a smaller one in the right middle lobe. Search for a primary source of the lesion was unavailing. A left lower lobectomy was performed for both diagnosis and treatment. During surgery, findings on frozen section established the diagnosis as embryonal carcinoma consistent with testicular origin; an extremely small, essentially nonpalpable, primary tumor was found in the testes and removed by orchiectomy. Postoperative irradiation was ineffective in the treatment of the lesion in the right lung; and six months after the first operation, middle lobectomy was performed. The patient died one year after the initial thoracotomy, with extensive pulmonary metastases.

One of the six living patients is well a year following wedge resection of a cylindromatous adenocarcinoma in the right lower lobe, which was metastatic from a parotid tumor first treated seven years before. She has also had resections of two cervical recurrences. In the second living patient, a small metastasis in the left upper lobe was resected approximately one year following amputation for hemangiopericytoma of the left femur. Fourteen months after resection, a second lesion in the right upper lobe appeared and was resected. The patient is well more than a year and one half following the second thoracotomy. The third living patient underwent right nephrectomy for a renal cell carcinoma in 1943. Seven years later, in 1950, he developed symptoms of an intracranial neoplasm, and a roentgenogram showed a lesion in the left lower lobe of the lung. He underwent craniotomy with resection of a cerebral metastasis and two weeks later a left lower lobectomy. This patient is well five and one-half years after the removal of the metastases. Two of the three patients who were recently treated, underwent resections of metastases from carcinoma of the breast; the third underwent resection of a metastasis of colonic origin.

The surgery performed on the remaining two patients who underwent exploration for what were presumably solitary metastases, represented rather heroic attempts to help young people. One was a 13-year-old girl who had a synovial sarcoma of the knee; the other was a 30-year-old woman who had chorio-epithelioma that apparently had been controlled in the abdomen.

Presumed Primary Neoplasm

In this group are included patients operated upon for definitive resection and a number of patients in whom the lesion if found to be neoplastic was certainly unresectable but in whom the diagnosis was obscure. One patient having a mass extending into the left hilum and negative bronchoscopic findings, underwent pneumonectomy for a neoplasm that on histopathologic study proved to be typical renal cell carcinoma. A right nephrectomy was performed shortly after pneumonectomy, but the patient died approximately six months after pneumonectomy of disseminated carcinoma in the retroperitoneal area. Nine additional patients underwent only exploration with biopsy for lesions that initially were believed to be primary carcinoma but that proved to be metastatic. In most of these cases the confusion concerning the diagnosis arose because the lesion caused segmental obstructive pneumonitis, a condition usually associated with bronchogenic neoplasms.

Metastatic Obstruction of a Bronchus

Ordinarily, metastatic lesions, in contrast to primary bronchogenic carcinoma, occur in the pulmonary parenchyma and do not involve the tracheo-bronchial tree. However, occasionally a metastatic lesion compresses or ruptures into a bronchus. If the compression or rupture is sudden, the patient may immediately develop respiratory symptoms similar to those seen in acute atelectasis. If the obstruction develops slowly, it causes obstructive pneumonitis and varying degrees of respiratory embarrassment. In rare instances resection of the obstructed portion of the lung may offer worthwhile palliation. For example, one of our patients had undergone left nephrectomy for renal cell carcinoma. When he was seen five years later, he had a one-year history of dyspnea, chronic cough with hemoptysis, and coughing up of small fragments of tissue. Roentgenograms of the chest showed multiple bilateral nodules, a collapsing left upper lobe, and a spontaneous left pneumothorax. On three separate occasions, he was bronchoscoped and large casts of tumor that had been protruding from the orifice of the left upper lobe were removed. Subsequently, he underwent left upper lobectomy. The patient's symptoms disappeared following that procedure, and he remained well for more than two years before his death.

Another patient with a known unresectable renal carcinoma of three years'

duration suddenly developed acute respiratory distress; at bronchoscopy the left main bronchus was totally occluded by necrotic neoplastic tissue. The occlusion was somewhat alleviated by removal of a large amount of tissue through the bronchoscope. However, he was extremely desirous of several more months of life for business reasons and elected to undergo pneumonectomy. He lived for six months after pneumonectomy.

A third patient had undergone abdominoperineal resection for adenocarcinoma. Eleven years later he developed intractable cough and shortness of breath. He was found to have multiple bilateral pulmonary nodules with early obstructive pneumonitis in the left lung. He elected surgery, and no lesser procedure than a pneumonectomy could be performed; he was free of pulmonary symptoms until his death seven months later from cerebral metastases.

A fourth patient had Hodgkin's granuloma proved by biopsy of cervical lymph nodes. Eleven years after that diagnosis, she was examined because of a cough that had become progressively more severe and a right-sided wheeze of three years' duration. Roentgenograms showed atelectasis of the right upper lobe. Bronchoscopy then demonstrated a stenosis of the intermediate bronchus on the right side. A totally consolidated right upper lobe was resected, which contained parenchymal Hodgkin's granuloma. Subsequently, the stenosis of the intermediate bronchus was treated with repeated dilatations. However, she continued to have symptoms; six months following the upper lobectomy, she underwent resection of the remainder of the right lung. When last seen, 19 years after the original diagnosis of Hodgkin's granuloma, she was well.

DISCUSSION

One of our prime missions as physicians is to alleviate suffering and this mission is obviously not furthered by operating on disseminated malignancy. Metastatic neoplasm in the lung usually reflects a widely disseminated and hopelessly incurable malignancy. Therefore, in selecting patients for surgery, there must be good cause to anticipate that it will result in worthwhile palliation or cure or resolution of a strong question as to the proper diagnosis. Thoracotomy per se today is associated with low mortality and morbidity; in this series of 38 patients there was only 1 operative mortality. However, the results certainly must be carefully evaluated before this type of procedure can be justified.

As previously mentioned, biopsy as a planned minimal procedure seems worthwhile as a diagnostic measure. It has proved safe and definitive without undue discomfort or inconvenience to the patient. Palliative resections for bronchial obstruction should be undertaken only when the patient is fully cognizant of the limited goal in view. In this series of patients there were nine diagnostic biopsies, four palliative resections, and 25 operations for cure. More than 50 per cent, 14 procedures, of the latter 25 were some type of resection. This is a satisfactory resectability rate for pulmonary malignancy and would

seem to justify such an aggressive approach if there are many long-time survivors.

Of 18 resections performed in the entire group of 38 patients, 4 were palliative, as has been mentioned. Another one of the resections was performed on a patient who was found to have an uncontrollable renal primary neoplasm early in the postoperative period. Thus, 13 of the 18 resections potentially were curative (Table 2). Four of these 13 resections were pneumonectomies, and the remaining nine were lobectomies or lesser procedures. In the pneumonectomy group, there was one operative death; this patient, as has been mentioned, on postmortem examination was found to have had residual disease. Two additional patients died of their disease, 9 and 10 months respectively, following pneumonectomy, and the remaining patient was lost to follow-up two years following surgery. Thus, in this very small group of cases it is hard to justify the use of pneumonectomy in treating metastatic disease.

Table 2.—*Data in 13 potentially curable cases of neoplastic metastasis in the lung, treated by resection*

Type of resection	No. of cases	Operative death	Postoperative deaths	Living
Pneumonectomy	4*	1 (residual disease)	2 (9 and 10 mo. postop.)	—
Lobectomy or lesser resection	9	—	1 (1 yr. postop.)	8 (1—5½ yr. postop.)

*One patient lost to follow-up two years postoperatively.

On the other hand, among the nine patients who underwent lobectomies or lesser resections and were considered potentially curable, one died within a year after operation and the other eight still are living from one to five and one-half years postoperatively. Among the eight living patients, two have had second thoracotomies for subsequently appearing contralateral metastases.

It is impossible from a series of this size to judge whether a particular type of carcinoma is more suitable for pulmonary resection than any other. Our living patients include: two with hemangiopericytoma, two with carcinoma of the breast, and single patients with renal, ovarian, salivary and colon primaries.

A distinct impression is gained, however, that the duration of time from treatment of the primary neoplasm to treatment of the metastasis is of some

prognostic significance. Almost all of the late metastases occurred in patients who still are living (Table 3).

Table 3.—*Time lapse between treatment of primary tumor and resection of neoplastic metastasis in 13 potentially curable cases*

Time lapse (years)	No. of patients	
	Living	Dead
0	—	1
2	3	1
3	—	1
4	—	1*
5½	—	1
6	1	—
7	2	—
10	1	—
13	1	—
Range 0-13	Total 8	5

*Lost to follow-up after two years.

As mentioned previously, an assumed pulmonary metastasis may prove to be a primary bronchogenic neoplasm. This situation was exemplified by a patient who had a right radical mastectomy for carcinoma. Four years later, in 1950, she developed a peripheral lesion in the left upper lobe of the lung that continued to enlarge for a number of months despite hormonal therapy. A left upper lobectomy was performed and the lesion was found to be a primary squamous bronchogenic carcinoma. Five years after lobectomy, the patient still is well.

Another facet of the problem of surgical treatment of metastatic disease is that bronchogenic carcinoma frequently metastasizes to the central nervous system. In our experience a surgical approach under these circumstances is very rarely indicated. In fact, aggressive surgery is strongly contraindicated in a patient having proved bronchogenic carcinoma and signs of an expanding intracranial lesion. However, we have operated on two such patients, although in neither of them was more than palliation achieved. One patient had a small superficial nodule of the scalp that on biopsy proved to be metastatic carcinoma. The only other positive findings were minimal prominence of the hilum of the left lung, and on bronchoscopy several atypical cells. Left pneumonectomy was performed, and a month later radical excision of the scalp and skull. The patient died two years after pneumonectomy, of disseminated neoplasm. The second patient had signs of an expanding intracranial lesion; roentgenograms showed a small peripheral lesion in the right upper lobe. He underwent craniotomy with enucleation of a nodule of metastatic adenocarcinoma. Two weeks

later a right upper lobectomy was performed. The patient died of further intracranial metastases 23 months after lobectomy, but for 20 months of that palliative period he had been able to continue working.

Summary

The indications for surgery in patients having metastatic neoplastic disease in the lung are broadly defined on the basis of findings in 38 cases. Surgery is of value as a diagnostic and a definitive therapeutic procedure in carefully selected cases. In 13 of the 38 patients, resection was performed for possible cure of the condition. Eight of those 13 patients still are living, all eight having undergone lobectomies or lesser resections. In our series the late appearance of pulmonary metastases seemed to indicate a more favorable prognosis.

References

1. Christopherson, W. M., Foote, F. W., Jr., and Stewart, F. W.: Alveolar soft-part sarcomas; structurally characteristic tumors of uncertain histogenesis. *Cancer* 5: 100-111 (Jan.) 1952.
2. Hood, R. T., Jr., Good, A. C., Clagett, O. H., and McDonald, J. R.: Solitary circumscribed lesions of the lung: study of 156 cases in which resection was performed. *J.A.M.A.* 152: 1185-1191 (July 25) 1953.