

# MALIGNANT SYNOVIOMA

## *Report of Two Unusual Cases*

LAWRENCE J. MCCORMACK, M.D.,

Department of Pathology

and

WILLARD PARKER, M.D.

Department of Otolaryngology

**M**ALIGNANT SYNOVIOMA is a well-recognized clinical entity as evidenced by the review of 222 cases by Tillotson, McDonald, and Janes<sup>1</sup> in 1951, and by other series subsequently reported. We are presenting two noteworthy cases: one in which the biologic behavior of the tumor was remarkable and the patient survived an exceptionally long time; the other in which the tumor arose in the anterior portion of the neck, a region not previously reported as a site of malignant synovioma.

### Case Reports

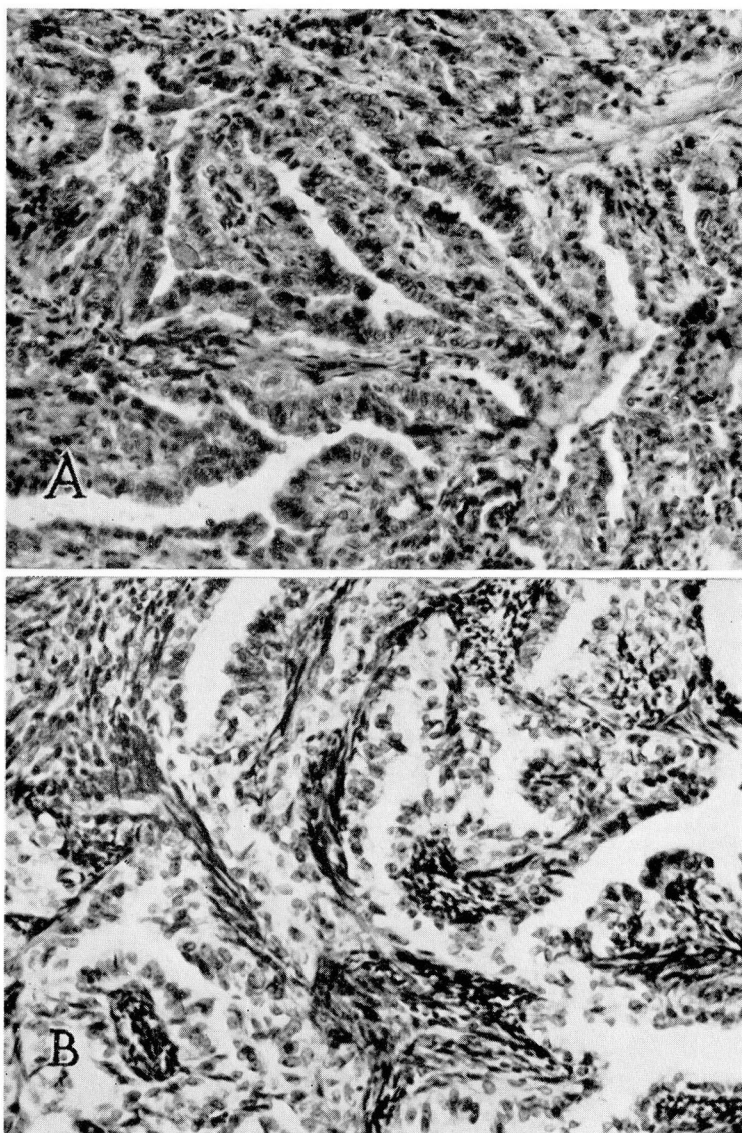
**Case 1.** A 32-year-old white woman was admitted to the Cleveland Clinic Hospital on March 23, 1925, because of pain, swelling, and local discoloration behind the left knee. The symptoms had been present for 15 years, but during the few months before admission had gradually increased in severity.

Physical examination revealed a firm ovoid tumor mass in the popliteal space, which apparently was attached to underlying tissues but not to skin. The overlying skin showed slight bluish discoloration. There was no roentgen evidence of bony change or soft-tissue calcification. The tumor was removed on April 20, 1925, 28 days after admission.

The surgical specimen was a lobulated, soft, pale-gray, poorly encapsulated mass, 12 by 7 by 6 cm.; on bisection the cut surface was grayish white, homogeneous, friable, and moderately vascular. A review of the sections revealed the cell architecture to be typically that of malignant synovioma but with a pronounced epithelial appearance of the cells forming lumina (Fig. 1A). The irregularly shaped spaces were numerous and lined by prominent, cuboidal-to-columnar, pale-staining epithelial cells with uniformly small nuclei. Between these spaces were numerous small dark-staining spindle cells with occasional mitotic figures. No calcification was noted.

Irradiation was administered to the patient postoperatively.

The patient subsequently was seen three times at the tumor clinic of St. Vincent's Charity Hospital in Cleveland, Ohio, in 1938 (13 years postoperatively), 1947, and 1951. Each time there was removed from the popliteal space a small recurrent mass with the same histopathologic characteristics as those of the original tumor (Fig. 1B). In 1953, 28 years after excision of the original neoplasm, the patient still was living without evidence of distant metastasis.



**Fig. 1.** Case 1. (A) Celloidin section of original tumor removed in 1925. The epithelial component is prominent. Hematoxylin and eosin; X270. (B) Recurrence removed in 1951. Hematoxylin and eosin; X270.

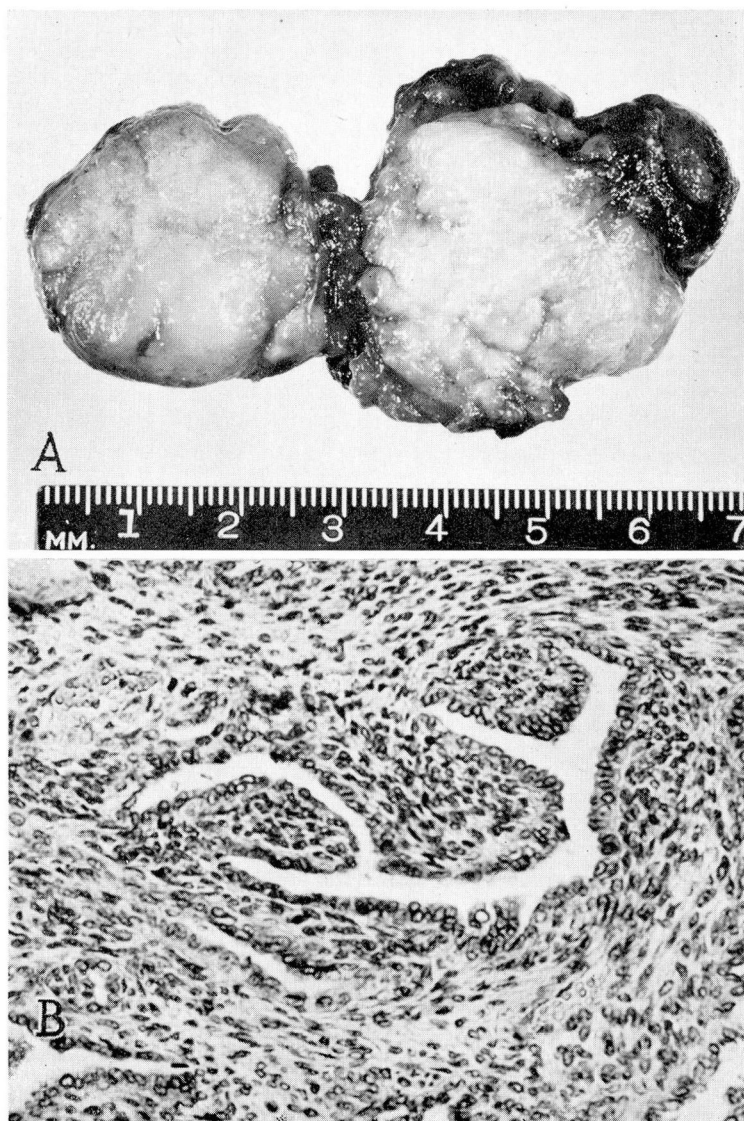

Fig. 2. Case 2. (A) Cut surface of bilobate gross specimen surgically removed. (B) Histology of neoplasm. The spindle-celled component is more loosely arranged in this area. Hematoxylin-eosin—methylene blue; X270.



**Case 2.** A 36-year-old white man was admitted to Cleveland Clinic Hospital on April 6, 1953, because of a mass in the left side of the neck. He stated that two years previously, after a severe upper respiratory infection, he had first noted a swelling in the left side of the neck under the jaw, which had reached its present size in a few weeks and then had remained stationary. Two months before admission he noted a persistent second swelling under the chin near the first mass. It seemed to him that the masses had fluctuated in consistence from soft to "stony hard."

Physical examination revealed the presence of two soft masses in the neck. The posterior tumor was located in the region of the left submaxillary gland; the anterior tumor extended under the tongue on the left side. On frozen-section examination the diagnosis was papillary carcinoma or malignant synovioma. Both masses were immediately excised in continuity.

The tissue that was removed was a bilobate mass, weighing 30.0 gm. (Fig. 2A). Each of the two lobes was firmly attached to a segment of the hyoid bone, 1.0 cm. in length. Both were covered by a thin capsule. The larger lobe measured 3.5 cm. in diameter, the smaller, 3.0 cm. On section, they were generally similar, being composed of soft, finely granular, gray-white tissue, and joined by a narrow isthmus of similar tumor. In addition, the larger lobe had a peripheral margin, 1 cm. in thickness, formed of dark-purple soft tissue.

The tissue was of the same histologic structure throughout the lobes and the isthmus. There were large, irregularly shaped spaces lined by cuboidal cells that occasionally formed papillary projections into the lumina (Fig. 2B). The intervening tissue was formed by dark-staining, small, spindle cells. In some areas these spindle cells were closely packed, and in others they were more loosely arranged. Occasional mitotic figures were present, and psammous calcification was noted in one area. The masses were covered by condensations of fibrous tissue, adjoined by skeletal muscle.

The patient has survived three years, and at the present time there is no evidence of local recurrence or metastasis.

### Comment

Five-year survival rates in patients having malignant synovioma usually are less than 10 per cent; however, Pack and Ariel<sup>2</sup> reported a five-year survival rate of 19.1 per cent in their series. Stout<sup>3</sup> believes that malignant synovioma should be considered cured only when a patient remains well for at least ten years after treatment. No patient in his series survived for ten years, although one remained well for nine years after amputation and then died of pulmonary metastases before the ten-year period ended.

In our first patient the lesion manifested itself only by three local recurrences during a 28-year period, although histopathologically it was indistinguishable from the usual highly malignant form. One of Tillotson, McDonald, and Jones's<sup>1</sup> patients (case 23) who received contact irradiation in addition to surgery had a somewhat similar history—he had a local recurrence 13 years after therapy and was surviving 21 years after the original treatment.

Only five cases heretofore have been reported as occurring in locations other than the extremities. One malignant synovioma was described by Stout<sup>3</sup> as arising from the back of the neck, one by Eisenberg and Horn<sup>4</sup> from the anterior

chest wall, one by Wright<sup>5</sup> from the lumbosacral area, and two by Pack and Ariel<sup>2</sup> from the anterior abdominal wall. In our second patient the neoplasm arose retromandibularly in the upper cervical area.

### Summary

Two unusual cases of malignant synovioma are reported. In one, the patient's survival after initial treatment (28 years) has been exceptionally long, and in the other, the tumor arose in the anterior portion of the neck, a site of origin not previously ascribed to this neoplasm.

### References

1. Tillotson, J. F., McDonald, J. R., and Jancs, J. M.: Synovial sarcomata. *J. Bone & Joint Surg.* **33-A**: 459-473, April 1951.
2. Pack, G. T., and Ariel, I. M.: Synovial sarcoma (malignant synovioma); report of 60 cases. *Surgery* **28**: 1047-1084, Dec. 1950.
3. Stout, A. P.: Seminar on Tumors of Soft Tissues (*Am. Soc. Clin. Path.*), Oct. 19, 1951, Case 18, by American Society of Clinical Pathologists, 1953.
4. Eisenberg, R. B., and Horn, R. C., Jr.: Synovial sarcoma of chest wall, report of case. *Ann. Surg.* **131**: 281-286, Feb. 1950.
5. Wright, C. J. E.: Malignant synovioma. *J. Path. & Bact.* **64**: 585-603, July 1952.