

# ANGIOGRAPHY OF THE CORONARY ARTERIES IN THE LIVE DOG

## *II. Detection of Abnormalities*

EDWARD W. MILLER, M.D.,\*  
Division of Research

C. ROBERT HUGHES, M.D.,  
Department of Radiology

and

WILLEM J. KOLFF, M.D.  
Division of Research

AN earlier article<sup>1</sup> reported our experience with coronary angiography in normal dogs. The present report describes observations on the angiographic diagnosis of experimentally induced abnormalities of the coronary arteries in dogs.

### **Procedure**

The procedure used was described in the previous article<sup>1</sup> and need not be reported in detail. Mongrel dogs were used, weighing approximately 10 kg. each. Angiograms were made under morphine-pentobarbital (Nembutal sodium, Abbott) anesthesia. A 50-cm. cardiac catheter was passed into the root of the aorta through a carotid artery if available, but brachial and femoral arteries were employed with equal success. We depended on our sense of touch and fluoroscopy to place the catheter tip near the coronary ostia.

Injections of radiopaque medium were made either rapidly or slowly. Ninety per cent Hypaque sodium (sodium diacetrizate, Winthrop) was used as the contrast medium in seven, and 70 per cent Diodrast (iodopyracet, Winthrop) in six experiments. The contrast medium usually was injected in 10-cc. amounts at intervals of a few minutes. The average total dose of Hypaque sodium was 43 cc. per dog, or approximately 4 cc. per kilogram of body weight; one dog received 86 cc. within one hour's time. The average total dose of Diodrast was 55 cc. per dog, or about 5.5 cc. per kilogram; one dog received 80 cc. within one hour's time.

---

*This work was supported by a grant from the Cleveland Area Heart Society to Doctor Kolff.*

*The authors wish to acknowledge the technical assistance of Warner S. Williams, Chief X-Ray Technician, Department of Radiology, and of Robert Reinhart, student in the Course in X-Ray Technology, Department of Radiology.*

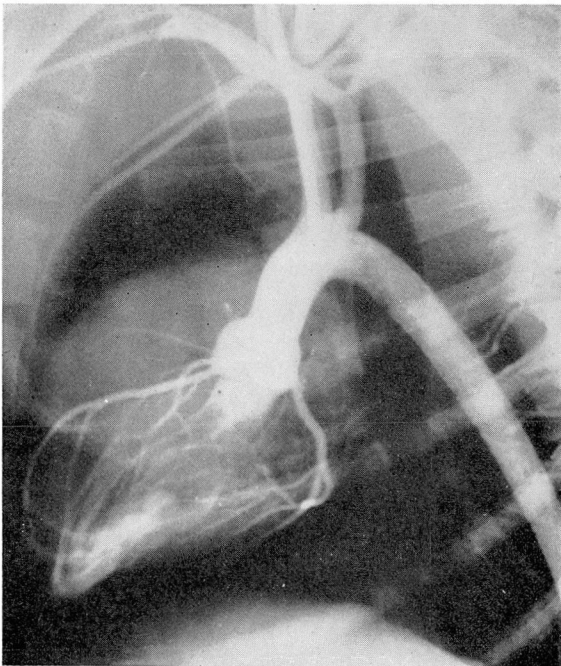
*\*Special Fellow, Division of Research.*

Eleven dogs survived the coronary artery defects that had been produced days or months before in the following ways: (1) ligation of major coronary artery, three dogs; (2) ligation of branches of a major coronary artery, three dogs; (3) narrowing of a major coronary artery at one point by tying a silk ligature over a No. 20F needle and then withdrawing the needle, three dogs; and (4) complete division and reanastomosis of a major coronary artery during induced cardiac arrest while the systemic circulation was maintained by a heart-lung machine, two dogs.

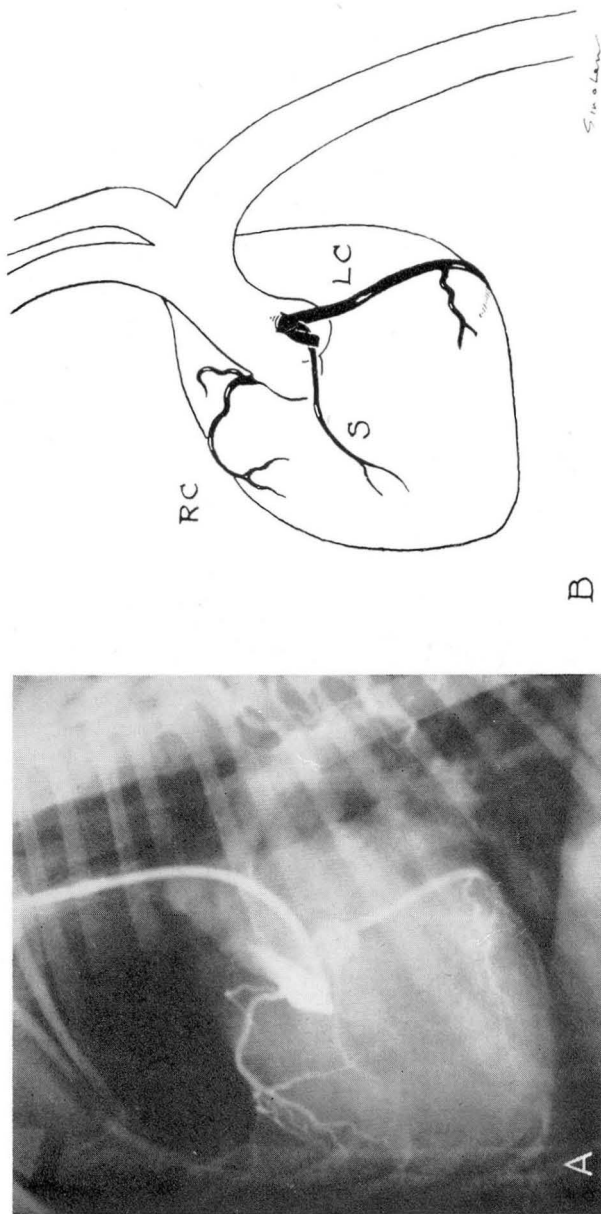
## Results

**Effects of injecting contrast medium.** Immediately after receiving an injection of contrast medium, most dogs exhibited a brief period of apnea followed by hyperpnea and transient tachycardia. There were no other ill effects apparent when 90 per cent Hypaque sodium was used.

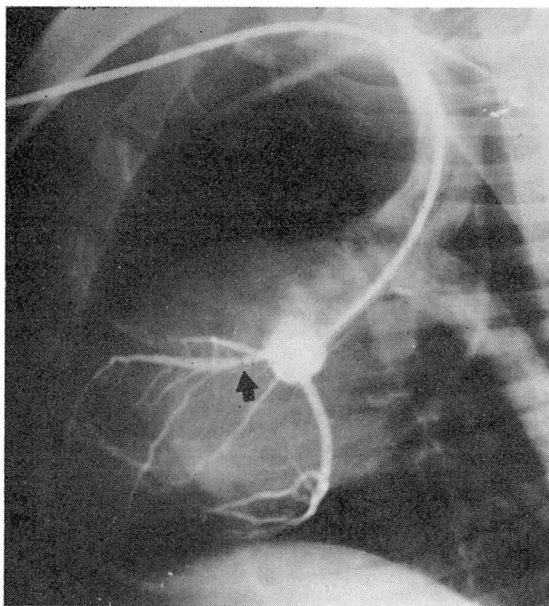
Reactions to Diodrast were more pronounced. This was anticipated, and Diodrast was used only when our supply of Hypaque sodium was exhausted. After Diodrast, occasionally there were signs of central nervous irritation with extensor movements and evacuation of the rectum. Tonic movements of the body could be elicited by sudden noise or by moving the operating table. One dog that



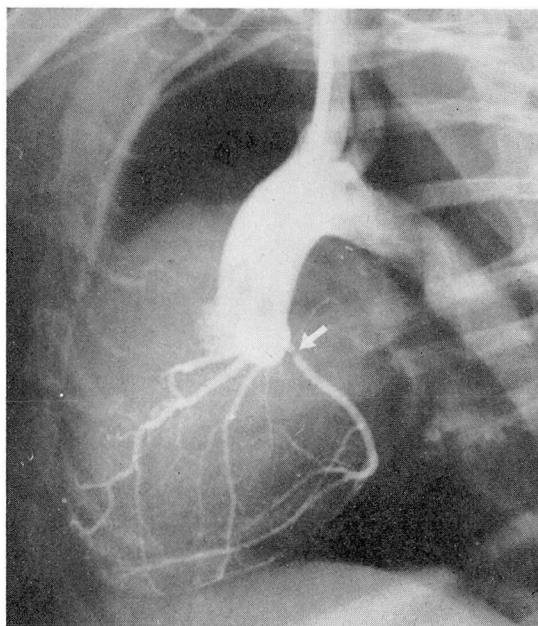
**Fig. 1** (Ligation of right coronary artery). Only the stump of the right coronary artery is filled; the branches of the left coronary artery are clearly visible.



**Fig. 2** (Ligation of anterior descending branch of left coronary artery). **A**, Since the tip of the catheter is in the right sinus, the right coronary artery is filled best, but contrast medium spills over into the left sinus of Valsalva. The anterior descending branch of the left coronary artery is not seen, but the left circumflex and septal branches are well filled. **B**, Diagram to show the anatomic relationship of the vessels seen in **A**. The stump of the anterior descending branch of the left coronary artery cannot be seen in the angiogram and has been sketched in to show its anatomic position. The right coronary artery, RC; the septal branch, S; and the left circumflex branch, LC.

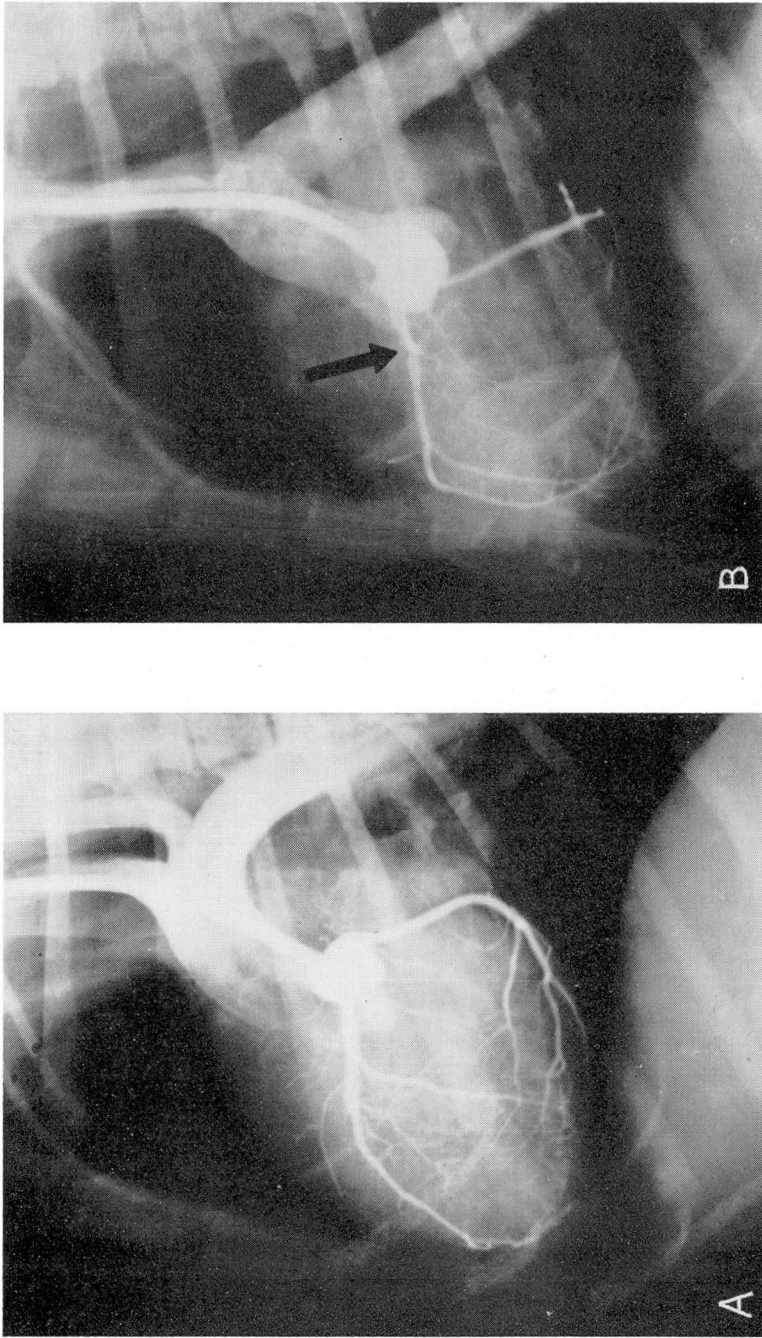


**Fig. 3** (Narrowing of anterior descending branch of left coronary artery). The tip of the catheter is in the left sinus of Valsalva so that the left coronary artery is filled. A narrow area in the anterior descending branch of the left coronary artery is indicated by the arrow. Above the narrowing, the septal artery is filled. The right coronary artery is not seen in this roentgenogram but was visualized on others.

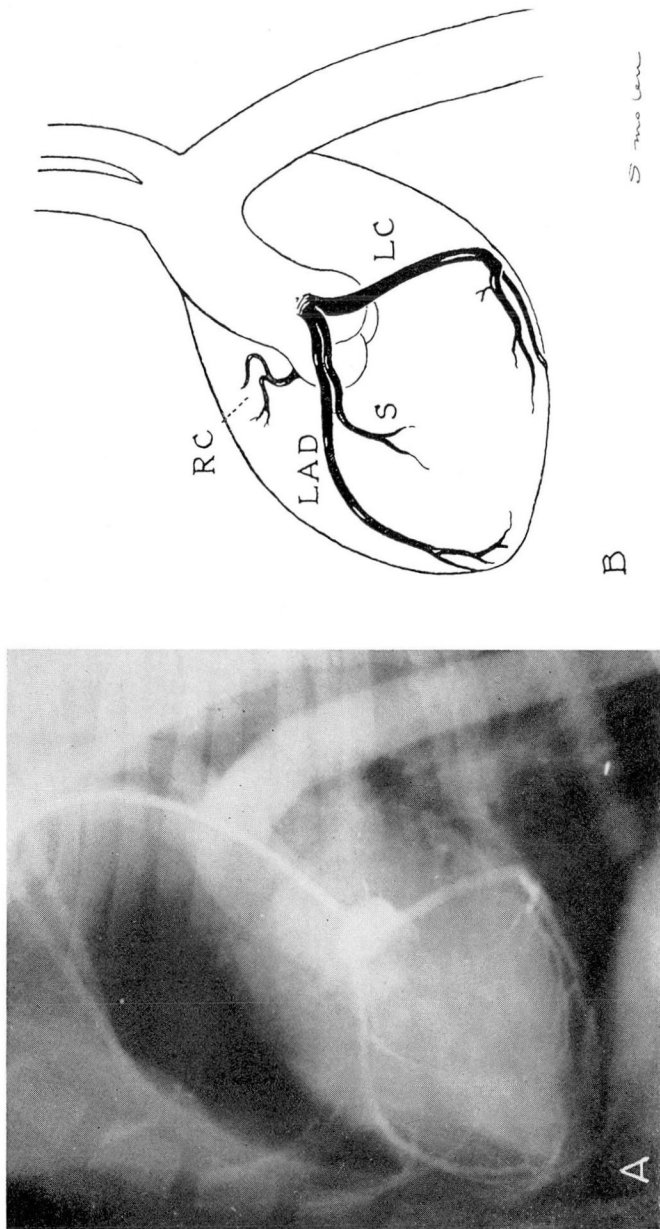


**Fig. 4** (Narrowing of circumflex branch of left coronary artery). The defect is indicated by the arrow. All three coronary arteries are filled.





**Fig. 5** (Narrowing of anterior descending branch of left coronary artery). In these two roentgenograms the effects of a slight rotation in the position of the dog are noted. **A**, The narrow area in the anterior descending branch of the left coronary artery is hidden by the septal branch in the oblique view, but it is brought into relief, **B**, when the dog's position was rotated laterally.



**Fig. 6** (Division and reanastomosis of anterior descending branch of left coronary artery). **A**, The tip of the catheter is in the left sinus of Valsalva. The left coronary artery is filled. The left anterior descending branch is well filled and without evidence of defect. The point of anastomosis cannot be seen. **B**, Diagram of **A** to show anatomic relationship of the vessels.





received 80 cc. of Diodrast within one hour's time, died the night after angiography. This animal had had ligation of the right coronary artery two months prior to the studies. The cause of death could not be determined at autopsy.

In another dog that had had division and reanastomosis of a major coronary artery and that was studied twice, a total of 20 cc. of Hypaque sodium was well tolerated; but one month later, 40 cc. of Diodrast produced a generalized convulsion.

**Quality of angiogram.** In each animal all three coronary arteries, when patent, filled satisfactorily with contrast medium. The three coronary arteries were best outlined when the animal was in the lateral or in the left posterior oblique position. The position of the catheter was of importance in obtaining satisfactory visualization. Since there are three sinuses of Valsalva, right, left, and posterior, and coronary arteries arise only from the right and the left, it is best to place the catheter tip near the ostium of the artery that one wishes to fill. With rapid injection there is overflow of the contrast medium into adjacent sinuses; with slow injection this overflow is less likely to occur.

**Accuracy of angiographic interpretation.** In the three dogs that had ligation of one of the main coronary arteries, the involved vessels were easily recognized by their failure to fill (Figs. 1 and 2).

In the three dogs that had ligation of one or more branches of the left coronary artery, it was not possible to determine roentgenographically which branches were tied off. The wide range of normal variation in the structure of the coronary arterial tree made it impossible to identify a vessel as missing.

In the three dogs with narrowing of a major artery, the roentgenograms clearly demonstrated the areas so treated (Figs. 3 and 4). Rotation of the dog's position in either direction from the lateral brought into relief the origin of the artery from the sinus of Valsalva as well as the first centimeter of the artery. In the oblique view the septal artery might override the anterior descending artery, obscuring the first third of the latter vessel (Fig. 5A). Rotation to the lateral obviated this source of error (Fig. 5B).

In the two dogs in which coronary arteries had been divided and reanastomosed (Figs. 6 and 7), the vessels were filled with contrast medium, showing their patency. The area of suture could not be identified, probably because of the absence of narrowing at the suture line.

## Summary

Angiography was found to be a dependable procedure in localizing sites of partial or complete occlusion of any of the main coronary arteries in 10 experiments in living dogs. Occlusion of side branches of the main arteries could not be detected by this means. Ninety per cent Hypaque sodium proved to be a safe contrast medium for this purpose.

## Reference

1. Hughes, C. R.; Sartorius, H., and Kolff, W. J.: Angiography of coronary arteries in live dog. *Cleveland Clin. Quart.* 23: 251-255, Oct. 1956.