

II. INTRAARTICULAR ADMINISTRATION OF NITROGEN MUSTARD ALONE AND COMBINED WITH A CORTICOSTEROID FOR RHEUMATOID ARTHRITIS

Experimental and Clinical Studies

ARTHUR L. SCHERBEL, M.D., SIDNEY L. SCHUCHTER, M.D.,

Department of Rheumatic Disease

and

S. JOHN WEYMAN, M.D.*

Department of Pathology

DURING and after World War II extensive studies were made of the effects of HN_2 (nitrogen mustard) on various body tissues,²⁶ however no reports of its effects on synovial tissue have been encountered. Because of the observed suppressive action of intravenously administered HN_2 on acute joint inflammation of patients with rheumatoid arthritis (part I), it seemed worthwhile to study the effect of intraarticularly administered HN_2 on synovial tissue, both experimentally and clinically.

Experimental Study

Material and methods. Fifteen joints of seven healthy normal dogs were used in the study. Ten were injected with HN_2 ** alone, three with a combination of HN_2 and hydrocortisone tertiary-butylacetate (hereinafter termed *H.T.B.A.*), one with *H.T.B.A.* alone, and one was used as a control. Histologic examination was made of specimens of synovium obtained by open joint exploration, the dogs being sacrificed from 2 to 30 days after injection. Histologic specimens were fixed in Zenker's acetic acid fixing fluid (modified) and were stained with hematoxylin, eosin, and methylene blue. In the 14 experiments, the agent, dose, and time of examination were as follows:

*Fellow in the Department of Pathology.

** HN_2 0.25 to 1.0 mg. dissolved in normal saline solution diluted to 1 mg. per milliliter.

TREATMENT OF RHEUMATOID ARTHRITIS. II

Agent	Dose, mg.	Time of examination, no. of days after injection
HN ₂	0.25	2
HN ₂	0.25	4
HN ₂	0.25	7
HN ₂	0.50	2
HN ₂	0.50	4
HN ₂	0.50	7
HN ₂	1.0	2
HN ₂	1.0	4
HN ₂	1.0	7
HN ₂	1.0	30
{ HN ₂	0.25	
{ H.T.B.A.	25.0	4
{ HN ₂	0.5	
{ H.T.B.A.	25.0	4
{ HN ₂	1.0	
{ H.T.B.A.	25.0	4
H.T.B.A.	50.0	7

Results. During the period of observation before sacrifice, there was no evidence of pain on motion of any of the joints. All joints into which more than 0.25 mg. of HN₂ had been injected swelled slightly to moderately for from two to five days, after which time the swelling quickly subsided. Grossly the joints injected with HN₂ showed mild diffuse erythema of the synovium which was slightly greater in those areas having the heaviest concentration of HN₂. However, the synovial membrane examined 30 days after injection of HN₂ was normal in color, slightly irregular, and glistening.

The injection of HN₂ alone, produced changes in the synovialis that in general were histologically similar in all the joints; minor differences were interpreted as being the result of the differences in doses and in time intervals between the injections and the sacrifice of the animals. When a combination of HN₂ and H.T.B.A. was injected, the histologic changes were not so obvious; and when H.T.B.A. was injected alone, no significant histologic changes were apparent.

In the untreated synovial membrane from a normal dog there was observed a superficial layer of lining cells, with an underlying thin layer of collagen containing capillaries, on a fibroadipose stroma also containing capillaries (Fig. 1). Two days after intraarticular injection of 0.5 mg. of HN₂ there was absence of the superficial layer of lining cells and homogenization of the underlying superficial collagen (Fig. 2). A similar homogenization with endothelial swelling had occurred in the walls of some small blood vessels. Scanty lymphocytic infiltration was present superficially. Seven days after intraarticular injection of 1.0 mg. of HN₂ the changes were generally similar to those described for the two-day specimen with, in addition, a slight infiltration of histiocytes; again there was a slight or no inflammatory reaction. In certain areas there was beginning regeneration of the superficial layer of lining cells, which appeared as a thin, flat layer.

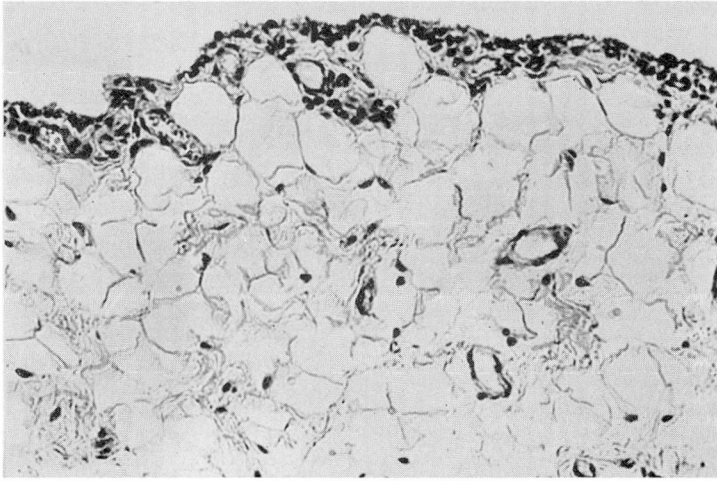


Fig. 1. Normal untreated canine synovial membrane. Hematoxylin-eosin-methylene blue; X225.

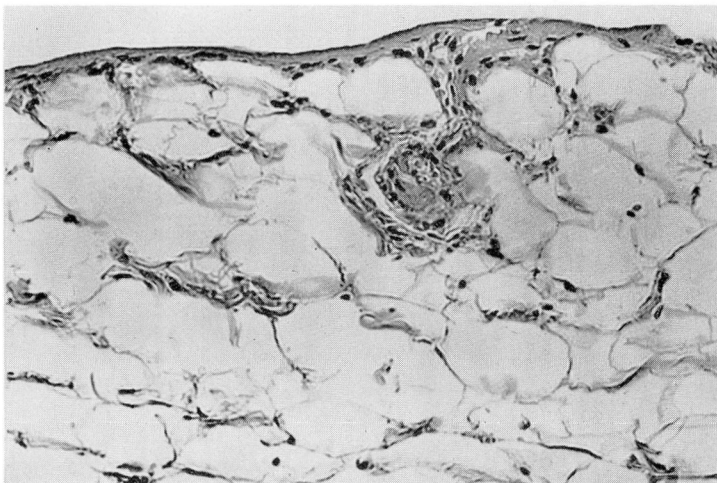


Fig. 2. Canine synovial membrane two days after intraarticular injection of 0.5 mg. of HN₂. Absence of layer of lining cells; homogenization of underlying collagen. Hematoxylin-eosin-methylene blue; X240.

Endothelial swelling in some areas had disappeared, and the walls of the blood vessel appeared to be almost normal. Thirty days after intraarticular injection of 1.0 mg. of HN₂ the synovial membrane appeared almost normal (Fig. 3); the collagen still showed faint alteration in staining character and was slightly homogenized. A mild lymphocytic and plasma-cell infiltration was present with fibroblastic proliferation in some superficial areas. H.T.B.A. administered alone caused no significant histologic changes; cellular infiltration and capillary and

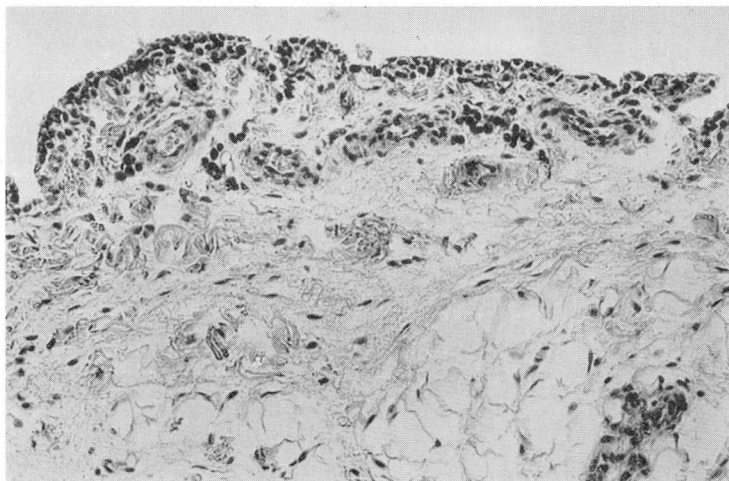


Fig. 3. Canine synovial membrane, almost normal, 30 days after intraarticular injection of 1.0 mg. HN₂. Hematoxylin-eosin-methylene blue; X160.

collagenous changes were absent (Fig. 4). A combination of 1 mg. HN₂ and 25 mg. H.T.B.A. caused only slight infiltration of lymphocytes, plasma cells, and histiocytes, with some capillary congestion and slight endothelial swelling; homogenization of underlying collagen and lysis of synovial membrane lining cells were not apparent (Fig. 5).

Summary. The injection of HN₂ into joints of normal dogs caused the following changes: (1) lysis and disappearance of the synovial membrane lining cells with subsequent regeneration of these cells; (2) transient fibrinoid change in underlying superficial collagen fibers, evidenced by homogenization and deep acidophilia in routinely stained hematoxylin-eosin sections, with greenish-blue streaks and smudges in the sections counterstained with methylene blue; (3) endothelial swelling in adjacent capillaries with congestion of the superficial vessels and focal extravasation of erythrocytes; (4) within 24 hours, scanty, focal, superficial infiltration with lymphocytes and plasma cells and an occasional neutrophil; later, infiltration with histiocytes which disappeared after a few weeks, and fibroblasts which persisted. The intraarticular administration of a combination of HN₂ and H.T.B.A. resulted in fewer histologic changes although slight swelling of synovial cells and endothelial cells was apparent. The fibrinoid change of collagen and lysis of synovial membrane lining cells were not observed in the three joints that were injected with a combination of the agents. H.T.B.A. administered alone caused no significant histologic change.

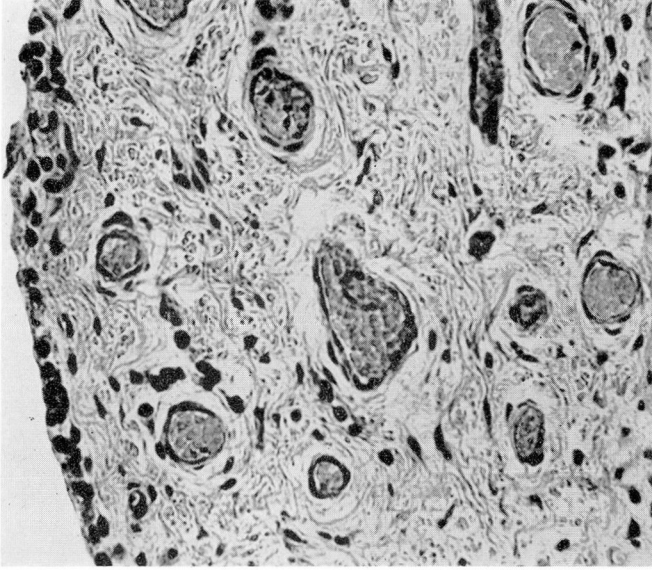


Fig. 5. Canine synovial membrane four days after intra-articular injection of a combination of 1 mg. HN_2 and 0.25 mg. hydrocortisone. There are: slight infiltration by lymphocytes and plasma cells, an occasional histiocyte, congestion of capillaries, and slight endothelial swelling. The cells lining the synovial membrane are swollen but otherwise unaffected. Homogenization of the underlying collagen and lysis of synovial cells are not apparent. Hematoxylin-cosin-methylene blue; X290.

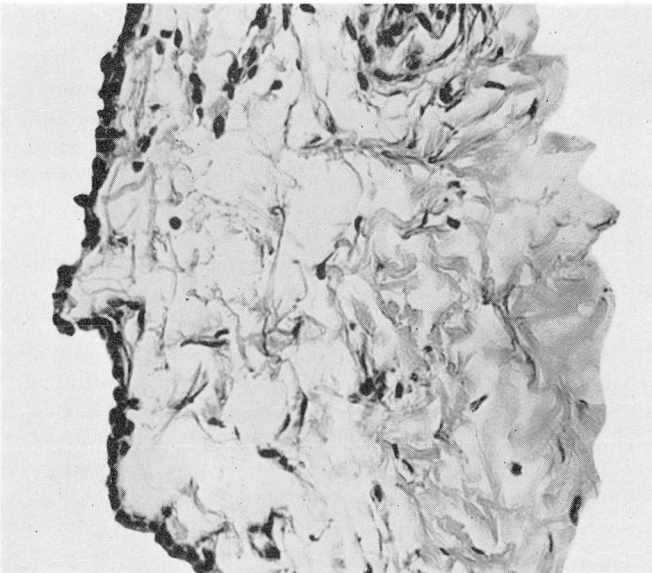


Fig. 4. Canine synovial membrane two days after intra-articular injection of hydrocortisone. There are no significant histologic changes; there is slight edema; cellular infiltration and capillary and collagenous changes are absent. Hematoxylin-cosin-methylene blue; X290.

Clinical Study

Selection of patients and procedure. This study comprises a group of 130 patients with active rheumatoid arthritis who received intraarticular injections of HN_2 alone or in combination with hydrocortisone acetate or H.T.B.A. or prednisolone tertiary-butylacetate (hereinafter termed *P.T.B.A.*) over a period of two years. The duration and severity of the arthritis as well as the functional capacity of the patients varied widely. Thirty-three patients had grade 1, 42 patients had grade 2, 31 patients had grade 3, and 24 patients had grade 4 disease (A.R.A. classification modified¹⁸).

HN_2 alone was administered in 24 patients, 16 of whom had received no other medication for the arthritis and 8 of whom had taken medication orally, prior to the injections of HN_2 , resulting in only partial relief of joint manifestations.

One hundred and six patients received HN_2 in combination with an intraarticular steroid; 28 of these patients had received no other medication for the rheumatoid arthritis and 78 were receiving medication orally which had resulted in only partial decrease in synovitis and swelling. In 28 of the latter 78 patients the medication consisted of iproniazid 12.5 mg. and prednisone 3 to 7.5 mg. daily; in 50 patients it consisted of prednisone 3 to 7.5 mg. daily and chloroquine phosphate 250 mg. daily or hydroxychloroquine sulfate 200 to 800 mg. daily. Forty-three of the 106 patients formerly had received three injections of H.T.B.A. alone, which usually had resulted in only temporary improvement of joint swelling lasting from 3 to 21 days following each injection.

Of the 106 patients, 50 were hospitalized and received three injections at three-day intervals. The 56 patients who were not hospitalized received three injections at 7 to 10 day intervals; and three to nine months later, 20 of these 56 patients received an additional two or three injections at 7 to 10 day intervals.

Drugs, dosages, and technic of intraarticular administration. Doses of HN_2 administered alone ranged from 0.1 to 1.0 mg.; those of 0.25 mg. or less were diluted in 0.5 ml. of saline solution, and those of 0.5 to 1.0 mg. were diluted in 1.0 to 2.0 ml. of saline solution. The combination of HN_2 and an intraarticular steroid was prepared as follows: 1 mg. HN_2 diluted in 1 ml. saline solution was mixed with hydrocortisone acetate, H.T.B.A., or P.T.B.A., 25 mg. per milliliter, in varying ratios for different joints.

Our technic for intraarticular injections, except into the wrist, was similar to that described by Hollander and associates.²⁷ The combination of HN_2 and an intraarticular steroid was used immediately after it was mixed, and promazine hydrochloride, 50 mg., was given orally before the injections inasmuch as nausea and vomiting occasionally occurred after as little as 0.5 mg. of HN_2 , combined with intraarticular steroid, had been injected. The usual mixture for most joints was 0.5 mg. HN_2 in 0.5 ml. saline solution in 1 ml. (25 mg.) hydrocortisone acetate, H.T.B.A., or P.T.B.A. For elbow and ankle joints two injections, each containing 0.25 mg. of HN_2 combined with 0.5 ml. of an intraarticular steroid, was used. The wrist usually was injected in four areas: A, B, C, D (Fig. 6). The carpal tunnel, Area C, was injected routinely whenever there

was thickening or swelling of the transverse carpal ligament or restriction of wrist extension. The carpal tunnel was injected with 0.5 ml. (12.5 mg.) of an *intraarticular steroid alone* inasmuch as the median nerve which lies in the carpal tunnel should not be exposed to HN_2 . The dorsal area of the wrist, Area A, was injected with 0.25 mg. of HN_2 diluted in 0.25 ml. of saline solution combined with 0.5 ml. of intraarticular steroid. One half of this amount in this combination was injected into the radial and ulnar regions, Areas B and D, when there was moderate or marked periarticular swelling. In order to reduce periarticular swelling in the wrist area, the latter injections were made into the deep subcutaneous tissue rather than into the joint space. The interphalangeal, metacarpophalangeal, and metatarsophalangeal joints were injected with doses of the combined drugs equivalent to those that were used in the radial and ulnar areas. The knees usually were injected with 0.5 mg. of HN_2 mixed with 1 ml. of intraarticular steroid, but when thick pannus formation or persistent effusion existed, the mixture was doubled to 1 mg. of HN_2 and 2 ml. of steroid. The hips, shoulders, and temporomandibular joints were injected only with steroid when an intraarticular injection appeared warranted.

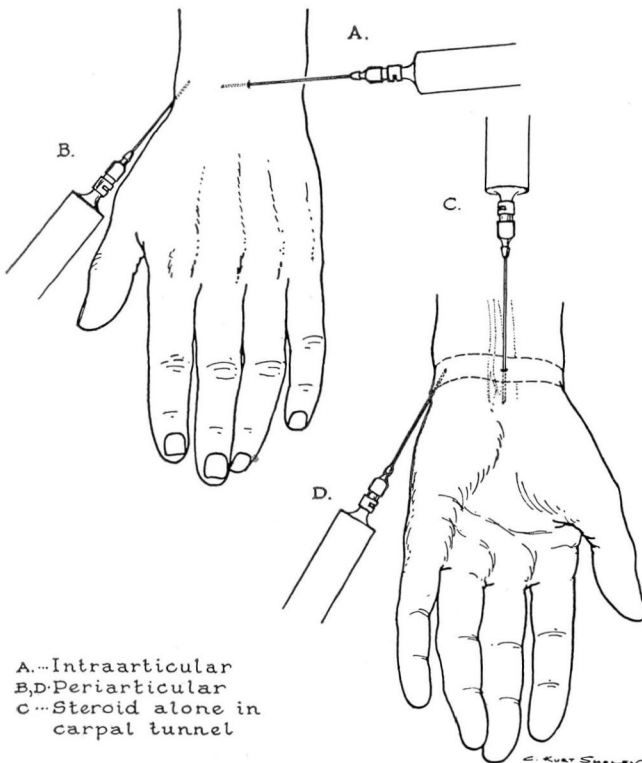


Fig. 6. Technic for injecting the wrist.

Results. Of the 24 patients receiving HN_2 alone, 18 had a marked decrease in synovitis. However, it was observed that while a rapid and prolonged decrease in joint swelling occurred after the injection of HN_2 alone, pain was not relieved so readily or so completely as it was after the injection of intra-articular steroid. Therefore, 106 patients in this study, and all subsequent patients receiving intraarticular injections of HN_2 , also received intraarticular steroid. The rationale of combining the drugs was to prolong the desirable but temporary effect obtained when intraarticular steroid was used alone.

In 37 of the 106 patients with persistent synovial inflammation and thickening present for from one year to eight years, who received combined HN_2 and intraarticular steroid there was complete disappearance of pain and swelling. These 37 patients now have been observed for 18 to 24 months and there has as yet been no recurrence of pain, swelling, or tenderness of the previously involved joints. In 35 of the remaining 69 patients, joint swelling was absent for six to nine months, after which time it recurred but to a lesser degree and was again suppressed by one or two additional injections. Pain subsided completely in 20 and incompletely in 15 of these 35 patients. Of the 34 remaining patients, in 24 there was incomplete disappearance of pain and swelling and in 10 there was no significant response to treatment.

In 28 of the 34 patients who responded poorly to the combined therapy, extensive fibrosis, cartilage destruction, relaxation of ligaments, and painful crepitation were prominent before treatment. Aggravation of joint instability frequently occurred after a joint with relaxed ligaments had decreased in size as a result of treatment.

Twenty-six patients who for more than one year had persistent swelling of one or more large joints, associated with increased erythrocyte sedimentation rates and serum polysaccharide-protein ratios, and who had received oral medication for six months or more without significant relief of joint manifestations, were given as supplemental therapy three intraarticular injections of HN_2 and H.T.B.A. into each of the involved joints. In addition to further clinical improvement manifested by decrease in joint swelling there was return to normal of the erythrocyte sedimentation rates and serum polysaccharide-protein ratios. In each instance it appeared that disease activity had been altered by intraarticular administration of HN_2 .

Toxicity and sensitivity reactions. There was no evidence of hematopoietic depression following the administration of this small amount of HN_2 . In 33 patients serial roentgenograms of joints one year after the initial injections of HN_2 have shown no evidence of injury to cartilage or bone. In one patient the HN_2 was not injected completely into the joint, and a small area of painless induration developed along the site of the needle tract, which became crusted and disappeared spontaneously within three months. Frequently nausea and occasionally vomiting occurred within one to four hours after administration of as little as 0.5 mg. of HN_2 ; these symptoms were satisfactorily controlled when 50 mg. of promazine hydrochloride was given orally before the injection of HN_2 . In 10 patients localized itching associated with a temporary increase

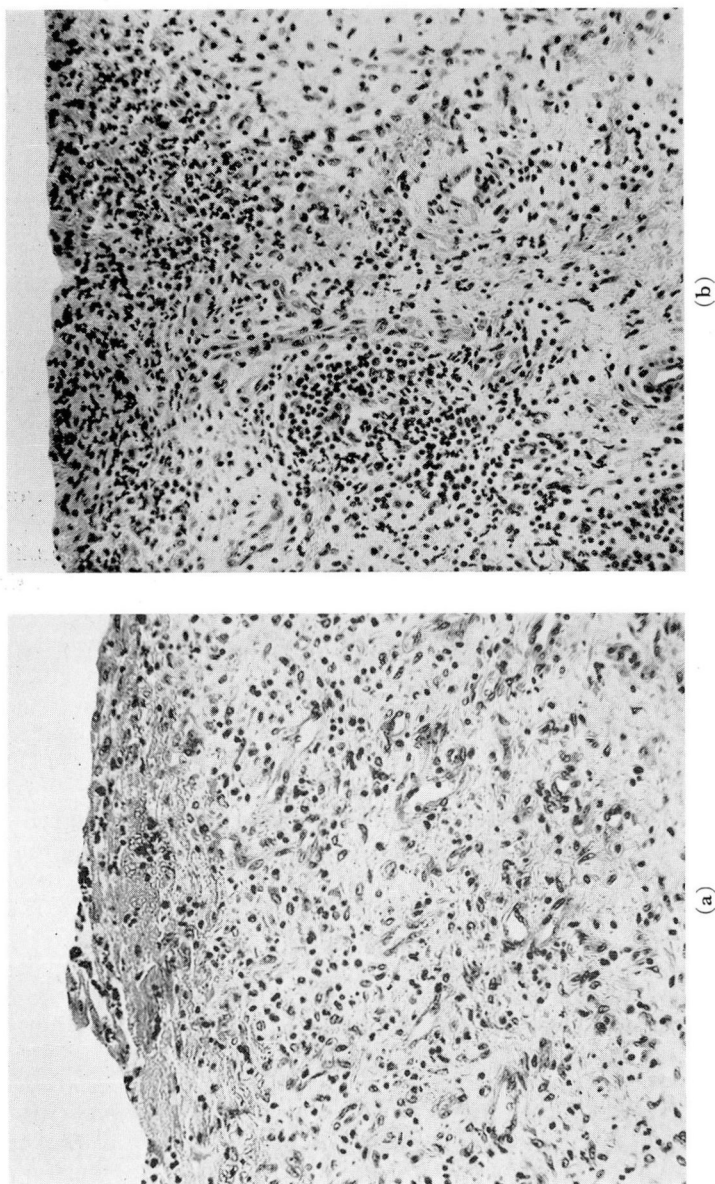


Fig. 7. Human synovial membrane, acute rheumatoid arthritis, before treatment. (a) A few epithelial-like lining cells are present. Fibrin deposition, granulation tissue, slight infiltration by neutrophils and slight superficial edema and congestion are present. Hematoxylin-cosin-methylene blue; X200. (b) Epithelial-like lining cells are absent; marked neutrophil infiltration is present with occasional lymphocytes and plasma cells. A focal collection of lymphocytes and histiocytes is present around a capillary. Hematoxylin-cosin-methylene blue; X200.

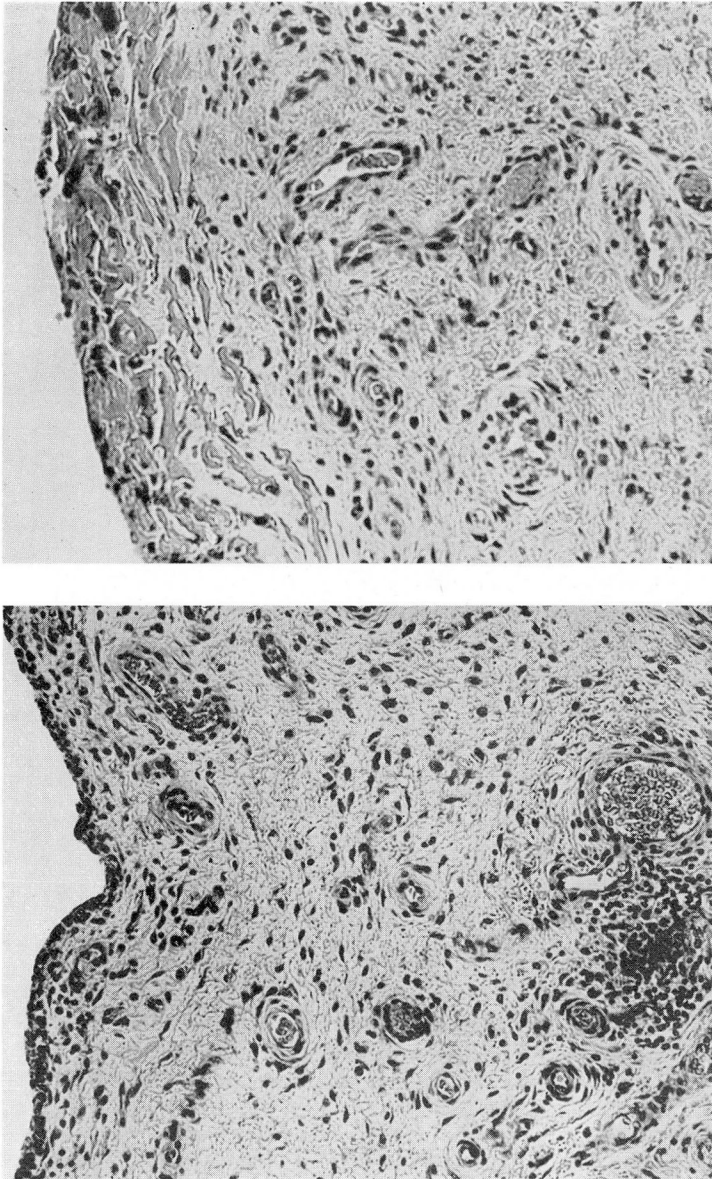


Fig. 8. Human synovial membrane, acute rheumatoid arthritis, one month after intraarticular HN_2 . (a) Synovial lining cells are present. Focal lymphocyte and plasma cell infiltration and congestion of capillaries are evident. Hematoxylin-cosin-methylene blue; X185. (b) Homogenized fibrin superficially, and rare lymphocyte and plasma cell present. Hematoxylin-cosin-methylene blue; X225.

in joint swelling, and a maculopapular erythematous rash developed directly over the injected joint a few hours after the injection and usually lasted for from 24 to 72 hours. In 12 patients who had received a combination of HN₂ and H.T.B.A. or P.T.B.A., an increase in joint swelling persisted for one or two weeks and then suddenly subsided. It is not known whether this swelling resulted from a sensitivity reaction to medication, or from temporary irritation of the synovial membrane.

Histologic features of synovial membrane. The effect of HN₂ in small doses administered intraarticularly is illustrated by the comparison of microscopic sections of synovial membrane before and after treatment (Figs. 7 and 8). A 26-year-old married woman having persistent rheumatoid arthritis of one year's duration developed an acute exacerbation. Both knees were swollen, warm, and painful on motion. Open biopsy was performed to obtain synovial membrane from the left knee. The following day 1 mg. of HN₂ diluted in 1 ml. of normal saline solution was injected intraarticularly, and thereafter every third day for a total of three injections. No other medication was given, and a repeat open biopsy was performed at the same site one month later.

A specimen of synovial membrane obtained before treatment showed microscopically an acute synovitis evidenced by focal absence of the epithelial-like layer of lining cells, superficial fibrin deposition, massive infiltration of neutrophils, a few foci of lymphocytes, a few plasma cells, histiocytes, granulation tissue, slight fibrosis, edema and congestion (Fig. 7).

Synovial membrane obtained from a comparable site from the same patient one month after treatment with HN₂ showed a small amount of fibrin, homogenized in part, the epithelial-like lining cells present except over the fibrinous areas, rare focal collections of lymphocytes and plasma cells, and congestion of capillaries. Neutrophils had almost completely disappeared (Fig. 8).

Discussion

The intraarticular administration of HN₂ has been used primarily as a supplement to the administration of intraarticular steroid in selected cases heretofore resistant to treatment but still potentially reversible. With the technic and dosage described, side effects were insignificant, and continued use of both agents did not appear to be harmful.

The local action of HN₂, as described above, appears to cause marked reduction in the inflammatory reaction as evidenced by a decrease in cellular exudate and edema. In addition there were alterations in the synovial membrane lining cells resulting in eventual regeneration. There was a lack of inflammatory response when HN₂ was injected into the joints of dogs, whereas when an equivalent dose of HN₂ was injected into the muscles of dogs, local inflammatory response occurred, histologically manifested by diffuse infiltration

of neutrophils, principally around blood vessels and degenerated muscle fibers (Fig. 9).

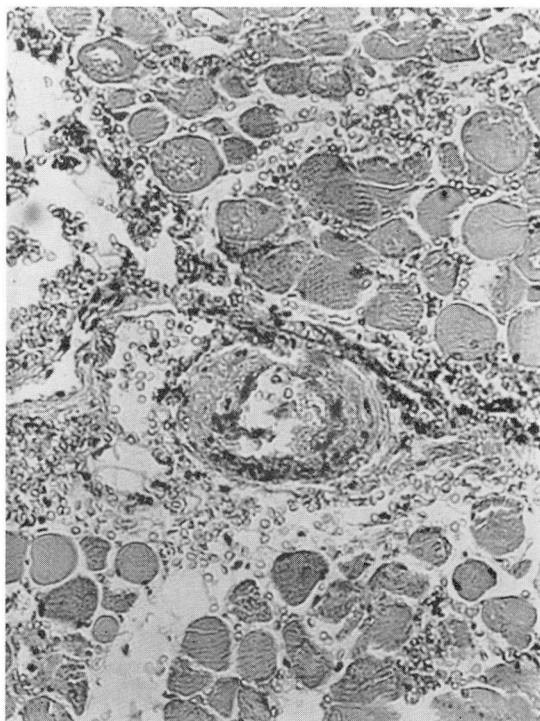


Fig. 9. Canine muscle two days after injection of HN_2 . Cellular infiltration (neutrophils) in area of hemorrhage; homogenization of vessel wall. Some muscle fibers were degenerated. Hematoxylin-eosin-methylene blue; X240.

The intraarticular injection of H.T.B.A. or a related steroid and HN_2 in most patients having advanced joint disease not infrequently resulted in rapid and significant reduction in joint size but also in an unstable joint because of relaxed ligaments, atrophy of adjacent muscle, and destruction of cartilage. In many instances these patients had rather severe anxiety reactions and were fearful of increasing their exercise lest joint swelling recur. It is questionable that they were actually benefited by treatment.

At the present time we believe that HN_2 can be safely and effectively administered intraarticularly alone or in combination with H.T.B.A. or P.T.B.A. for suppression of persistent rheumatoid synovitis with or without effusion of joints. It is used mainly as a supplement to other therapeutic agents that then may be given in smaller doses in an attempt to continue the suppression of disease activity. Temporary side effects, clinically insignificant, may occur, but no serious or harmful effects of HN_2 have been noted during a two-year follow-up. However, there must be long-term observation before this form of therapy can be fully evaluated.