

## PROSTHETIC REPLACEMENT OF THE HEMISECTED MANDIBLE

ROBIN ANDERSON, M.D.

Department of General Surgery

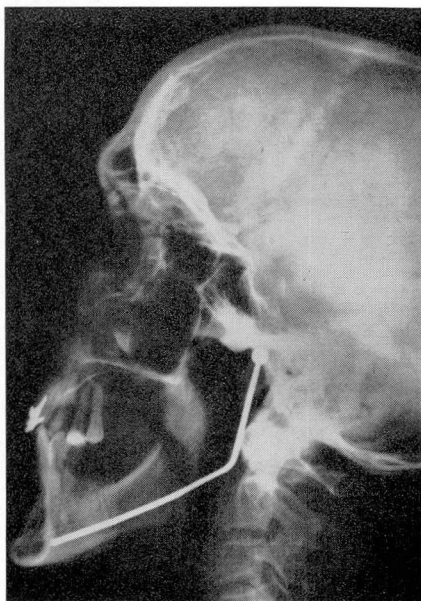
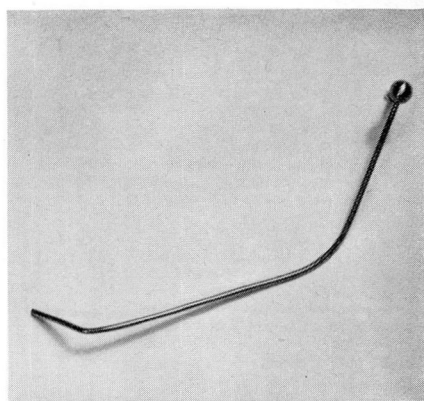
**R**ECONSTRUCTION of one half of the mandible including its condyle is a formidable surgical problem. Ideally it should be possible to graft a piece of bone that will unite with the remaining bone segment at one end, and form an articulating condyle at the other. Unfortunately, the graft does not behave in this ideal fashion, and for practical purposes is unsatisfactory. Because of this difficulty, many surgeons believe that the mandibular fragment is better left unsupported after hemisection. They consider the inevitable collapse of the pharynx neither disabling nor dangerous if a tracheostomy is maintained for a sufficiently long period, and they argue that the secondary deformity associated with abnormal mobility of the jaw fragment is inconsequential.

Despite these arguments, there is no question that pharyngeal collapse, even if it does not increase the chance of mortality, is most unpleasant to the patient, particularly if it is prolonged. Furthermore, while a majority of patients will tolerate a jaw segment that, when chewed with, wanders across much of the lower half of the face, they are most grateful if reasonably normal function can be established. For these reasons, the remaining portion of mandible should be supported in its normal position at the time of resection, if such support is possible.

Probably every surgeon who has removed a number of jaws has attempted such reconstruction. Because of a long history of bone-graft failures, most of these attempts have been carried out with prosthetic devices of inert metal or plastic, shaped to resemble the resected specimen. These efforts generally have met with failure, with ultimate extrusion of the large foreign body. The series of cases reported by Healy and associates<sup>1</sup> using acrylic prostheses is illustrative: of their eight implants, most were extruded, and only one stayed in place for as long as one year. Believing the size of the prosthesis to be the most significant factor in this lack of success, Byars<sup>2</sup> replaced the hemisected jaw with a small Steinman pin, the condylar end of which terminated in an olive-shaped piece of stainless steel drilled through in numerous places to permit its transfixion by granulation and scar tissue. His results have been consistently superior to those previously reported. We agree heartily with Byars' concept, and have employed a similar prosthesis modified to minimize its mass and to simplify its construction.

### Technic

The prosthesis we employ is shown in Figure 1. It consists of a Steinman pin that in cross section measures approximately  $\frac{1}{16}$  inch. Its condylar portion is a  $\frac{9}{32}$  inch stainless-steel ball bearing, drilled and driven into position on the pin. If the joint is tight, soldering or brazing is unnecessary. It has not been found necessary to drill additional holes through this ball for fixation by fibrous tissue. At operation the pin is bent to the desired angle (Fig. 1).

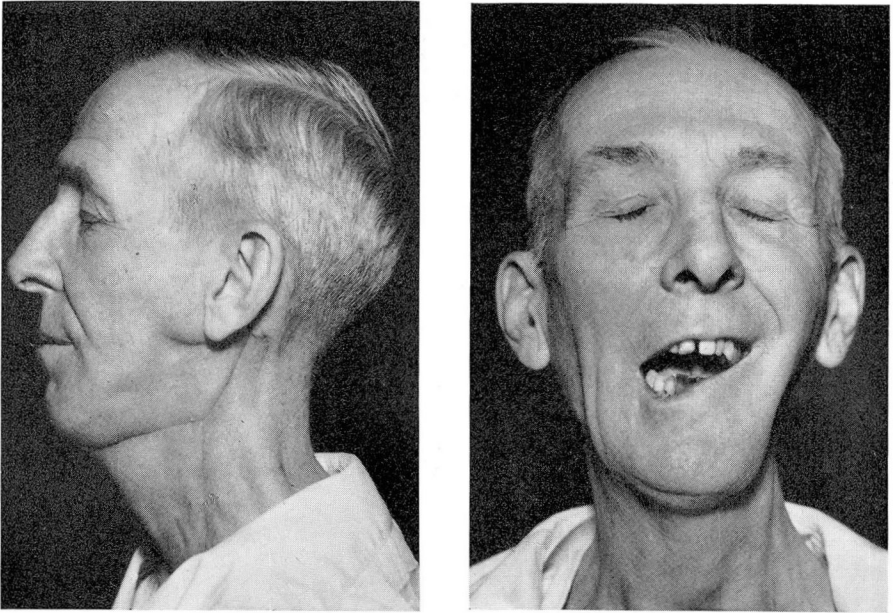


**Fig. 1.** (Left) Photograph of the prosthetic device bent to shape for implantation. (Right) Postoperative roentgenogram showing the prosthesis in place.

After hemisection of the jaw, a pin-sized hole at least  $\frac{3}{4}$  inch long is drilled into the cut end of the remaining jaw fragment. With any available teeth in occlusion, this hole should accept the pin without torsion or displacement of the prosthetic condyle out of the fossa. The pin is angled so that its course from condyle to bone is just in contact with the soft tissue medial to it. This makes it possible to close the soft tissue over the pin without tension. Such closure prevents contact of the pin with the skin flap anywhere along its course, thus minimizing the possibility of subsequent erosion through the skin. Because of its light weight and inconsequential mass the prosthetic condyle remains in the fossa without additional support. Except for the skin approximation, 4-0 chromic catgut sutures are employed throughout. A mild pressure dressing is applied at the close of the procedure. A Levin tube and a prophylactic tracheostomy are essential only during the immediately postoperative period and are discontinued as soon as possible. Minimal interdental wiring with rubber band support is applied at the time of operation if teeth are available.

## Results

During the past four years, we have used this type of prosthesis on five patients. Two of these implants are currently functional after four (Fig. 2) and



**Fig. 2.** (Left) Lateral view of patient with prosthesis in place for four years, showing minimal deformity. (Right) The patient opens his mouth easily, adequately, and in the normal plane of mandibular motion.

two years respectively. A third was tolerated well but was removed at the time of subsequent surgery for a recurrence of tumor approximately one year after insertion. The remaining two were not tolerated because of local infection and had to be removed in the early postoperative period; in neither of these was erosion of skin a factor.

### Summary

When one half of the mandible is resected, the remaining jaw fragment should be supported by means of an articulating prosthesis. A stainless-steel implant of minimal size has been effective for this purpose.

### References

1. Healy, M. J., Jr.; Sudbay, J. L.; Niebel, H. N.; Hoffman, B. M., and Duval, M. K.: Use of acrylic implants in one stage reconstruction of mandible. *Surg., Gynec. & Obst.* **98**: 395-406, April 1954.
2. Byars, L. T.: Surgical management of mandible invaded by oral cancer. *Surg., Gynec. & Obst.* **98**: 564-570, May 1954.