

REPAIR OF INJURY TO THE COMMON BILE DUCT

Results in 69 Cases

GEORGE L. HOFFMANN, M.D.* and GEORGE CRILE, JR., M.D.

Department of General Surgery

THIS report is based on a survey of the results of 69 operations for repair of injuries to the common bile duct. The operations were performed at the Cleveland Clinic Hospital during the 15-year period from 1940 to 1955 and included hepaticoduodenostomy as well as more complicated procedures.

There is little agreement among surgeons as to which technic of reconstruction of the common bile duct provides the best results. Cole and associates^{1,2} advocate the use of Roux-Y procedures, which they expect to produce good results in 90 per cent of the cases if from 2 to 3 cm. of duct is available for anastomosis, and if the surgeon himself is "satisfied" with the operation. However, if the proximal stump of the duct is short, Cole believes that only about 65 per cent of the results will be good. In Cole's cases the over-all results of hepaticojejunostomy, including those operations in which the surgeon himself was "not satisfied" at the end of the procedure, were satisfactory in 79 per cent of the cases. Ravdin³ believes that an end-to-end anastomosis should be made. Aust and Varco,⁴ reported that in their series of 70 adult patients, surgical results were satisfactory in 48 patients. Best results (satisfactory in 9 of 10) were obtained with hepaticojejunostomy.

Walters⁵ states that for repair of injury to the common bile duct, hepaticoduodenostomy has been the most effective procedure at the Mayo Clinic. Boren and Walters⁶ reported that of 147 patients who underwent hepaticoduodenostomies in the last 30 years, 96 (65 per cent) are well. In commenting on their results, Walters⁷ cited the experimental work of Musgrove, Grindlay, and Karlson who reported that in dogs, postoperative cholangitis resulted from stricture rather than from reflux. He⁷ also mentioned that Klement and Lie had better results with hepaticoduodenostomy than with Roux-Y procedures. McGoon and Claggett⁸ report that of 52 patients who received prostheses of Vitallium, 16 patients have satisfactory results. In an additional 13 patients, good results were obtained in each after a second operation was performed to remove the tube. Lahey and Pyrttek,⁹ of the Lahey Clinic, described the technics of splitting the head of the pancreas to locate the lower end of the divided duct so that an end-to-end reconstruction can be carried out. In 19 of 27 patients (73 per cent) operated upon by this technic, results were good or excellent. Fifty-nine (78 per cent) of 78 patients undergoing simple end-to-end repair obtained good results. The authors also reported that a plastic (Heineke-Mikulicz) procedure to open short stenosed segments of the duct gave uniformly successful results in 17 patients, and that duct-to-intestine anastomoses performed in 45 patients gave worthwhile results in 33 patients.

*Formerly Chief Surgical Fellow; present address: Mesa, Arizona.

Aust and Varco⁴ point out the advantages of bringing the long arm of the T tube out through a separate incision in the wall of the duct and allowing a short limb to extend through the intact anastomosis. Of their 11 patients, results were good in eight when the drainage was managed in this fashion, while the results were good in only 40 per cent of these patients when the T tube was brought out through the anastomosis.

Procedures and Results

Between 1940 and 1955, 89 operations* for injured bile ducts were performed at the Cleveland Clinic Hospital, of which 69 (performed on 58 patients) could be classed as *reparative*. These 58 patients also had undergone 108 operations elsewhere, totaling 197, or an average of 3.4 operations per patient. Four (4.5 per cent) patients died in the postoperative period.

Of the 69 reconstructive procedures, 21 were hepaticoduodenostomies; 19 were simple dilatations with insertion of a T tube; 12 were end-to-end anastomoses; seven were hepaticojejunostomies; five were Roux-Y procedures; and five employed either a Vitallium tube prosthesis, skin grafting, or the Grindlay procedure (Table 1). The best results were obtained in the first group,

Table 1.—*Comparison of results of 69 reparative operations on the common bile duct*

Operation	Total number of operations	Good Results**	
		Number of operations	Percentage, %
Hepaticoduodenostomy	21	18	86
Dilatations	19	11	58
End-to-end anastomosis	12	7	58
Hepaticojejunostomy	7	3	43
Roux-Y procedures	5	3	60
Vitallium tube prosthesis	2	0	—
Skin-graft reconstruction	2	0	—
Grindlay procedure	1	0	—
Total	69	42	60

**Patient doing well, having no chills, fever, or jaundice.

where 18 patients are classified as having obtained "good results"—feeling well, with no chills, fever, or jaundice. Two of the three patients in whom operative results were not good had intermittent symptoms of cholangitis without jaun-

*Eighty-seven of these operations were performed by three surgeons: George Crile, Jr., M.D., Stanley O. Hoerr, M.D., and Thomas E. Jones, M.D. (now deceased).

dice, and subsequently underwent gastric resections (Billroth II) to exclude the biliary tract from the direct alimentary flow. The other patient had recurrent jaundice and required reoperation; this result is classed as a failure. The other procedures—dilatation, end-to-end anastomosis of the duct, hepaticojejunostomy, and the use of internal skin grafts (2 cases), Vitallium tubes (2 cases), or the Grindlay procedure (1 case), each produced satisfactory results in less than 60 per cent of the cases.

Technic

Irrespective of the sites of previous incisions, a right subcostal approach gives the most direct access to the common bile duct. If the previous incision was made through the rectus muscle, the subcostal incision lies lateral to the previous one, and the abdomen can be entered almost extraperitoneally without disturbing intraperitoneal adhesions. After the liver is identified, the adherent structures are dissected from its undersurface from right to left (Fig. 1). When carried out

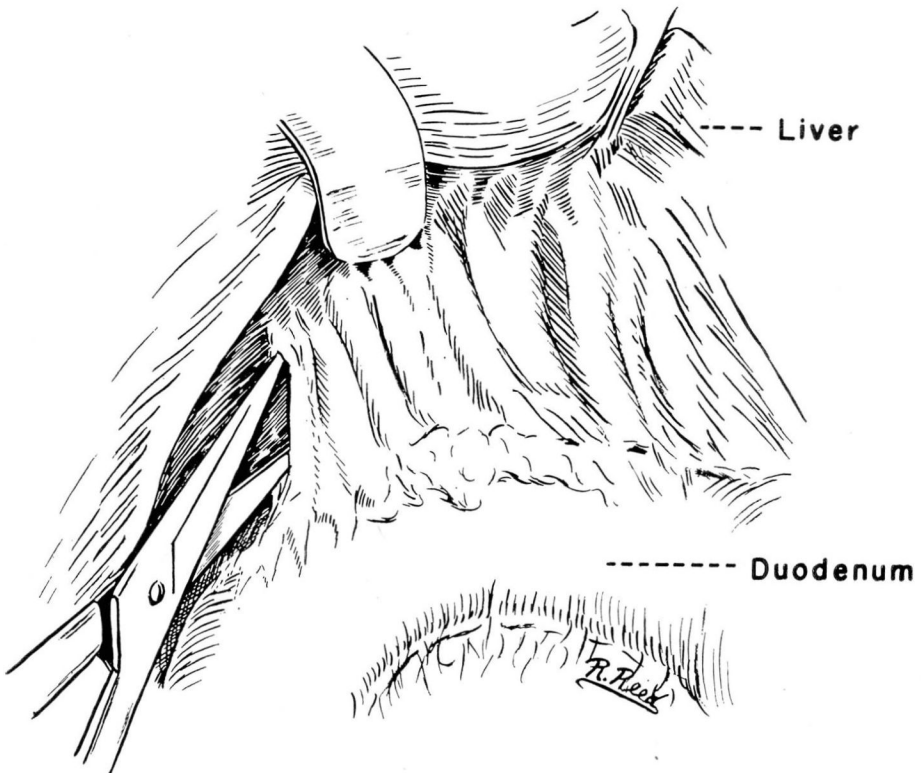


Fig. 1. Sketch showing the beginning of lateral dissection of subhepatic adhesions, for hepatico-duodenostomy.

in this fashion, the dissection proceeds rapidly, and loss of blood is minimal. As the porta hepatis is approached, the hepatic artery can be identified by palpation (Fig. 2). When this vital landmark is identified, aspiration with a needle

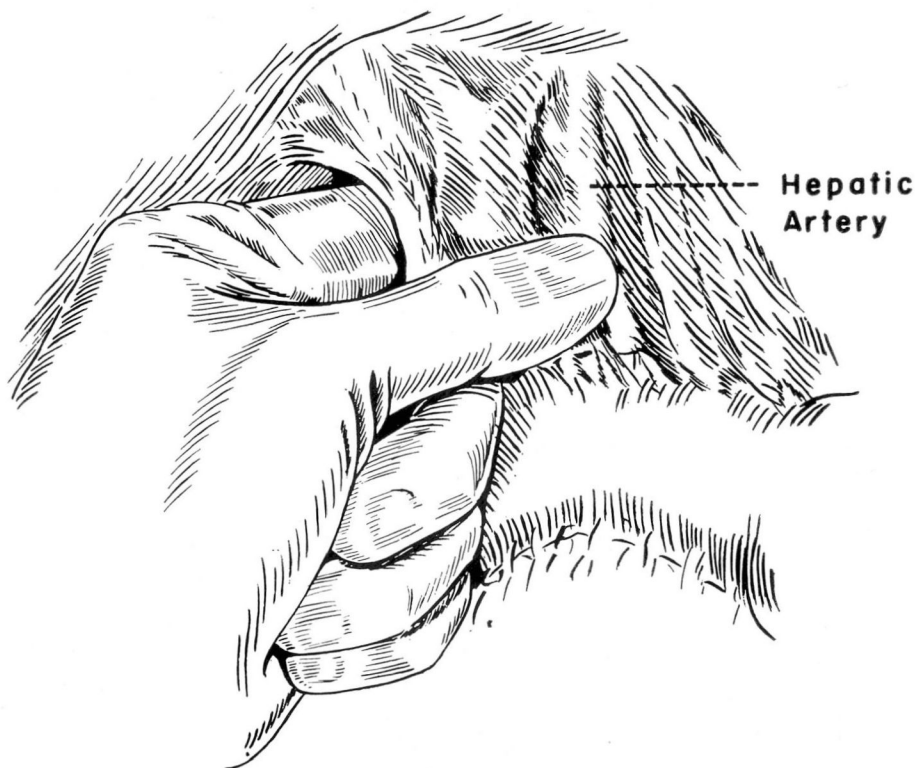

Fig. 2. Sketch showing how the pulsation of the hepatic artery is palpated as dissection progresses during hepaticoduodenostomy.

inserted lateral to it usually demonstrates the bile-containing duct, and an operative cholangiogram can be made (Fig. 3). The information obtained from the cholangiogram may facilitate further dissection of the duct.

Unless the ends of the duct are unusually accessible and of good caliber, hepaticoduodenostomy is carried out using a single layer of interrupted 00 chromic catgut sutures on atraumatic needles to effect an end-duct-to-side duodenal anastomosis (Fig. 4). Silk should not be used in repair of the duct because this material may serve as a nidus for stones that can produce biliary obstruction that requires reoperation (Fig. 5). Although we prefer to insert the T tube through the wall of the duct and place it with a limb extending through the anastomosis, occasionally the stump of the proximal duct is short and it is necessary to bring the tube out through the anastomotic line. Under these circumstances the T tube should not be pulled out, rather, it should be cut off at the level of the skin and should be allowed to pass through the intestinal tract.

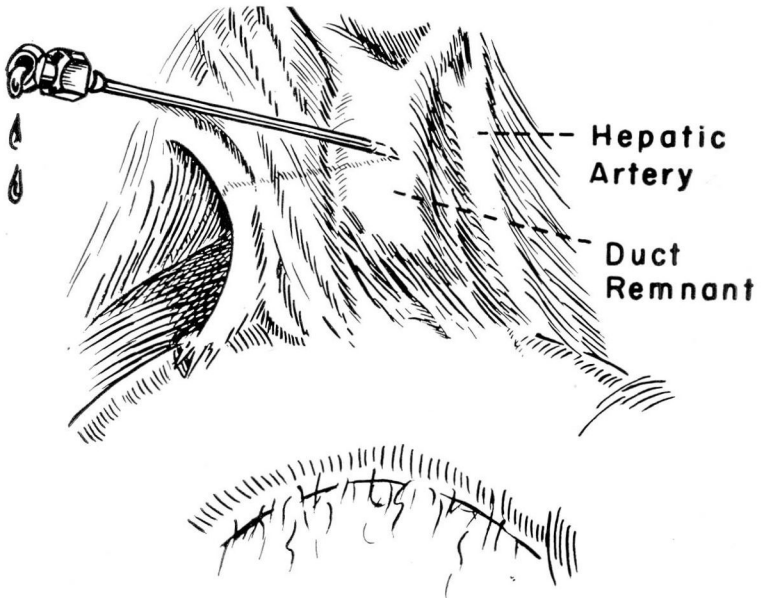


Fig. 3. Sketch showing needle aspiration lateral to the hepatic artery in order to locate the duct containing bile, for hepaticoduodenostomy.

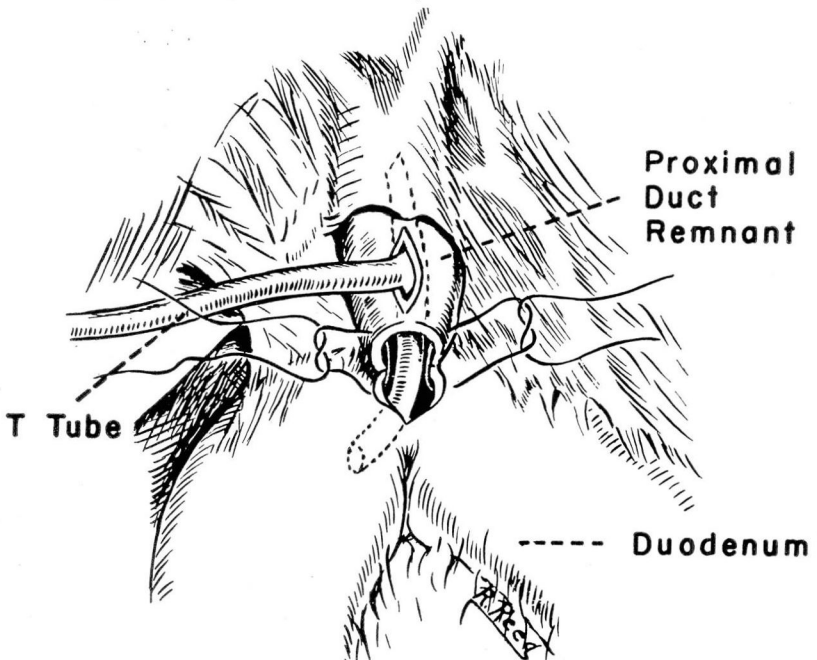


Fig. 4. Sketch showing completion of the hepaticoduodenostomy. The posterior line of interrupted chromic catgut sutures has been placed, and the anterior line has been started.

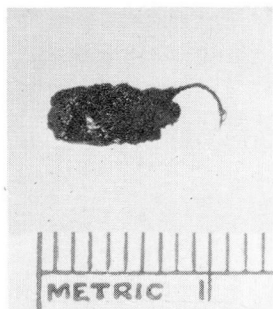


Fig. 5. Gallstones formed around silk suture used in repairing the common bile duct.

This maneuver may result in less disruption and, hence, less stricturing of the anastomosis. We have had no experience with the internal drainage tubes of Allen and McArthur.

If the stump of the proximal duct is fairly large (1.5 cm. or more in diameter), a hepaticoduodenostomy can be done without a T tube, but the area should be drained. Should the injury to the common duct occur at the time of cholecystectomy, when the tissues are soft and pliable, it is best simply to reconstruct the duct over a T tube placed into the duct above or below the line of anastomosis.

Conclusion and Summary

Since selection of cases and use of various special technics for the repair of common bile ducts are apt to influence the end results of operations on the common bile duct, it is impossible to state categorically which is the best method of repair in all cases. In our reported series of 69 operations however, hepaticoduodenostomy was most often feasible and gave results that were better than those of other methods.

The simplest approach to the damaged duct is through a subcostal incision, dissecting the undersurface of the liver from right to left. Fine chromic catgut is the suture material of choice. The most acceptable type of internal splint is the standard T tube which, whenever possible, should be brought out through a separate opening and not through the anastomotic line.

References

1. Cole, W. H.; Ireneus, C., and Reynolds, J. T.: Strictures of common duct. *Ann. Surg.* **133** 684-696, 1951.
2. Cole, W. H.: Strictures of common duct. *Postgrad. Med.* **19**: 464-470, 1956.
3. Ravdin, I. S.: Reconstruction of common bile duct. *Pennsylvania M. J.* **53**: 807-810, 1950.

4. Aust, J. B., and Varco, R. L.: Biliary stricture. *Minnesota Med.* **39**: 189-195; 218, 1956.
5. Walters, W.: Physiologic studies in cases of stricture of common bile duct: 28-year survey with data on 254 patients. *Ann. Surg.* **138**: 609-617, 1953.
6. Boren, J. A., and Walters, W.: Strictures of bile ducts and their treatment. *Proc. Staff Meet., Mayo Clin.* **30**: 245-250; discussion, 250-252, 1955.
7. Walters, W.: *In* Discussion, reference 6.
8. McGoon, D. C., and Clagett, O. T.: Vitallium tube method for repair of strictures of bile ducts. *Surg., Gynec. & Obst.* **106**: 409-412, 1958.
9. Lahey, F. H., and Pyrttek, L. J.: Experience with operative management of 280 strictures of bile ducts, with description of new method and complete follow-up study of end results in 229 of the cases. *Surg., Gynec. & Obst.* **91**: 25-56, 1950.