

HAND-SCHÜLLER-CHRISTIAN DISEASE WITH UNUSUAL ROENTGENOGRAPHIC FINDINGS OCCURRING IN AN ADULT

Report of a Case

THOMAS F. MEANEY, M.D.,*

Department of Radiology

and

LAWRENCE J. McCORMACK, M.D.

Department of Anatomic Pathology

THE usual roentgenographic manifestations of Hand-Schüller-Christian disease consist of a few radiolucent defects of moderate-to-large size in the calvaria and sometimes in the peripheral bones. These lesions most often occur in children, rarely in adults. Our purpose is to report a case of Hand-Schüller-Christian disease in an adult with unusually extensive involvement of the long bones in addition to the common roentgenographic findings.

Case Report

A 40-year-old white man was first examined at the Cleveland Clinic in March, 1954, because of excessive thirst (consuming two gallons of water daily), frequency of urination, and loss of libido. On physical examination the only abnormal finding was small testes. Roentgenograms of the skull were normal. The chest roentgenogram showed evidence of a finely nodular infiltrate, particularly in the upper lobes, suggestive of sarcoidosis; however, the Nickerson-Kveim test was negative. The clinical impression was that of pituitary insufficiency with diabetes insipidus.

Two years later, in 1956, he was re-examined because of multiple symptoms, including the recurrence of those of pituitary insufficiency, generalized weakness, and pain in the ankles. Roentgen examination at that time revealed no change in the appearance of the chest. Roentgenograms of the skull again demonstrated evidence of a normal sella turcica, but there were two radiolucent areas in the parietal region. Roentgenograms of the right ankle gave evidence of a pathologic fracture of the talus with collapse, and obvious bony defects about the ankle (*Fig. 1*). Bone survey studies evidenced diffuse involvement of the skeleton, with the exception of the spine, by multiple, small, rounded defects (*Figs. 2 and 3*). The serum calcium content was 9.0 mg., and the serum phosphorus content 5.5 mg. per 100 ml. The alkaline phosphatase concentration was normal.

Because of the peculiar roentgenographic findings in the long bones, a biopsy of the tibia was performed. The tissue that was removed was lemon yellow, soft, and homogeneous, with a few intermingled bony spicules. Microscopic examination revealed replacement of the marrow by various abnormal cells, large numbers of which had an abundant, definitely vacuolated cytoplasm and relatively small nuclei. These cells were

*Formerly Member of the Staff of the Department of Radiology; present address: 10515 Carnegie Avenue, Cleveland, Ohio.

intermingled with multinucleated giant cells that had the same type of vacuolated cytoplasm (*Fig. 4*). Large numbers of lymphocytes and a few eosinophils were present. Sudan IV stains of frozen sections faintly colored the cells having vacuolated cytoplasm (*Fig. 5*). Examination with polarized light demonstrated that the intracytoplasmic sudanophilic material was anisotropic; the Schultz stain was positive for cholesterol. A correlation of these pathologic findings with the clinical features resulted in the diagnosis of Hand Schüller-Christian disease.

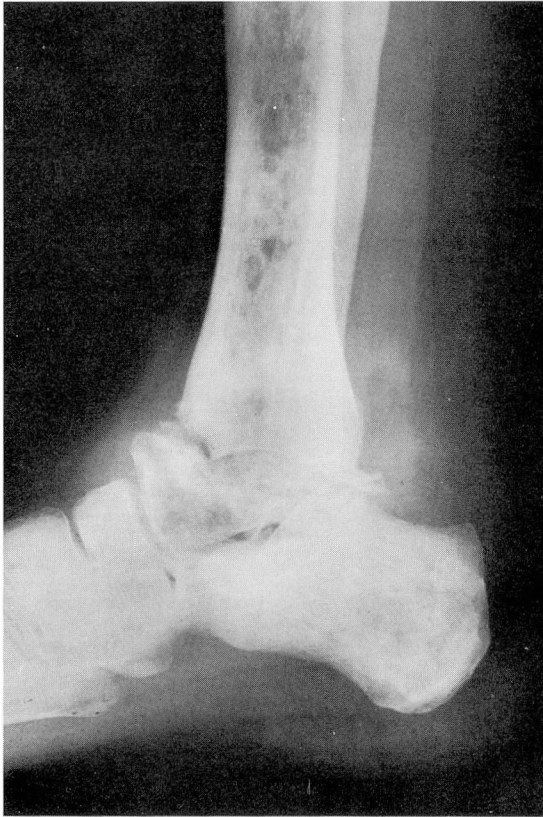


Fig. 1. Roentgenogram of the right ankle with evidence of a pathologic fracture of the talus and, in addition, multiple small radiolucent defects in the tibia, the fibula, and the bones of the foot.

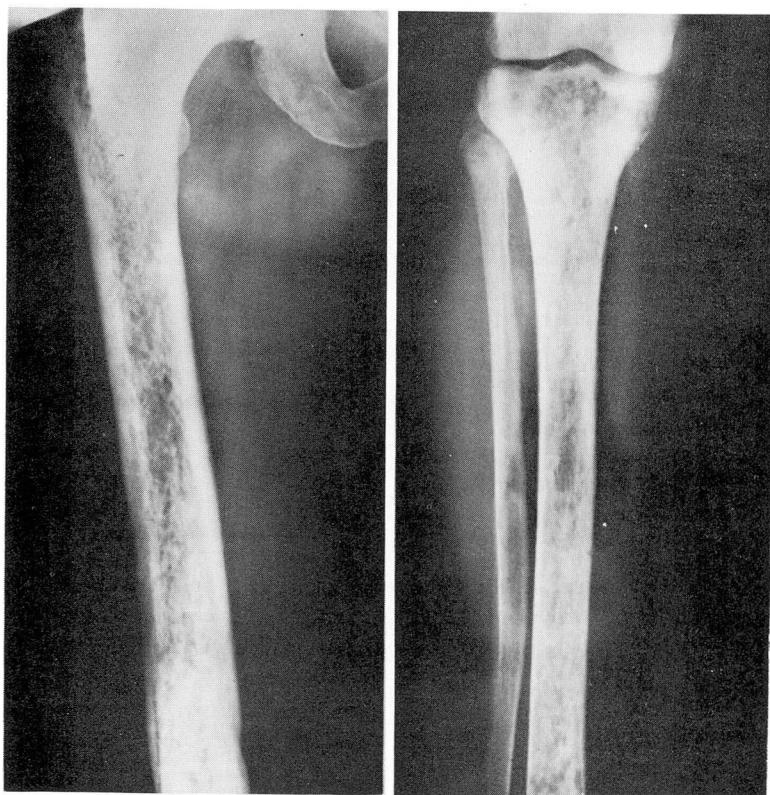


Fig. 2. Roentgenograms of the femur and of the tibia and fibula, with evidence of numerous small radiolucent defects.

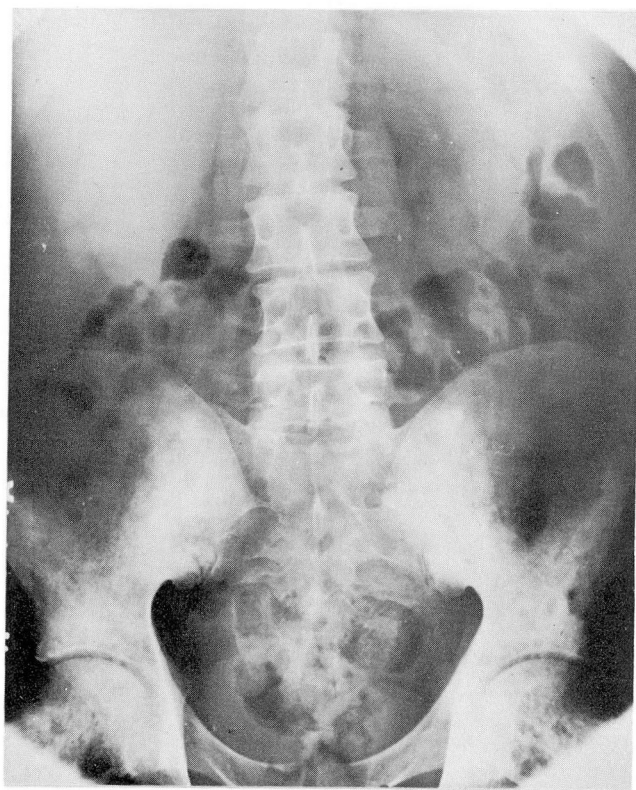

Fig. 3. Roentgenogram of the pelvis showing evidence of numerous small islands of osseous loss similar to those observed in the extremities. The vertebrae apparently are not involved.

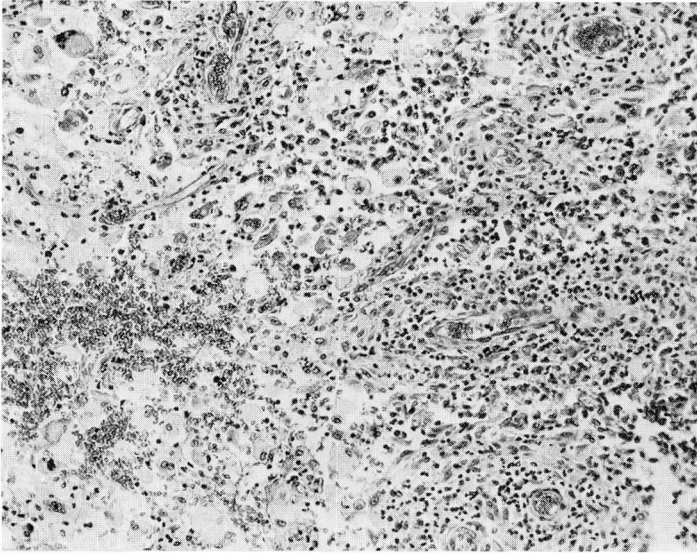


Fig. 4. Photomicrograph of a routinely processed histologic section of tissue from the tibia, with evidence of abnormal tissue formed by cells with an abundant, finely vacuolated cytoplasm, and single, round, vesicular nuclei, multinucleate giant cells, and lymphocytes. Hematoxylin-eosin — methylene blue stain; magnification x 140.

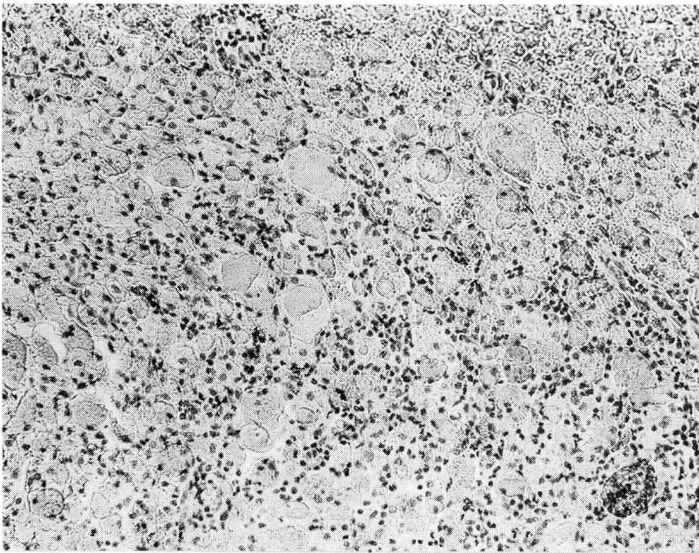


Fig. 5. Photomicrograph of a frozen section of tissue from the tibia, with evidence of slight sudanophilia. Sudan IV stain; magnification x 140.