

VAN NECK'S DISEASE—FACT OR FICTION?

E. HOWARD JAYNE, M.D.,* and THOMAS F. MEANEY, M.D.†

Department of Radiology

VAN Neck¹ in 1924 described two children who had swelling and demineralization of the ischiopubic synchondrosis with local pain and soft-tissue reaction. Since then, the term "Van Neck's disease" ("ischiopubic osteochondrosis") has been applied to the roentgen evidence of osseous swelling of the ischiopubic synchondrosis with or without other manifestations. This paper is presented to review the pertinent literature briefly, and to clarify the currently prevalent opinion that the roentgen findings of Van Neck's disease are actually only normal developmental variations.

The development of the pubic bone begins in the fetus during the fifth or the sixth month, when the center of ossification is formed in the horizontal ramus at the edge of the obturator foramen.² The ischium normally begins to ossify in the superior ramus in the fetus during the fifth month. As growth progresses, the cartilage between the ischial and the pubic rami is replaced by bone until fusion occurs. This area, called the "ischiopubic synchondrosis," undergoes fusion relatively early in childhood, whereas in the acetabular region, synostosis does not occur until puberty.

Köhler² believes that ischiopubic osteochondrosis is observed chiefly in children from nine years to 12 years of age. He attributes the vesicular appearance to a developmental disturbance at the site of fusion.

Both of Van Neck's¹ patients had pain and regional signs of inflammation. The histologic diagnosis based on the findings in the biopsy specimen of bone was osteochondritis. In both cases incision and drainage gave prompt relief of symptoms with somewhat slower regression of the osseous change.

In 1933, Heeren³ reported that of 100 asymptomatic children whom he examined, 16 had the roentgen findings described by Van Neck. More recently, Junge and Heuck⁴ studied the roentgen findings in 358 asymptomatic children ranging in age from five to 15 years. Approximately one seventh of the children had distention or thickening of the ischiopubic synchondrosis. They⁴ concluded that muscular insertions in the area produce a stress reaction in the bone, and that inflammation had no part in producing the roentgen findings.

A complete survey was published by Caffey and Ross⁵ in 1956. Roentgenograms of 549 children between the ages of two years and 12 years were studied. The roentgenograms were selected on the basis of a review of the clinical histories of the children; none were included of any child who had a systemic disease that

* Fellow in the Department of Radiology.

† Formerly member of the Staff of the Department of Radiology; present address: 10515 Carnegie Ave., Cleveland, Ohio.

could have affected osseous development, or any regional signs or symptoms of a disease process. Each patient's roentgenograms were examined to determine the time at which fusion had occurred, and whether there was evidence of swelling or uneven mineralization. More than 50 per cent of the children from six years to 10 years of age had evidence of unilateral or bilateral swelling and uneven mineralization. Of the 549 children, 246 (45 per cent) at some time had evidence of osseous swelling of the ischiopubic synchondrosis.

Caffey and Ross⁵ concluded that fusion of the ischial and pubic rami occurred at varying times in children between the ages of four years and 12 years; in many children fusion was preceded by osseous swelling that sometimes persisted for several years. They believed that the high incidence of the osseous swelling in healthy children suggested that Van Neck's disease is rare, and that many of the examples published are variations in normal growth. Our experience confirms their conclusion.

Material and Method

In order to visualize the normal process of osseous growth and fusion of the ischiopubic synchondrosis, serial roentgenograms were selected from films taken at the Cleveland Clinic during the months of June, July, and August, 1958. These roentgenograms (*Figs. 1 through 8*) trace the development of the ischiopubic synchondrosis in children from the age of five days to three years, when fusion is complete. The clinical history of each patient was analyzed to exclude those histories in which symptoms could be attributed to a disease entity or pathologic process involving the ischiopubic synchondrosis or contiguous areas.

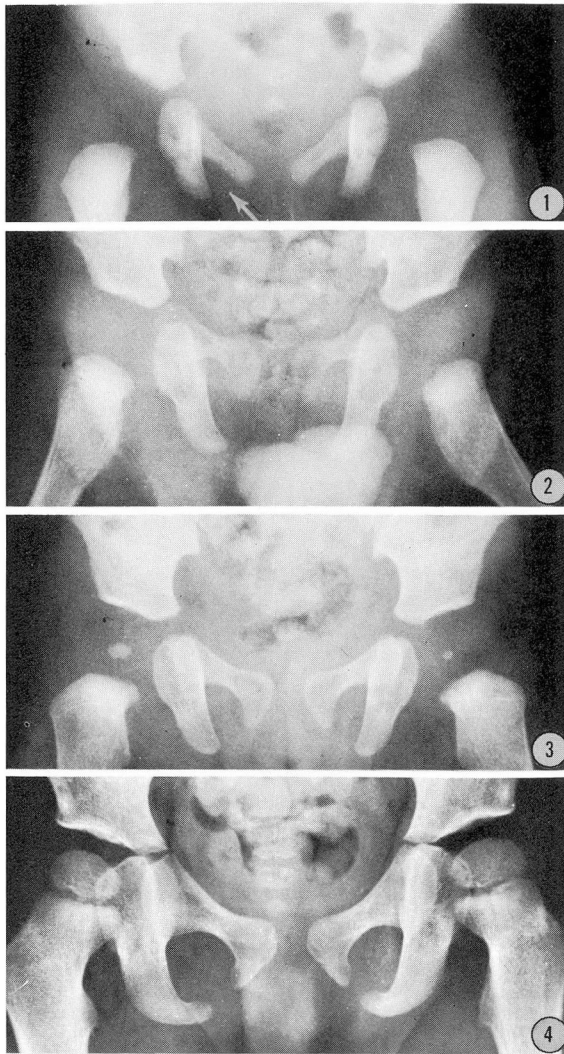
Figures 9 through 16 were among the roentgenograms obtained during the routine examination of 86 children, none of whom had any signs or symptoms referable to Van Neck's disease. The diagnosis at the time of roentgen examination is presented in each legend.

Summary

Since Van Neck's published paper in 1924, the term "Van Neck's disease" has been applied to any ischiopubic synchondrosis that roentgenographically is observed to be swollen or demineralized. Although both of Van Neck's patients had localized inflammation, the diagnosis of Van Neck's disease is made today on the basis of the roentgen findings in children who are free of regional inflammatory signs, and sometimes even in those who are free of regional symptoms.

Several detailed studies have been made and the incidence of Van Neck's roentgen findings is so high in asymptomatic children that the current opinion is that the roentgen findings of Van Neck's disease are normal variations in the development of the ischiopubic synchondrosis.

Roentgenograms illustrating the usual fusion process of ischiopubic synchondrosis



Figures 1 through 8 demonstrate the gradual fusion as it occurs in children from the ages of five days to three and one-half years. Fig. 1. Five days. (Infant girl examined because of problem in feeding; diagnosis undetermined.) Fig. 2. Three months. (Infant boy; diagnosis, cerebral atrophy.) Fig. 3. Six months. (Infant girl; diagnosis, ovarian agenesis.)

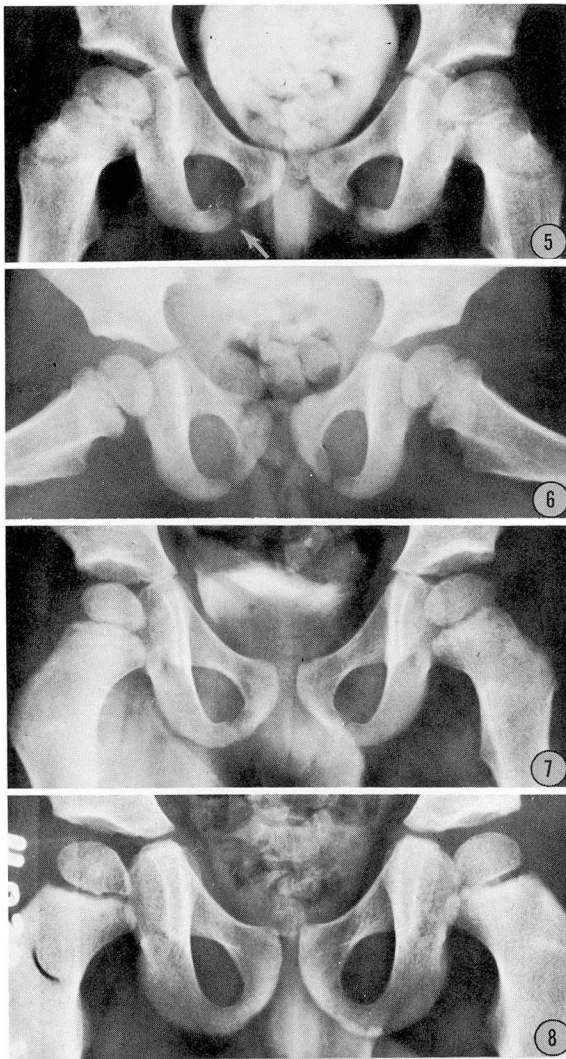
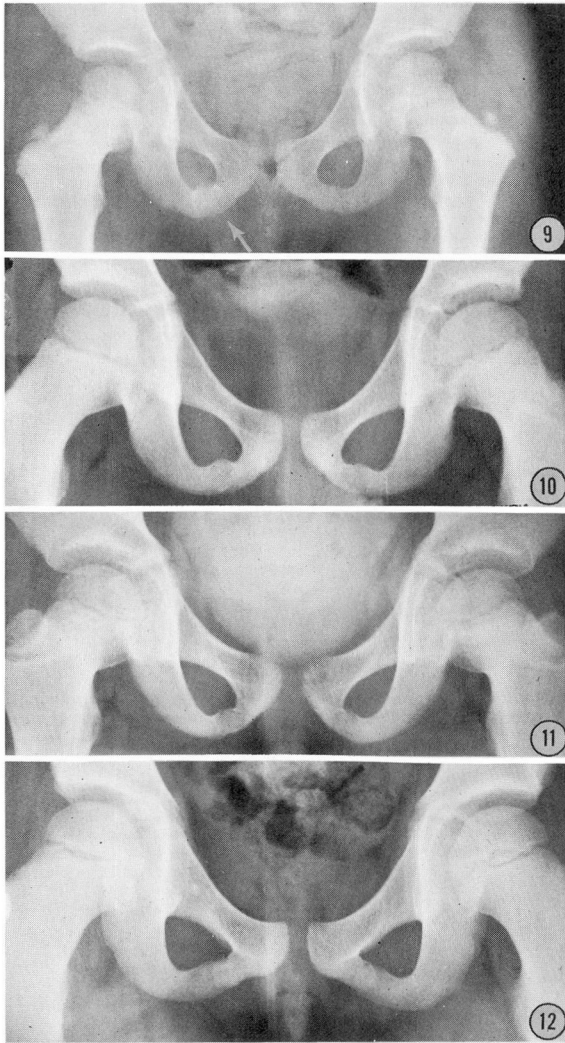


Fig. 4. Twenty-four months. (Girl; diagnosis, pigmented nevus on the back.) Fig. 5. Forty months. (Girl; diagnosis, tubercular node in the neck, but no abnormal roentgen findings. Fig. 6. Thirty months. (Girl; diagnosis, retinoblastoma.) Fig. 7. Thirty-six months. (Boy; diagnosis, nephrosis.) Fig. 8. Thirty-six months. (Boy; diagnosis, postpolio weakness.)

Roentgenograms illustrating normal variations
of the usual fusion process of ischiopubic synchondrosis



Figures 9 through 16 demonstrate the so-called "swelling" and "cystic changes" in patients from five years to 15 years of age with no signs or symptoms referable to those areas. Note that in some there is evidence that the process is unilateral. Fig. 9. Five years. (Boy; diagnosis, mental retardation.) Fig. 10. Six years. (Boy; diagnosis, nephrosis.) Fig. 11. Six and one-half years. (Girl; diagnosis, urethritis.)

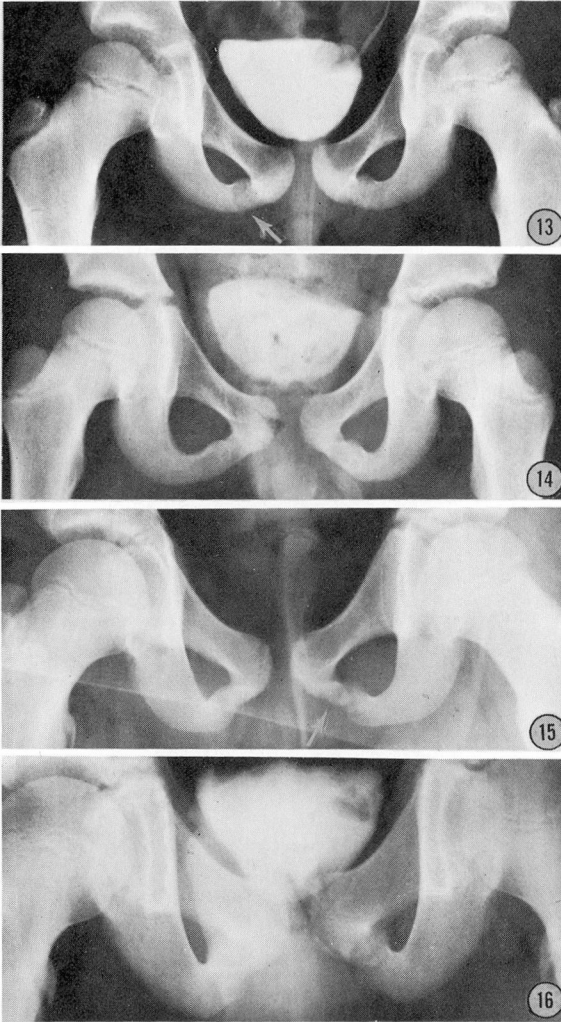


Fig. 12. Seven years. (Girl; diagnosis, pharyngitis.) Fig. 13. Seven years. (Boy; diagnosis, staphylococcal enteritis.) Fig. 14. Eight years. (Boy; diagnosis, chronic cystitis.) Fig. 15. Thirteen years. (Boy; diagnosis, sickle-cell trait.) Fig. 16. Fifteen years. (Boy; diagnosis, urinary frequency.)

References

1. van Neck, M.: Ostéochondrite du pubis. (Osteochondritis des Os pubis.) Arch. franc. belg. chir. 27: 238-240, 1924. Abstr. in Zentralorg. ges. Chir. u. Grenzgeb. 29, 1925.
2. Köhler, A.: Borderlands of the Normal and Early Pathologic in Skeletal Roentgenology. English trans. arr. and ed. by J. T. Case; 10th ed. by E. A. Zimmer, pp. 458-462. New York: Grune & Stratton, Inc., 1956, 723 pp.
3. Heeren, J.: Über röntgenologisch nachweisbare Veränderungen der Scham-Sitzbeinepiphyse und ihre klinische Bedeutung. Röntgenpraxis 5: 12-16, 1933.
4. Junge, H., and Heuck, F.: Die Osteochondropathia ischiopubica (gleichzeitig ein Beitrag zur normalen Entwicklung der Scham-Sitzbeingrenze im Wuchstumsalter) Fortschr. Geb. Röntgenstrahlen 78: 656-668, 1953.
5. Caffey, J., and Ross, S. E.: Ischiopubic synchondrosis in healthy children: some normal roentgenologic findings. Am. J. Roentgenol. 76: 488-494, 1956.