

Cleveland Clinic Quarterly

Volume 26

OCTOBER 1959

No. 4

FATTY INFILTRATION IN THE LIVER — RESPONSE TO TREATMENT

CHARLES H. BROWN, M.D., and MAURO MERLO, M.D.*

Department of Gastroenterology

INFILTRATION of fat in the liver may be produced experimentally in animals by dietary restriction of proteins, choline and precursors of choline, vitamin-B complex, as well as by the administration of hepatotoxins. Von Mering and Minkowski,¹ in studying diabetes, reported in 1890 the frequent occurrence of fatty liver in depancreatized dogs. In 1924, Allan, Bowie, Macleod, and Robinson,² and Fisher³ noted that large fatty livers developed in depancreatized dogs maintained on insulin for long periods. These findings led one of us (C.H.B.⁴) to suggest that liver function studies should be conducted on all diabetic patients.

In 1932, Best, Hershey, and Huntsman⁵ by dietary means produced fatty infiltration in the livers of normal rats in about three weeks, while six months was required for similar changes to appear in the depancreatized dog. Chaikoff and associates^{6,7} produced definite cirrhotic changes both in pancreatectomized and in normal dogs by prolonged feedings of diets that stimulated the accumulation of fat in the liver. Subsequently, several other investigators reported similar lesions occurring in rats on deficient diets.

Best, Hartroft, and Sellers⁸ reported that in experimental animals on a low-choline diet, stainable lipids first appeared in the liver as small intracellular globules. Subsequently the globules coalesced to form large spherical masses distending the cell membrane. The membranes of the liver cells, distended with fat, were increasingly stretched until the cell membranes broke and fatty cysts were formed in from six to nine weeks. With the rupture of the fatty cysts,

*Fellow in the Department of General Medicine.

definite cirrhotic changes occurred with fibrosis and increase in connective tissue.

Allan and associates² reported that the fatty infiltration of the liver in depancreatized dogs was prevented by the oral administration of raw beef pancreas. Hershey,⁹ and Hershey and Soskin¹⁰ reported that crude egg lecithin produced the same protective effect as that of raw beef pancreas. Best and associates^{5,8} identified choline as the active principle in lecithin. They reported that, within limits, after using a diet deficient in protein or choline for approximately six weeks, the administration of choline reversed the fatty infiltration and prevented the development of fibrosis. After the fatty cysts had ruptured, the subsequent administration of choline did not prevent the development of fibrosis or cirrhotic changes.

The lipotropic effect of these substances has been thought to result from an increase in the formation and turnover of phospholipids.¹¹ In the experimental animal, Artom and Cornatzer,¹² and Perlman, Stillman, and Chaikoff¹³ by using radioactive phosphorus have shown that choline and methionine will increase the phospholipid turnover in the liver.

Laennec's cirrhosis in man has been thought by many to result from the same mechanism as that which produces cirrhosis in the experimental animal; this concept has not been proved.¹⁴ While dense fatty infiltration of the liver frequently occurs in man, the large fatty cysts as seen in the experimental animal have not been observed.

Not one, but various types of fatty infiltration of the liver may occur in man, and each type may respond to a therapy designed to correct the specific etiologic agent. Fatty liver may be classified⁸ on the basis of four general causes: (1) dietary deficiencies (specifically proteins, choline, and vitamin-B complex); (2) hormonal imbalance (insulin deficiency); (3) lack of oxygen (anemia or ischemia of liver cells); and (4) toxic or infectious processes that damage the liver cell.

Extensive fatty infiltration of the liver can cause enlargement of the liver, ascites, edema, jaundice, and all of the clinical and laboratory findings of hepatic failure. Clinically, the response of the patient with fatty infiltration of the liver is much better than that of the patient with severe fibrosis. In a patient in hepatic failure we prefer to see only fatty infiltration on the needle biopsy^{15,16} since there is a much more favorable prognosis than if considerable fibrosis is present. As in the experimental animal, in man the fatty liver with no fibrosis can be restored to normal function and architecture by adequate treatment. In contrast, there is little we can do to remove the scarring or fibrosis that has already occurred.

Report of Cases

The following case histories are presented to demonstrate: (1) the great severity of hepatic failure that can be associated with extensive fatty infiltration of the liver; (2) the diminution in fat in the liver after intensive medical therapy,

as shown by serial specimens of needle biopsies of the liver; (3) the improvement in the clinical picture and in the results of liver function studies after medical treatment.

Case 1. A 48-year-old woman was first admitted to the Cleveland Clinic Hospital on February 27, 1959, because of jaundice, progressive abdominal distention, and loss in weight of four weeks' duration. She previously had had prolonged treatment for chronic alcoholism in three other hospitals, and also had been hospitalized for "liver disease" and ascites in 1952; paracentesis had been performed several times and 3,700 ml., 10,800 ml., 300 ml., and 4,500 ml., respectively, of ascitic fluid had been removed.

Physical examination revealed a poorly nourished, emaciated, chronically ill patient who was 62 inches tall and weighed 113 pounds. The skin was jaundiced and palmar erythema was present. The abdomen was distended with fluid, a fluid wave being present; the liver was enlarged 8 cm. below the costal margin, and the spleen was palpable.

Laboratory examinations showed the blood count, blood sugar, blood urea, Wassermann test results, serum electrolytes, stool, and urinalysis to be normal or negative. Liver function studies (*Table 1*) showed the presence of moderate jaundice, a

Table 1.—*Results of liver function tests in case 1*

Test	1959			
	February	April	May	July
Bilirubin, mg./100 ml.				
Direct	18.8, 15.1	2.2, 3.6	0.6	0.5
Indirect	20.0, 11.1	1.1, 2.4	1.4	0.2
Albumin, gm./100 ml.	2.3, 3.10	3.29	3.3	4.40
Globulin, gm./100 ml.	2.7, 2.40	2.29	3.5	2.70
Prothrombin time, percentage of normal control	68%	86%	80%	100%
Serum transaminase, S. G. O. units	160	115, 35	—	20
Thymol, units	7	3	3	4
Cephalin, units	2 +	1 +	0	0

reversal of the albumin-globulin ratio, and indications of active liver disease with an elevation of the transaminase and a 2 plus cephalin-cholesterol flocculation test. The electrocardiogram was normal. Roentgenograms revealed a normal chest and colon, but examination of the esophagus suggested small varices throughout.

Treatment consisted of a 3,000-calorie diet, high in proteins and carbohydrates, but low in salt and fat; choline dihydrogen citrate, 20 gr., three times daily; vitamin-B

complex twice daily; Decadron,* 0.75 gr. twice daily, and neomycin, 0.5 gm. four times daily. She also received parenteral injections of vitamin K, vitamin B₁₂ every other day, mercuhydrin daily, and depotestosterone twice weekly. Because of her extreme nervousness, she was given a course of prochlorperazine, 10 mg. four times daily. A few days later, a Parkinson-like syndrome† with tremor of the hands developed, which disappeared when administration of prochlorperazine was discontinued and Artane‡ and Cogentin§ were given. After five weeks she was discharged (April 7, 1959) and was advised to continue with the same therapy. Significant improvement was observed in the results of liver function studies and in the jaundice, and a notable diminution in the extent of fatty changes in the liver as demonstrated by repeated needle biopsies (*Fig. 1*).

Six weeks later (in May) when she underwent progress studies she appeared improved. She had abstained from alcohol and had followed the program she received in the hospital. Her appetite had increased and she had gained 13 pounds. There no longer was any evidence of ascites or jaundice, and the liver was not palpable.

Repeated liver function tests substantiated her clinical improvement (*Table 1*). Changes in therapy at that time included discontinuance of Decadron and mercuhydrin, a reduction in the number of vitamin-B₁₂ injections to one each week, and the giving of vitamin K orally rather than parenterally. The choline dosage was reduced to 10 gr. three times daily. When last examined as an outpatient on July 24, 1959, her general condition was still improving. She had a good appetite and had gained 29 pounds in six months; she had abstained from alcohol; there was no evidence of jaundice, hepatomegaly, or ascites.

Case 2. A 65-year-old railroad conductor was admitted to the Cleveland Clinic Hospital on April 15, 1959, because of an episode of hematemesis involving about a half cupful of bright-red blood. He had not had any tarry stools, but for several weeks he had occasional nausea and vomiting of clear fluid. He was a chronic alcoholic throughout adulthood, and for the last few months had missed many days of work because of increased alcoholic intake. He had a history of duodenal ulcer with massive hemorrhage in 1939, but had no symptoms of ulcer since then. In July, 1950, he was operated on for papillary transitional carcinoma of the bladder; cystectomy and bilateral ureterosigmoidostomy were performed.

Physical examination revealed an elderly plethoric man who weighed 150 pounds; he was nervous, agitated, and had a coarse tremor of the head, shoulders, and hands. The skin was not jaundiced; palmar erythema was present. The liver was soft, non-nodular, and was enlarged 6 cm. under the right costal margin.

The significant laboratory findings were as follows: the blood hemoglobin content was 16.5 gm. per 100 ml., white-cell count 5,200 per cu. mm., and a normal differential count. Two consecutive stool examinations for occult blood were negative. Blood urea was 24 mg. per 100 ml. The urinalysis, blood sugar, electrolytes and results of the

*Decadron (dexamethasone), Merck Sharp & Dohme.

†We have seen a Parkinson-like syndrome in four other patients with severe liver disease; two of these patients had undergone portacaval shunt procedures. In each instance, the Parkinson-like syndrome was aggravated by prochlorperazine.

‡Artane (tribexyphenidyl), Lederle Laboratories.

§Cogentin (methanesulfonate (benztropine methanesulfonate, Merck)), Merck Sharp & Dohme.

Wassermann test, were either normal or negative. The liver function studies showed high retention of Bromsulphalein (*Table 2*).

Table 2.—*Results of liver function tests in case 2*

Test	1959	
	April	July
Bilirubin, mg./100 ml.		
Direct	0.2	0.2
Indirect	0.8	0.2
Albumin, gm./100 ml.	4.16	3.67
Globulin, gm./100 ml.	2.49	2.78
Prothrombin time, percentage of normal in 14 sec.	100%	100%
Cephalin, units	0	0
Bromsulphalein, percentage of retention in 45 minutes	21%	3%
Alkaline phosphatase, units	2.9	—

Roentgenograms of the esophagus, stomach, and duodenum showed no abnormality. Esophagoscopy, performed a few days later, showed no evidence of erosion, ulceration, or varices throughout the entire length of the esophagus. An intravenous urogram showed evidence of bilateral caliectasis, and a roentgenogram of the chest was normal.

The patient was given the following regimen: rest; a 3,000-calorie diet, high in proteins and carbohydrates; vitamin-B complex, three times daily; supplemental protein feeding, two and one-half hours after meals; an anticholinergic agent, four times daily; an antacid, four times daily; and sedation. The cause of the hematemesis remained undetermined and was thought to have been associated with the strain of retching and not due to ulcers or varices. He was discharged from the hospital and advised to follow the above-outlined program. On July 1, 1959, he was readmitted for progress studies. At that time the patient was feeling well; he had gained ten pounds in weight. He had had no hematemesis or tarry black stools since April. The liver was not palpable.

The Bromsulphalein retention tests showed improvement in liver function (*Table 2*), and a specimen of a needle biopsy of the liver showed a significant decrease in fatty infiltration (*Fig. 2*).

Case 3. A 50-year-old woman was admitted to the Cleveland Clinic Hospital on February 2, 1959, because of epigastric pain (relieved by alkali and food) loss of 25 pounds in weight, and severe generalized malaise of one year's duration. These symptoms were dated from a cholecystectomy, which was performed in 1958 at another hospital. She customarily consumed a half pint to one pint of whisky a day for many years.

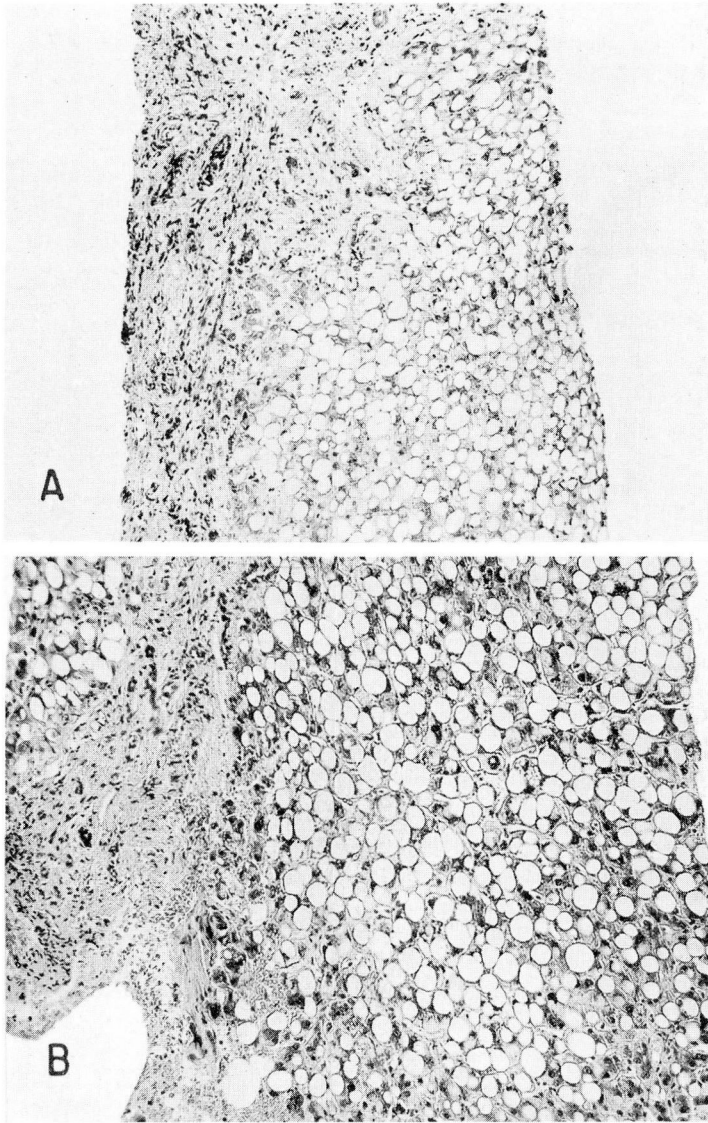
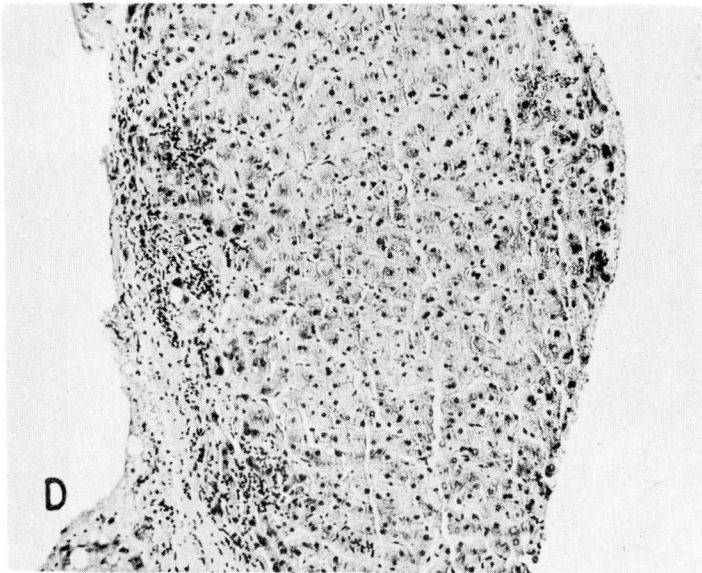
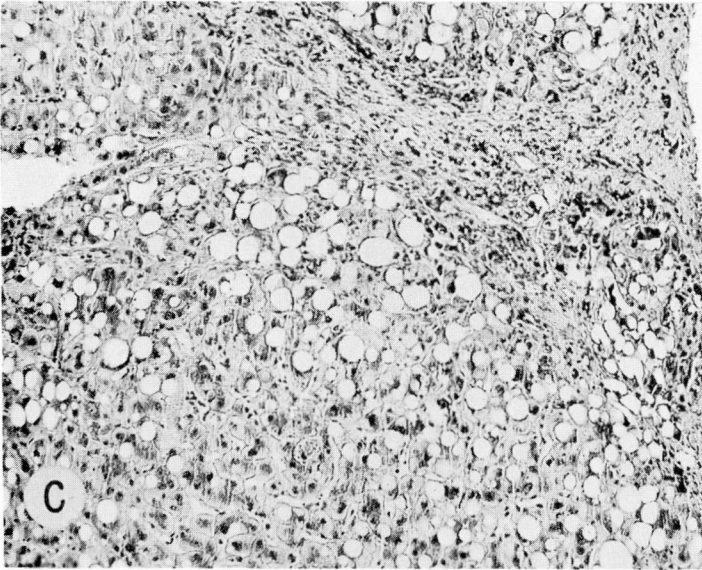


Fig. 1. Case 1. A, Needle biopsy specimen on March 3, 1959. Section shows extensive fatty replacement with only sparse parenchymal cells scattered between the fat globules. Some fibrosis is seen in the periportal areas (on the left side); magnification $\times 100$. B, Needle biopsy specimen on March 17, 1959, again shows an extensive infiltration of fat in the hepatic parenchyma. Some bile stasis is present within the hepatic nodules, which are separated by moderately broad fibrotic portal zones containing proliferating bile ducts and a minimal amount of chronic inflammatory infiltrate; magnification $\times 100$. C, Needle biopsy specimen on April 2, 1959, revealing a decrease in the fatty



change and in the bile stasis in comparison with the two previous specimens. Periportal fibrosis is present, but some normal liver cells without fat globules, which are difficult to find on the previous specimens, are present; magnification x 100. D, Needle biopsy specimen on May 11, 1959, reveals almost complete disappearance of fat. The hepatic parenchymal cells, which were hardly visible in the first biopsy specimen, now show no significant abnormality. The normal lobular architecture is still distorted by bands of connective tissue and fibrosis; magnification x 100.

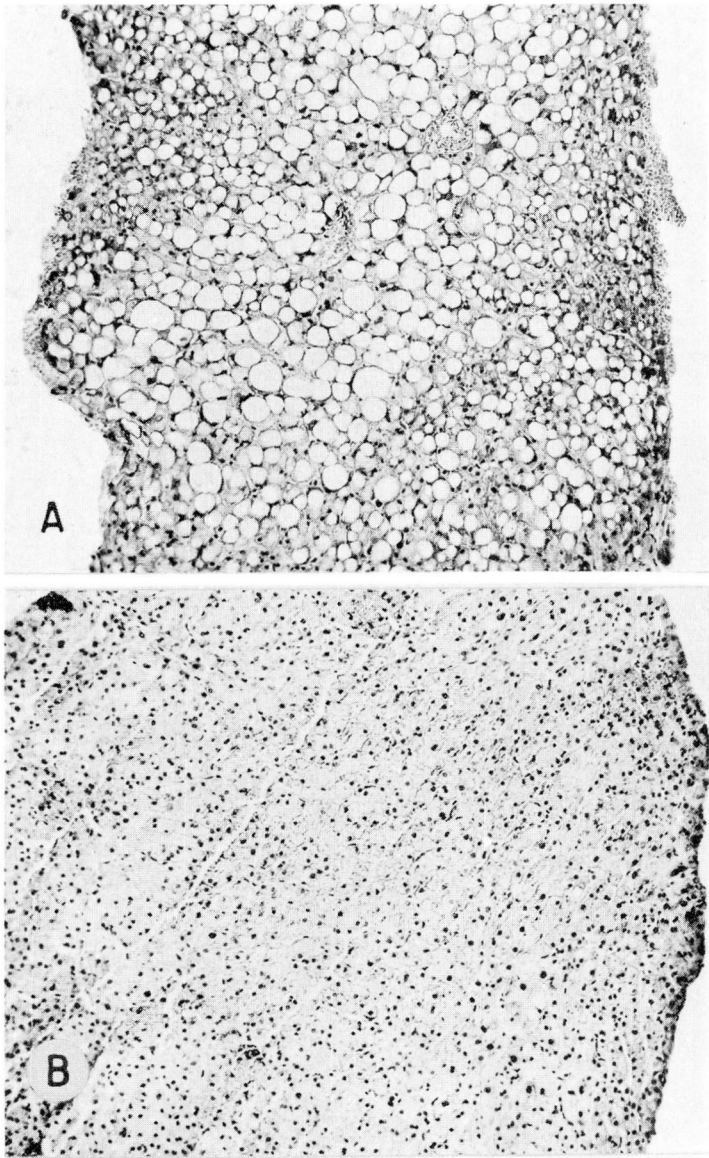


Fig. 2. Case 2. A, Needle biopsy specimen on April 17, 1959, showing an extensive fatty replacement throughout the entire specimen; magnification $\times 100$. B, Biopsy specimen on July 1, 1959, showing a marked decrease in the fatty infiltration; the liver cells appear well-glycogenated with only an occasional cell showing fat in the cytoplasm. In contrast to case 1, there does not appear to be an increase in fibrous tissue; magnification $\times 100$.

The physical examination revealed a pale and emaciated woman who was 62 inches tall and weighed 99 pounds. Palmar erythema and icterus of the sclerae were present. The abdomen was distended; a fluid wave was found. The liver was enlarged, extending 10 cm. below the right costal margin, with a sharp edge, and was tender to palpation. The spleen was palpable.

The significant laboratory findings were as follows: blood hemoglobin concentration, 11.4 gm. per 100 ml.; and a white-cell count, 5,100 per cu. mm. with a normal differential count. A guaiac test of the stool was positive. The blood sugar, blood urea, urinalysis, serum electrolytes, and Wassermann test results were either normal or negative. The liver function studies showed impaired function (*Table 3*).

Table 3.—*Results of liver function tests in case 3*

Test	1959		
	February	April	August
Bilirubin, mg./100 ml.			
Direct	0.7	0.5	0.2
Indirect	1.2	0.7	0.2
Albumin, gm./100 ml.	3.0	3.3	4.5
Globulin, gm./100 ml.	2.5	3.5	2.7
Prothrombin time, percentage of normal control	62% (19 sec.)	100% (14 sec.)	100% (14 sec.)
Thymol, units	6	7	4
Cephalin, units	2 +	1 +	0
Bromsulphalein, percentage of retention in 45 minutes	19%		.
Alkaline phosphatase, units	6.4	—	3.5

Treatment in the hospital consisted of: a smooth diet high in proteins and carbohydrates, and low in salt; a lipotropic agent three times daily, multivitamins twice daily; prochlorperazine, 10 mg., three times daily; and intramuscular injections of vitamin K, once a day. The patient also received an intramuscular injection of vitamin B₁₂, 1,000 µg., twice weekly. The course in the hospital was uneventful. She was discharged on February 20 and was asked to continue the same therapy with strict avoidance of alcohol.

She was re-examined in April, 1959. At that time she was feeling much better, her appetite had increased, and she had gained 14 pounds in weight. The liver was still palpable, 4 cm. below the right costal margin, but there was no evidence of ascites. In the meanwhile, a Parkinson-like syndrome developed, which promptly disappeared when administration of prochlorperazine was discontinued and Artane with a meprobamate was given (see footnote to case 1).

On August 5, 1959, she was admitted to the hospital because of an accidental fracture of the eighth dorsal vertebra two months previously. At this time, the results of liver function tests showed a remarkable improvement (*Table 3*). Progress needle biopsy specimens of the liver substantiated the clinical and laboratory improvement in the liver function (*Fig. 3*). She was discharged on August 12 and was advised to follow this program: a high-protein, low-salt diet; vitamin-B complex, once a day; vitamin-B₁₂ injections once a week; chlorothiazide, 0.5 gm. three times a week; meprobamate, 400 mg. four times daily.

Case 4. A 40-year-old physician was examined at the Cleveland Clinic Hospital on August 17, 1948, because of dizzy spells and mental fatigue of six weeks' duration. He had been a heavy drinker most of his adulthood, consuming from one to three quarts of whisky daily.

The physical examination revealed an obese patient who weighed 250 pounds. The skin was jaundiced. The liver was smooth, soft, and enlarged, extending 12 cm. below the right costal margin. The results of laboratory examinations were as follows: the blood hemoglobin content, 12.0 gm. per 100 ml.; a white-cell count, 6,350, and a normal differential count. The urinalysis, blood sugar, serum electrolytes, and Wassermann test results were either normal or negative. The results of the liver function studies are presented in *Table 4*. Roentgen examination of the gastrointestinal tract revealed a duodenal diverticulum and multiple diverticula in the hepatic flexure and the sigmoid colon.

Table 4.—*Results of liver function tests in case 4*

Test	Aug., 1948	June, 1949	Nov., 1949	Jan., 1950	July, 1950	July, 1951	Jan., 1952	July, 1953	April, 1956
Bilirubin, mg./100 ml.	0.8 (Total)	2.5 (Total)	0.8 (Total)	2.5 (Total)	—	0.4 (Direct) 0.5 (Indirect)	—	0.3 (Direct) 0.5 (Indirect)	0.3 (Direct) 0.5 (Indirect)
Albumin, gm./100 ml.	4.8	—	—	5.2	—	4.9	5.4	4.9	—
Globulin, gm./100 ml.	4.3	—	—	4.4	—	3.3	3.6	3.3	—
Prothrombin time, percentage of normal control	—	—	100%	100%	—	100%	100%	—	—
Thymol, units	1.6	—	—	1.0	—	—	—	—	—
Cephalin, units	—	—	0	—	—	0	—	0	—
Bromsulphalein, per- centage of retention in 45 minutes	32%	24%	28%	12%	18%	15%	20%	15%	7%
Alkaline phosphatase, units	4.6	—	—	—	—	—	—	—	—

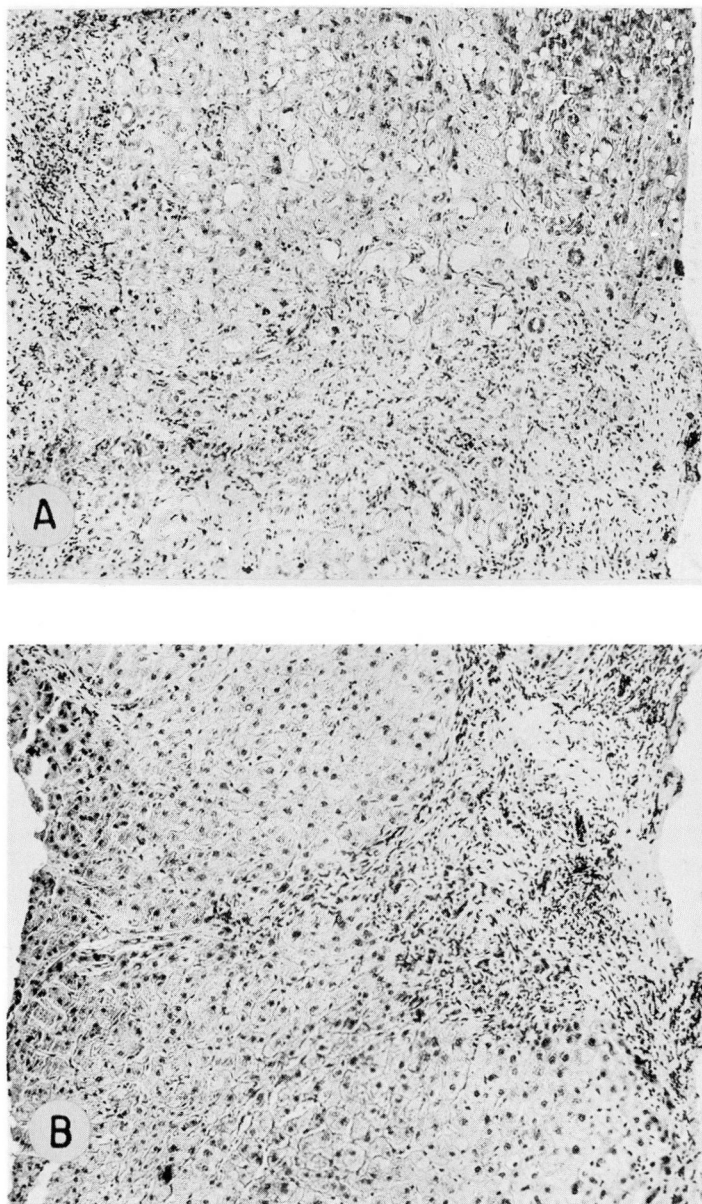


Fig. 3. Case 3. A, Needle biopsy specimen on February 6, 1959, revealing distortion of the normal hepatic architecture by broad zones of fibrous and collagenous tissue. The liver cells contain a moderate amount of fat globules; magnification $\times 100$. B, Biopsy specimen on August 6, 1959, shows no change in the fibrosis, but the infiltration of fat has disappeared; magnification $\times 100$.

Treatment in the hospital consisted of a diet that was high in proteins and carbohydrates and low in fat; choline dihydrogen citrate, 10 gr. three times daily; multivitamins, twice a day; and injections of liver extract twice weekly. Upon discharge on August 27 he was advised to follow the same program, and to return for examinations at intervals. Despite the advice to stop drinking, he drank sporadically but followed the rest of the program. The liver gradually decreased in size. It was two fingerbreadths below the right costal margin in March, 1949, one fingerbreadth in June, 1949, and was not palpable in November of the same year.

Because of intermittent episodes of severe pain in the right upper quadrant, along with the nausea and vomiting, the patient was admitted to the hospital on January 1, 1950. Roentgen examination showed a nonfunctioning gallbladder, and a cholecystectomy was performed on January 26. The gallbladder was found to be diffusely inflamed. A biopsy specimen of the liver was obtained (*Fig. 4*).

Postoperatively the patient again began to drink heavily, consuming about two quarts of whisky daily. Despite the alcoholic intake, he followed the diet and continued daily to take choline and multivitamins, and weekly injections of liver extract. At the last examination in April, 1956, the patient had abstained almost entirely from alcohol; the liver was not palpable, and the Bromosulphalein test showed a 7 per cent retention of the dye after 45 minutes.

Treatment of the Patient with Fatty Infiltration of the Liver

The basic treatment for fatty infiltration of the liver was the same for each of the four patients. It should be noted that each of the patients was an alcoholic and each had a nutritional or Laennec's type of cirrhosis (in contrast to postnecrotic cirrhosis). The first three patients cited, abstained completely from alcohol. The fourth patient reduced his alcoholic consumption and followed the rest of his "liver program." Although alcohol itself may not cause the hepatic changes described, we believe that it is essential that patients with liver disease, particularly with Laennec's or nutritional cirrhosis or with fatty infiltration avoid the use of alcohol.

A high-protein, high-calorie intake is as essential to the treatment of liver disease as is the avoidance of alcohol. The actual fat content of the diet is of least importance and is adjusted to keep the diet palatable; vitamin-B complex orally and vitamin B and crude liver extract parenterally, are used primarily to increase the appetite. In addition, supplemental protein feedings, such as one of the protein powders or egg-nogs, are given two hours after meals. Lipotropic substances such as choline are given as a supplement to insure that adequate amounts are available to mobilize the fat from the liver.

Other therapy, such as vitamin K, testosterone and other hormones for the effect on nitrogen metabolism, steroids, and tranquilizers, is given depending upon the individual needs of the patient. Salt restriction is imposed and diuretics are given if there is ascites or edema.

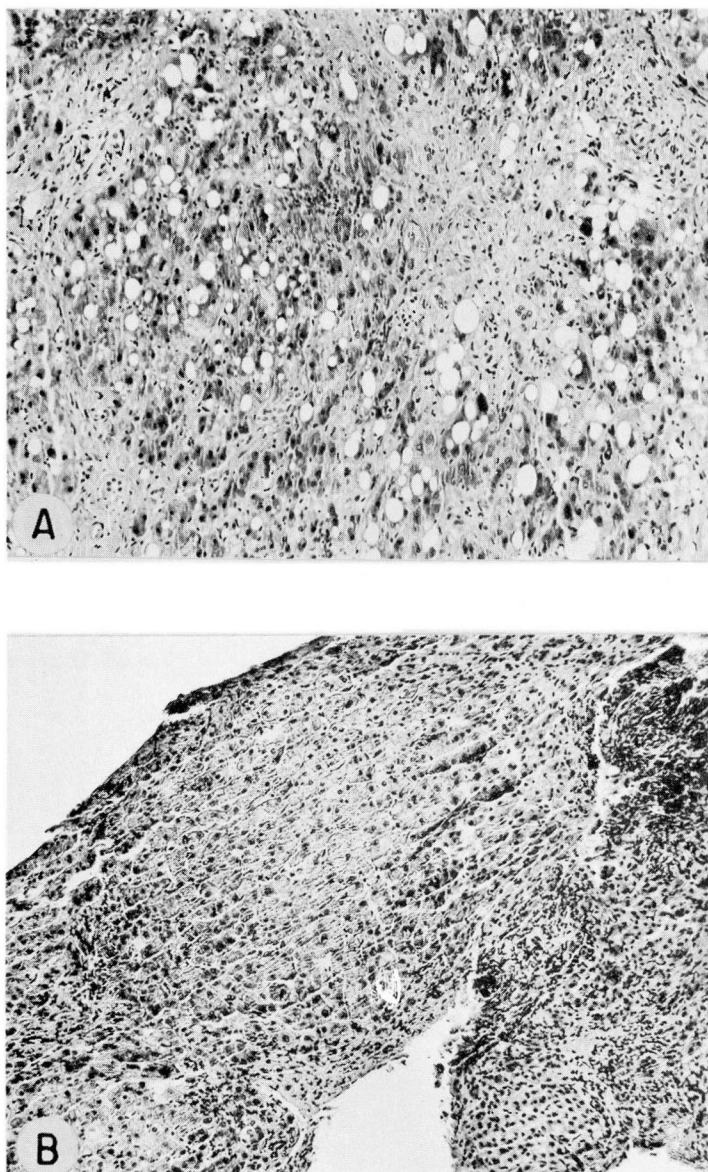


Fig. 4. Case 4. A, Needle biopsy specimen on August 24, 1948, showing an extensive fatty infiltration of the hepatic parenchyma with a moderate increase in periportal fibrous tissue; magnification $\times 100$. B, Needle biopsy specimen obtained at the time of cholecystectomy on January 26, 1950. The same amount of connective tissue in the portal areas is present, but the fat globules in the hepatic cells have disappeared; magnification $\times 100$.

Comment

The lack of choline, as well as of protein and vitamin-B complex in the diet, may produce infiltration and subsequently cirrhosis in rats; this change can be reversed by the administration of choline if fibrosis has not already occurred.⁸ Consequently, choline and other lipotropic agents have been employed in the treatment of patients with liver disease. Histologic and other studies on the effectiveness of choline and other lipotropic agents in humans have not been in agreement. Morrison,¹⁷ Franklin and associates,¹⁸ Beams and Endicott,¹⁹ and Fagin, Sahyun, and Pagel,²⁰ believed from their studies that lipotropic substances including choline, cystine, and methionine, exerted a beneficial effect upon the clinical course of fatty infiltration of the liver. Studies by Cornatzer and Cayer^{21,22} suggested that an insufficient supply of lipotropic material was present in *untreated* cirrhotic patients.

Others have reported beneficial effects on the clinical course of cirrhosis and fatty infiltration of the liver without the use of lipotropic substances. Volwiler, Jones, and Mallory,²³ Buck,²⁴ Klatskin and Yesner,²⁵ Eckhardt and associates²⁶ and Seife, Kessler and Lisa²⁷ have shown that a nutritious diet is beneficial and is associated with effective lipotropism. Choline added to the diet was found to have no additional effect. Post and associates²⁸ have shown on the basis of protein intake of 1 gm. per kilogram of body weight, that effective lipotropism occurred within four weeks. The administration of choline was without added demonstrable effect, either on the clinical response of the patient, on the results of liver function tests, or on the histologic appearance of the liver.

A high-protein intake undoubtedly assures that adequate choline (present in the protein) is available, so that supplemental choline is probably unnecessary. Since choline is inexpensive and an excess is not harmful, each of our patients here reported was given supplemental choline or other lipotropic substances to insure an adequate supply.

The exact role of steroidal therapy in the treatment of liver disease, both hepatitis and cirrhosis, is obscured by many conflicting reports. Creutzfeldt and Kühn²⁹ reported cortisone or prednisone to be of benefit to 26 of 40 patients with enlarged livers (hypertrophic cirrhosis or fatty liver). One of our patients (case 1) was given steroidal therapy (Decadron) with apparent benefit.

Prognosis

The outlook for the patient with fatty infiltration in the liver is excellent with adequate treatment. The decrease in the size of the liver, the improvement in results of liver function tests, the clinical improvement, and the actual decrease in the amount of fatty infiltration in the liver in the four cases cited are typical of the favorable response of patients with fatty livers to adequate treatment. There is little that can be done for fibrosis or scarring that has already occurred in a

cirrhotic liver; however, much can be done for the patient who primarily has fatty infiltration of the liver with little fibrosis. The prognosis is excellent.

Summary

Fatty infiltration of the liver and cirrhosis have been produced experimentally in animals by dietary deficiencies in protein, vitamin-B complex, or choline. The progress toward cirrhosis is reversed by the administration of choline. The application of these studies to the cause and the treatment of cirrhosis in man is obviously desirable, but remains unproved.

Four case histories of severe fatty infiltration of the liver have been presented. Each patient was an alcoholic and was thought to have a nutritional type of cirrhosis. Treatment consisted of avoidance of alcohol, a high-protein and high-calorie diet, supplemental measures including vitamin B to increase the caloric intake, lipotropic agents, and any special measures indicated by the specific findings on the individual patient. All measures that were considered to be of possible benefit in increasing the protein and caloric intake were used.

Treatment in each case resulted in clinical improvement, a decrease in the size of the liver, improvement in results of the liver function tests, and a disappearance of the fat from the liver as shown by serial specimens of needle biopsies. Fibrosis that had already occurred (in cases 1, 3, and 4) persisted despite therapy.

Severe fatty infiltration of the liver may produce all the signs and symptoms of liver failure, including jaundice and ascites. The prognosis, with treatment, is excellent.

References

1. von Mering, J., and Minkowski, O.: Diabetes mellitus nach Pankreasexstirpation. (Diabetes mellitus after pancreatectomy.) *Arch. exper. Path. u. Pharmacol.* 26: 371-387, 1890.
2. Allan, F. N.; Bowie, D. J.; Macleod, J. J. R., and Robinson, W. L.: Behavior of depancreatized dogs kept alive with insulin. *Brit. J. Exper. Path.* 25: 75-83, 1924.
3. Fisher, N. F.: Attempts to maintain life of totally pancreatectomized dogs indefinitely by insulin. *Am. J. Physiol.* 67: 634-643, 1923-1924.
4. Brown, C. H.: Review of liver function in diabetic patients. *M. Rec.* 152: 332-334, 1940.
5. Best, C. H.; Hershey, J. M., and Huntsman, M. E.: Effect of lecithine on fat deposition in liver of normal rat. *J. Physiol.* 75: 56-66, 1932.
6. Chaikoff, I. L.; Entenman, C., and Montgomery, M. L.: Mechanism of action of antifatty liver factor of pancreas; comparison of hydrolyzed and unhydrolyzed casein in prevention of fatty livers of completely depancreatized dog maintained with insulin. *J. Biol. Chem.* 168: 177-181, 1947.
7. Chaikoff, I. L., and Soskin, S.: Utilization of acetoacetic acid by normal and diabetic dogs before and after evisceration. *Am. J. Physiol.* 87: 58-72, 1928-1929.

8. Best, C. H.; Hartroft, W. S., and Sellers, E. A.: Protection of liver by dietary factors. *Gastroenterology* 20: 375-384, 1952.
9. Hershey, J. M.: Substitution of lecithin for raw pancreas in diet of depancreatized dog. *Proc. Am. Physiological Soc. Am. J. Physiol.* 93: 657-658, 1930.
10. Hershey, J. M., and Soskin, S.: Substitution of "lecithin" for raw pancreas in diet of depancreatized dog. *Am. J. Physiol.* 98: 74-85, 1931.
11. Zilversmit, D. B.; Entenman, C., and Chaikoff, I. L.: Measurement of turnover of various phospholipides in liver and plasma of dog and its application to mechanism of action of choline. *J. Biol. Chem.* 176: 193-208, 1948.
12. Artom, C., and Cornatzer, W. E.: Action of choline and fat on lipide phosphorylation in liver. *J. Biol. Chem.* 171: 779-789, 1947.
13. Perlman, I.; Stillman, N., and Chaikoff, I. L.: Radioactive phosphorus as indicator of phospholipid metabolism. XI. Influence of methionine, cystine, and cysteine upon phospholipid turnover in liver. *J. Biol. Chem.* 133: 651-659, 1940.
14. Rossmiller, H. R.; Brown, C. H., and Whitman, J. F.: Needle biopsy of liver. *Cleveland Clin. Quart.* 17: 64-73, 1950.
15. Brown, C. H.: Biopsy of liver with Vim-Silverman needles. *Mississippi Valley M. J.* 81: 198-200, 1959.
16. Connor, C. L.: Etiology and pathogenesis of alcoholic cirrhosis of liver. *J. A. M. A.* 112: 387-390, 1939.
17. Morrison, L. M.: Evaluation of treatment for cirrhosis of liver. *Ann. West. Med. & Surg.* 2: 143-155, 1948.
18. Franklin, M.; Salk, M. R.; Steigmann, F., and Popper, H.: Clinical, functional and histologic responses of fatty metamorphosis of human liver to lipotropic therapy. *Am. J. Clin. Path.* 18: 273-282, 1948.
19. Beams, A. J., and Endicott, E. T.: Histologic changes in livers of patients with cirrhosis treated with methionine. *Gastroenterology* 9: 718-735, 1947.
20. Fagin, I. D.; Sahyun, M., and Pagel, R. W.: Cirrhosis of liver; lipotropic action of parenterally administered amino acids. *J. Lab. & Clin. Med.* 28: 987-993, 1943.
21. Cornatzer, W. E., and Cayer, D.: Effects of lipotropic factors on phospholipid turnover in plasma of patients with cirrhosis of liver, as indicated by radioactive phosphorus. *J. Clin. Invest.* 29: 542-551, 1950.
22. Cornatzer, W. E., and Cayer, D.: Effects of lipotropic factors on phospholipid turnover in plasma of normal persons as indicated by radioactive phosphorus. *J. Clin. Invest.* 29: 534-541, 1950.
23. Volwiler, W.; Jones, C. M., and Mallory, T. B.: Criteria for measurement of results of treatment in fatty cirrhosis. *Gastroenterology* 11: 164-182, 1948.
24. Buck, R. E.: Observations on alcoholic fatty liver; use of interval needle biopsy and liver function tests. *J. Lab. & Clin. Med.* 33: 555-564, 1948.

25. Klatskin, G., and Yesner, R.: Factors in treatment of Laennec's cirrhosis; clinical and histological changes observed during control period of bed-rest, alcohol withdrawal, and minimal basic diet. *J. Clin. Invest.* **28**: 723-735, 1949.
26. Eckhardt, R. D.; Zamcheck, N.; Sidman, R. L.; Gabuzda, G. J., Jr., and Davidson, C. S.: Effect of protein starvation and of protein feeding on clinical course, liver function, and liver histochemistry of three patients with active fatty alcoholic cirrhosis. *J. Clin. Invest.* **29**: 227-237, 1950.
27. Seife, M.; Kessler, B. J., and Lisa, J. R.: Clinical, functional and needle biopsy study of liver in alcoholism. *Arch. Int. Med.* **86**: 658-670, 1950.
28. Post, J.; Benton, J. G.; Breakstone, R., and Hoffman, J.: Effects of diet and choline on fatty infiltration of human liver. *Gastroenterology* **20**: 403-410, 1952.
29. Creutzfeldt, Von W., and Kühn, H. A.: Die Therapie der Leberzirrhose mit Glukocorticoiden. (Treatment of cirrhosis of liver with glucocorticoids.) *Deutsche med. Wchnschr.* **84**: 455-461, 1959.