

## CARDIAC DISEASE SECONDARY TO POSTNEPHRECTOMY ARTERIOVENOUS FISTULA

### Report of a Case

EARL K. SHIREY, M.D.

Department of Cardiovascular Disease

THE detection of peripheral arteriovenous fistulas should be early, and regardless of cause they should be repaired surgically although they rarely alter the hemodynamics of the central circulation. The diagnosis of this type of peripheral vascular defect usually is not difficult to establish, particularly when the symptoms and abnormal physical findings are localized to an extremity or to superficial areas in other parts of the body. A communication between a renal artery and a renal vein may not be so simple to identify.

Irrespective of the cause, a renal arteriovenous fistula may be present for many years before abnormal cardiac hemodynamic effects are produced or become clinically recognizable. On the other hand, cardiomegaly, congestive heart failure, or a cardiac arrhythmia may develop early if the extracardiac shunt is large. Symptoms and abnormal objective findings referable to the heart may also be attributed to primary cardiac disease, and may go unrecognized as a reversible and so-called "curable" type secondary to another correctible vascular lesion.

A case of a postnephrectomy arteriovenous fistula 17 years after nephrectomy is being reported to present briefly the clinical manifestations and hemodynamics and to emphasize the importance of a complete physical examination as a reliable diagnostic approach in the detection of the extracardiac shunt that should be recognized as an unusual but possible cause of heart disease. One unreported case of a postnephrectomy arteriovenous fistula without secondary cardiac effects has been seen at the Cleveland Clinic.

Scheifley, Daugherty, Greene, and Priestley<sup>1</sup> recently reviewed the literature on 12 reported cases of renal arteriovenous fistula and added three cases. The two cases of postnephrectomy arteriovenous fistulas reported by Schwartz, Borski, and Jahnki,<sup>2</sup> and Muller and Goodwin,<sup>3</sup> and the case reported by Hollingsworth<sup>4</sup> which was not definitely diagnosed were not included in the review because of the absence of hypertension and myocardial insufficiency which Scheifley and associates<sup>1</sup> reported to be the prominent features of a renal arteriovenous shunt with an intact kidney. In the case reported by Muller and Goodwin<sup>3</sup> the patient had severe heart failure, and the case herewith reported represents a predominantly heart problem with myocardial insufficiency and a cardiac arrhythmia. Thus, according to recent reviews of the literature, to date, there are two reported cases of postnephrectomy arteriovenous fistula and a total of 17 cases of renal arteriovenous communication.

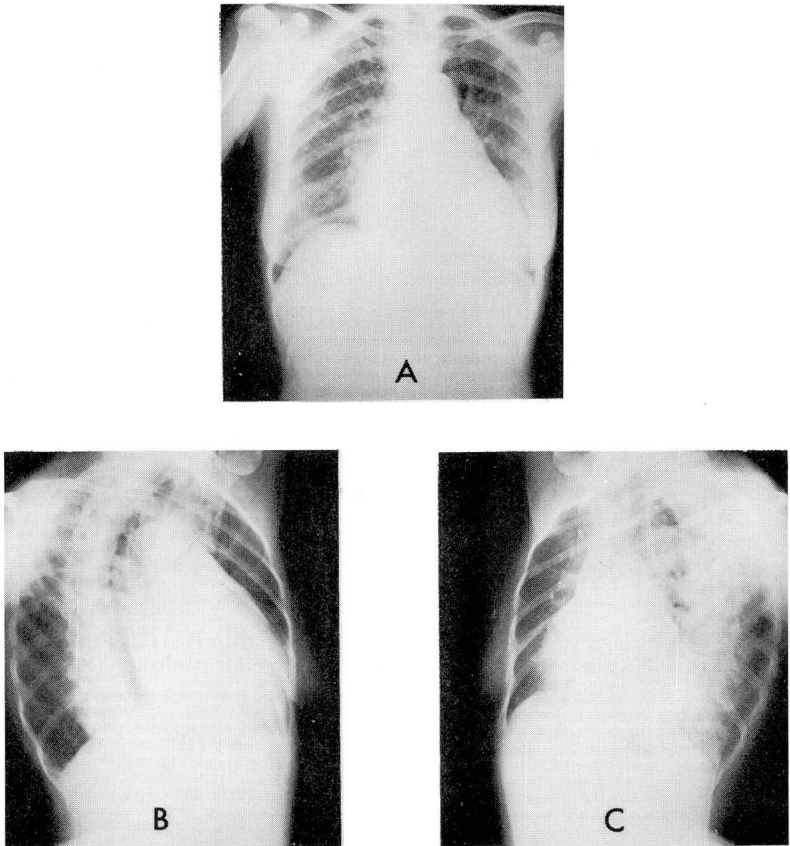
## Report of a Case

A 57-year-old white housewife was examined here in August, 1957, because of weakness and loss of weight which she attributed to digitalis that was prescribed by her physician five months previously for an irregular heartbeat. Approximately eight years previously another physician prescribed digitalis because of a "heart condition"; the drug was taken for only a short time and then was discontinued because of nausea and vomiting. For many years she experienced periods of weakness, fatigability, and dizziness that was attributed to labyrinthine vertigo. Palpitation occurred frequently, and about one month prior to examination here, swelling of the feet developed, which responded to the parenteral and oral administration of diuretics. There was no dyspnea, but she had voluntarily limited her activities because of fear of producing "further injury to the heart." There was no history of rheumatic fever, hypertension, or diabetes mellitus. The past history was otherwise unremarkable except for a right nephrectomy performed 17 years previously and a hysterectomy and an appendectomy performed, respectively, 12 years and 25 years previously.

*Physical examination.* The patient appeared to be chronically ill. She was apprehensive but not in acute distress. The temperature was 98 F. orally. The blood pressure was 140/70 mm. of Hg. The skin, eyes, ears, nose, and throat were normal. A fundoscopic examination demonstrated only grade I arteriosclerotic changes. The thyroid gland was of normal size, contour, and consistency. No abnormal lymph nodes were present. Examination of the chest revealed the lungs to be clear. The area of cardiac dullness was percussed 11 cm. from the midsternal line in the left fifth intercostal space. The heart rhythm was irregular with a ventricular rate of 120 beats per minute. A striking feature was the forceful heartbeat with a pronounced systolic thrust over the anterior left side of the chest. There was a grade III apical systolic murmur well transmitted over the precordium and to the left axilla. There was no diastolic murmur, gallop rhythm, pericardial friction rub or palpable thrill. The first heart sound at the apex was accentuated while the second sound was unremarkable. Examination of the abdomen elicited a faint thrill in the right upper quadrant in addition to a continuous machinery-like murmur in the same area. The intensity of the murmur was loudest in the right costophrenic angle and was accompanied by an easily palpable thrill. No masses were palpable and no hepatosplenomegaly was present. The abdominal aorta was of normal size and contour, and the peripheral pulses were equal, full, and synchronous. There were no congestive manifestations. Results of a pelvic examination were normal, and no abnormal musculoskeletal disorder was apparent. A neurologic survey was unremarkable.

*Laboratory studies* showed: hemoglobin content 13.5 gm. per 100 ml., red-cell count 4,860,000 per cu. mm., white-cell count 7,200 per cu. mm. with 54 per cent polymorphonuclear cells, 44 per cent lymphocytes, 1 per cent eosinophils and 1 per cent monocytes. Blood Wassermann and Kahn determinations were negative. Blood urea was 43 mg. per 100 ml. A urinalysis was negative except for 15 to 20 pus cells. Fasting and two and one-half hour postprandial blood sugar determinations were respectively 81 mg. and 83 mg. per 100 ml. Antistreptolysin titer was 20 units. A corrected sedimentation rate reading was 0.2 mm. per minute (Ernstene and Rourke method).

Fluoroscopy demonstrated the heart size to be 40 per cent above average. There was multichamber enlargement with increased amplitude of pulsations in the right and left ventricles. The aortic knob appeared slightly enlarged with calcification in the arch. No valvular or pericardial calcification was visualized. The vascular markings were increased but no hilar systolic intrinsic pulsations could be seen. Roentgenograms of the chest (*Fig. 1*) demonstrated essentially the same findings. The preoperative electrocardiogram (*Fig. 2*) showed atrial fibrillation, digitalis effect with QRS complexes in V5 and V6 consistent with left ventricular hypertrophy. A urogram demonstrated the absence of the right kidney, and a normal left kidney. An aortogram was made to define the arteriovenous communication (*Fig. 3*).



*Fig. 1.* Preoperative roentgenograms of the chest viewed in the (A) posteroanterior, (B) right anterior oblique, and (C) left anterior oblique projections. Note the small amount of calcification in the aortic knob. The transverse cardiac diameter was 16 cm.

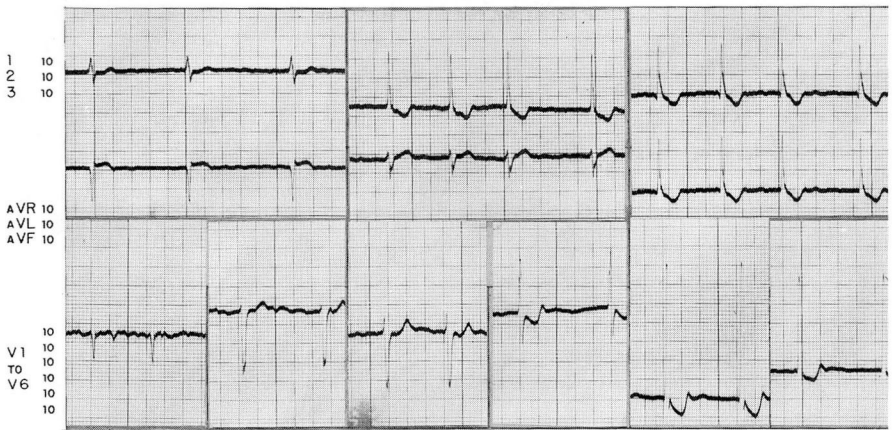


Fig. 2. Preoperative electrocardiogram showing atrial fibrillation, and digitalis effect with QRS complexes in V5 and V6 consistent with left ventricular hypertrophy.

The right renal artery was ligated and divided. The aneurysmal dilatation of the renal vein and the inferior vena cava (*Fig. 4*), discovered at surgery, collapsed along with disappearance of a palpable thrill during compression of the right renal artery. There was a slight increase in the ventricular rate at the same time, but there was no change in the basic rhythm. No record of the blood pressure was made immediately after obliteration of the arteriovenous communication, but for the first 12 hours after surgery, blood and levarterenol bitartrate\* was administered to raise and to maintain the systemic systolic pressure between 80 and 90 mm. of Hg. During this period the ventricular rate ranged between 110 and 160 beats per minute.

Two weeks after surgery, quinidine was administered and sinus rhythm was restored. At that time fluoroscopy and progress roentgenograms of the chest (*Fig. 5*) demonstrated a significant reduction in heart size and a decrease in the pulmonary vascular markings. The transverse cardiac diameter measured 14.0 cm., compared to 16.0 cm. preoperatively with only 25 per cent enlargement above average for her given height and weight according to the Ungerleider scale. Two months postoperatively the apical systolic murmur was of grade II intensity and the systolic thrust and accentuated first heart sound were absent. Further reduction in heart size had occurred and the transverse cardiac diameter was 13.6 cm. (*Fig. 6*). In addition, a remarkable change had occurred in the electrocardiogram (*Fig. 7*); there was sinus rhythm with no residual evidence of left ventricular hypertrophy.

The patient returned for another progress examination 14 months later (15 months postoperatively). During the interim, her functional status had improved despite numerous emotional problems that continued to curtail many activities. The objective findings, however, were striking. She had gained 20 pounds in weight and she appeared to be in excellent health. Results of the physical examination were entirely negative.

\*Levophed (levarterenol bitartrate), Wintthrop Laboratories.

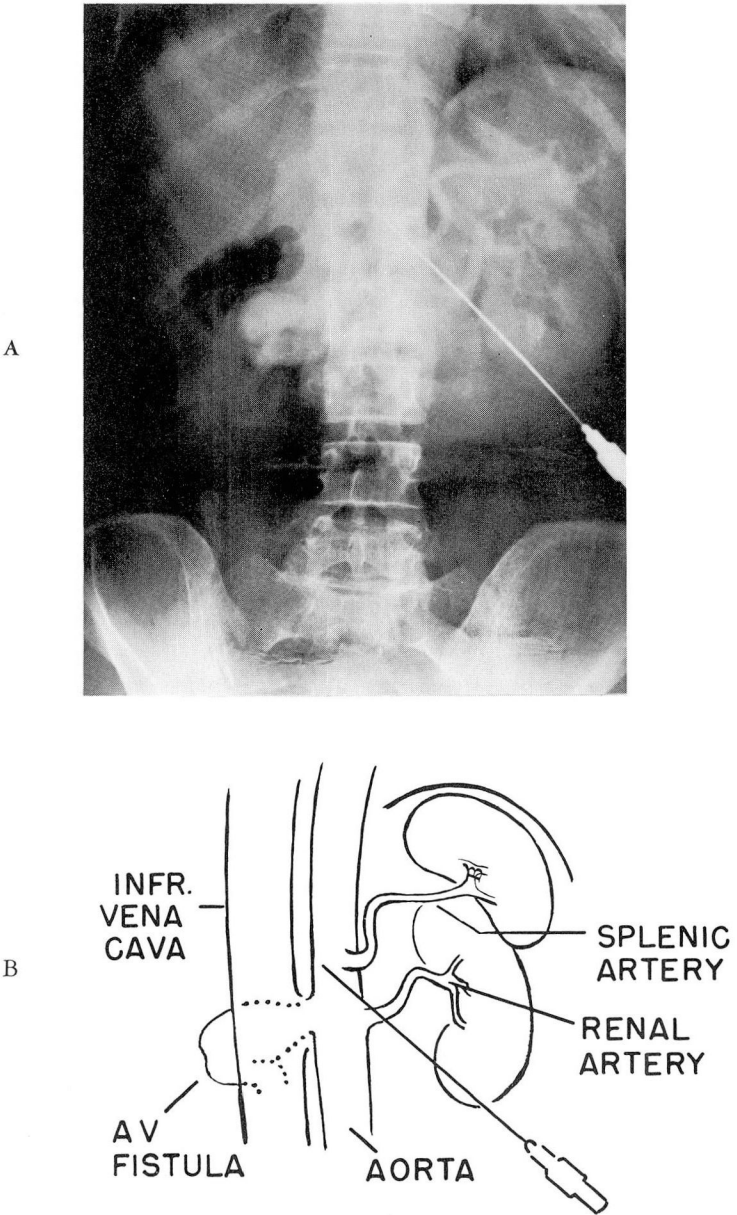


Fig. 3. A, Aortogram that demonstrates evidence of the right renal arteriovenous fistula. B, Diagram showing orientation.

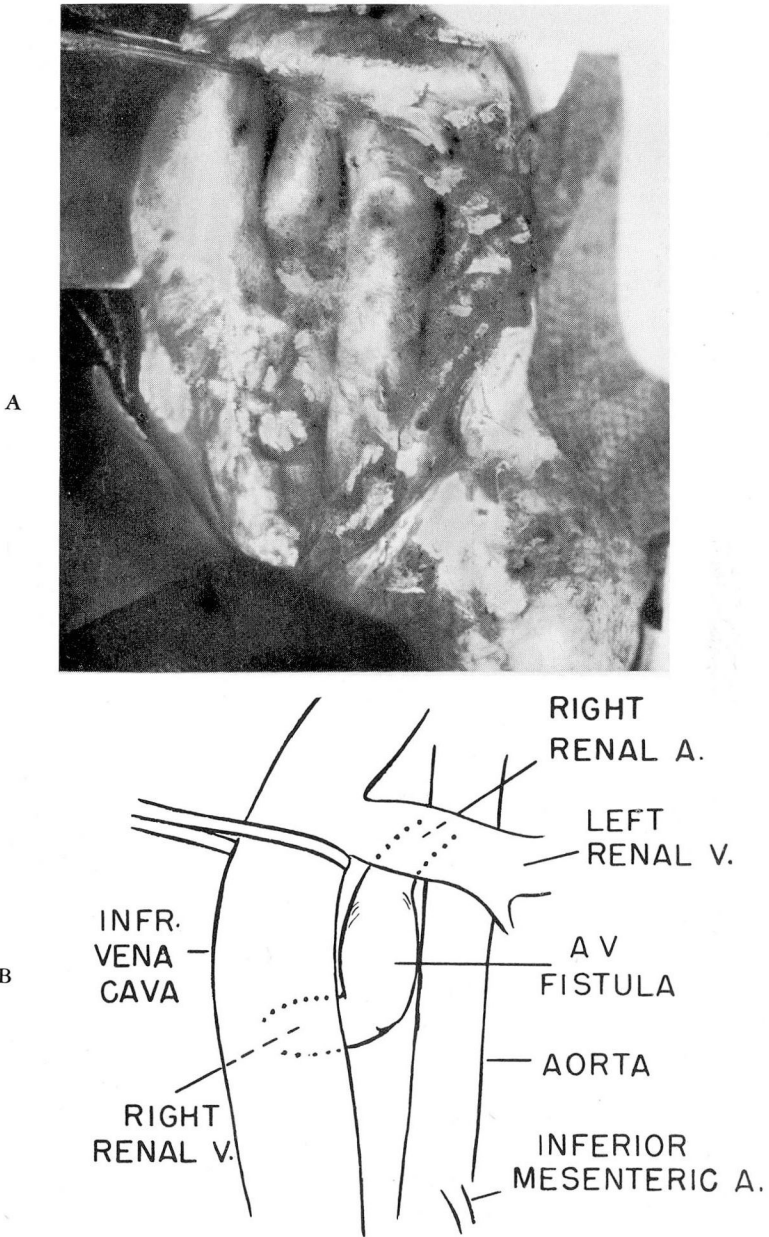
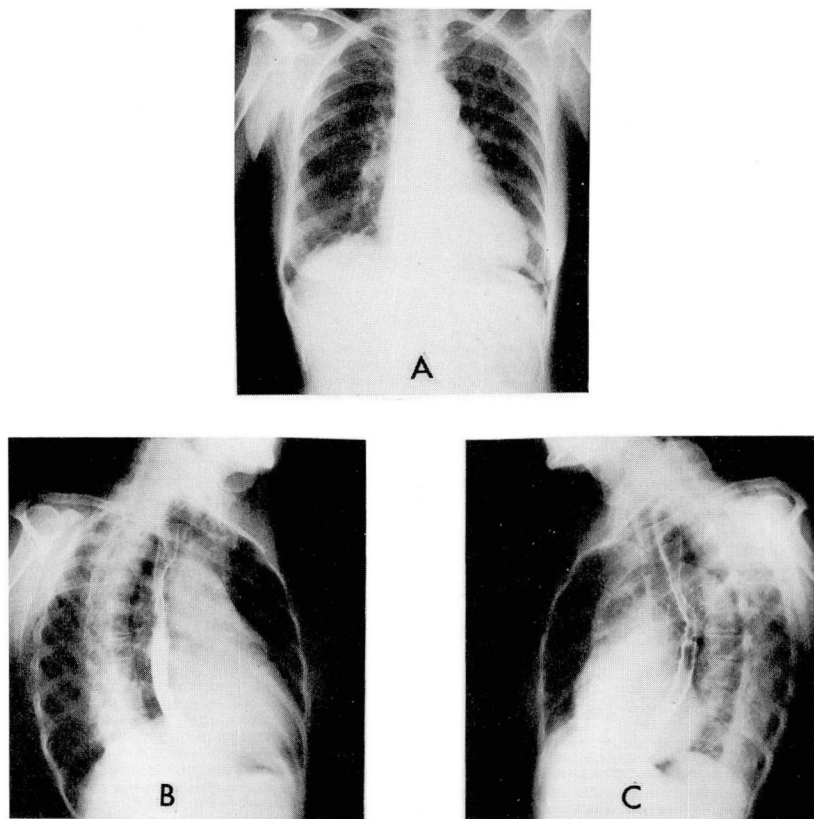


Fig. 4. A, Photograph of anatomic findings at the time of operation before the right renal artery was divided. Note the aneurysmal dilatation of the inferior vena cava. B, Diagram showing orientation.

Sinus rhythm had continued and a murmur was no longer audible. The heart size was average for her height and weight, according to the Ungerleider scale, with a configuration suggestive of minimal left ventricular enlargement (*Fig. 8*). A third electrocardiogram (*Fig. 9*) demonstrated sinus rhythm with no diagnostic changes. All of the findings were indicative of a normal heart and circulation. In comparison to the tracing in *Figure 7*, the amplitude of the R waves decreased appreciably in leads II, III, AVF, V4, V5, and V6.

#### Clinical Features

Despite the development of new and better roentgen equipment and improvement in laboratory diagnostic technics, a detailed history and a complex physical examination remain fundamental with nothing equivalent for the recognition of



**Fig. 5.** Roentgenograms of the chest two weeks after division of the renal artery. There is moderate left atrial and right-and-left ventricular chamber enlargement. The transverse cardiac diameter was 14 cm.

disease and, in many cases, the establishment of a correct diagnosis. For example, the examination of the heart alone can be misleading, because on the basis of abnormal auscultatory cardiac findings, the diagnosis of primary heart disease may be the only consideration. A general physical examination is mandatory in order to detect or to exclude disorders that secondarily affect cardiac function.

Because of the resultant increase in cardiac output produced by a renal arteriovenous fistula or any extracardiac shunt, cardiomegaly, a cardiac arrhythmia, heart murmur, and congestive manifestations can develop. High output failure results in these cases and always should be considered in a patient who has symptoms and objective evidence of congestive manifestations. Fluoroscopy of the chest can be helpful in recognizing an increase in cardiac output. Cardiomegaly,

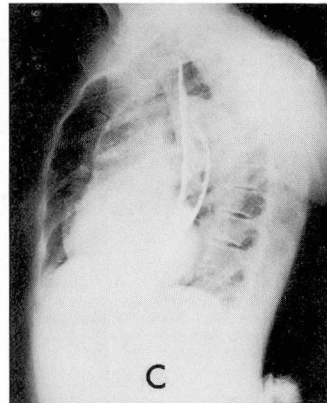
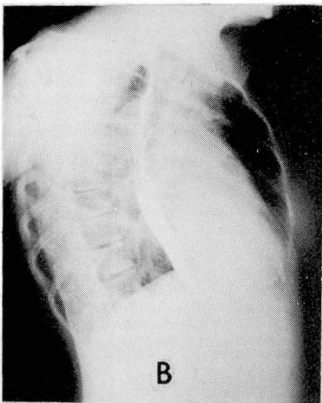
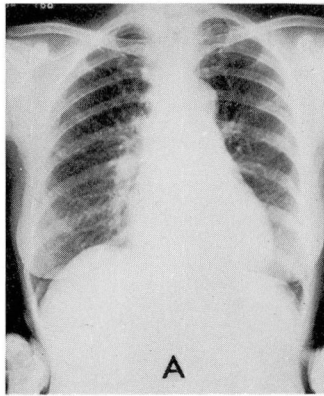


Fig. 6. Roentgenograms two months postoperatively. The transverse cardiac diameter was 13.6 cm.



right ventricular enlargement, increased amplitude of chamber pulsations along with an extremely "hyperkinetic heart" and occasionally multichamber enlargement are the characteristic features. A cardiac arrhythmia, enlargement, and hypertrophy of the ventricular chambers may also be demonstrated by the electrocardiogram.

The murmur of an arteriovenous fistula should be easily recognized. It has been clearly described by Edwards and Levine.<sup>5</sup> The murmur is continuous with a systolic accentuation. In the presence of only a systolic murmur, the possibility of an obstruction of the effluent vein, partial occlusion of the artery resulting in a significant reduction in the arteriovenous gradient, or an arterial aneurysm should be considered.

### Pathologic Physiology

Although peripheral and postnephrectomy arteriovenous fistulas do not produce hypertension, myocardial insufficiency can result if the shunt is of significant magnitude to impose a burden on the myocardium. Although the systemic hypertension associated with a renal arteriovenous fistula with an intact kidney is partially responsible for the development of cardiac enlargement and failure, the size of the artery-and-vein communication and the length of time the fistula has been present are also major factors. For example, the development of congestive heart failure as late as 57 years after the establishment of a peripheral fistula has been reported by Dorney.<sup>6</sup> Muller and Goodwin<sup>3</sup> reported a patient having an arteriovenous fistula with the development of congestive heart failure 29 years after a nephrectomy.

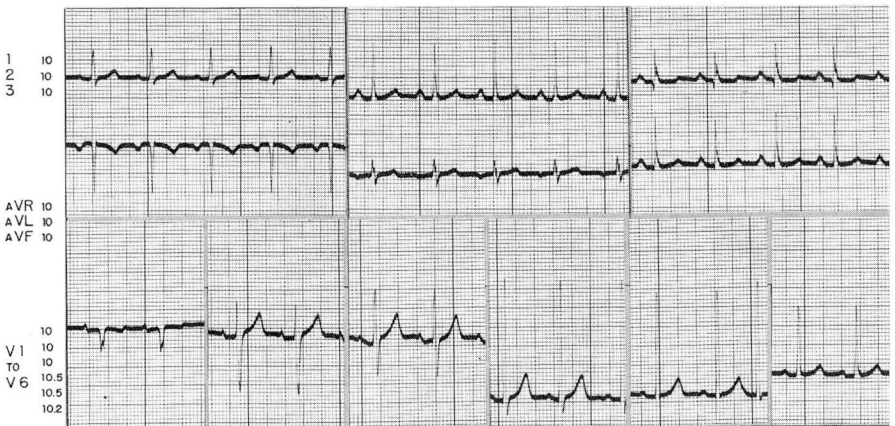


Fig. 7. Electrocardiogram two months postoperatively showing sinus rhythm with no evidence of left ventricular hypertrophy.

The physiology of an arteriovenous fistula has been thoroughly studied by Holman.<sup>7</sup> The pressure gradient between a systemic artery and vein which produces a significant left-to-right shunt results in reduced peripheral resistance and, as a compensatory mechanism, cardiac output increases. The increased volume and velocity of flow to the right side of the heart lead to increased heart work, cardiac dilatation, and ultimately cardiac hypertrophy. Congestive heart failure that may subsequently develop may be indistinguishable clinically from congestive manifestations due to primary valvular or myocardial disease, but physiologic studies have found the cardiac output to be decreased and the peripheral resistance to be increased in myocardial failure.

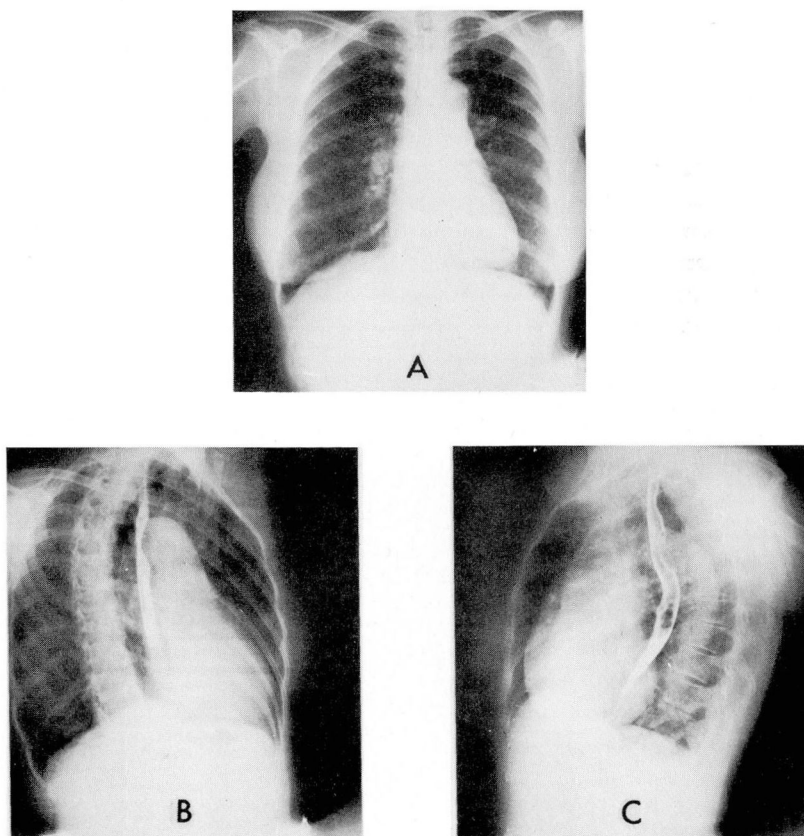


Fig. 8. Progress roentgenograms of the chest 15 months postoperatively. The transverse cardiac diameter was 12 cm.

Youmans's<sup>8</sup> studies on the circulatory effects of closing an arteriovenous fistula showed that there is an immediate elevation of the systemic blood pressure with a concomitant decrease in the pulse rate and the cardiac output. The decrease in the blood pressure and the increase in the heart rate in the case reported here were attributed to loss of blood and to atrial fibrillation.

### Diagnostic Features

With or without cardiac symptoms, a patient demonstrating cardiac enlargement without obvious cause and with a history of an injury or of surgery, should be carefully examined for an arteriovenous fistula. Good standard procedure is to perform auscultation over any area of scar tissue to detect a possible arteriovenous fistula. Fourteen<sup>1-3,9-15</sup> of the 17 cases that have been reported in addition to this case manifested a bruit, and the diagnosis of a renal arteriovenous fistula was established or at least suspected at the time of the physical examination. In two cases,<sup>1,16</sup> the diagnosis was made at the time of surgery. The auscultatory features of a systemic artery-and-vein communication have been discussed. It is fair to assume that in most instances, a careful physical examination is sufficient to detect this vascular defect.

An attempt must always be made to determine whether cardiac enlargement, a cardiac arrhythmia or congestive manifestations are on the basis of primary or secondary cardiac disease.

A careful and complete physical examination is essential for the detection of an extracardiac shunt. Fluoroscopy can be helpful in the recognition of cardiomegaly and increased amplitude of the ventricular pulsations indicative of an increase in cardiac output. Careful observation of the hilar vessels for intrinsic systolic pulsations (hilar dance) is also important in establishing the presence or

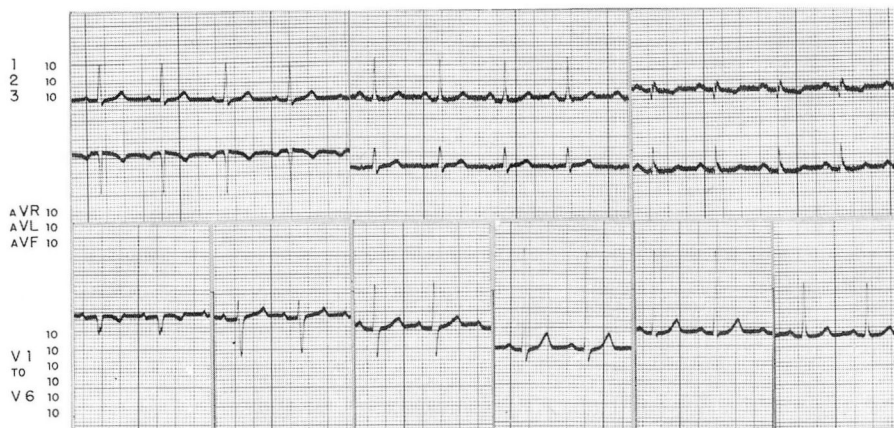

Fig. 9. Electrocardiogram 15 months postoperatively showing no diagnostic changes.

absence of a shunt in the central circulation. With the clinical manifestations of an increased cardiac output, hyperthyroidism, anemia, beriberi heart disease, Paget's disease and an intracardiac shunt as mentioned should be considered in the differential diagnosis. The pertinent clinical features of these various conditions will not be discussed at this time but a complete physical examination, fluoroscopy of the chest and a few laboratory studies will usually suffice to distinguish the various disorders.

Early recognition of an arteriovenous fistula, and immediate surgical excision of the vascular defect will prevent the development of gradual and progressive cardiac deterioration; whereas, delay in recognition and treatment may produce only partial reversibility in heart size and hemodynamics of the central circulation. Reid<sup>17</sup> has said: "It is too true that we often fail to appraise properly chronic affections which, while life lasts, are no serious handicap to the individual. . . . It is in such a manner that most abnormal arteriovenous communications must be considered, for they are usually chronic affections, often worrying little, but often subtracting days from the end of one's life."

#### Summary

Renal arteriovenous fistulas occur rarely; according to recent reviews only 17 cases have been previously reported. Two of the fistulas followed nephrectomy. Another postnephrectomy arteriovenous fistula is reported, which increases the totals to 18 and to 3 cases, respectively. The importance of a detailed history, a careful physical examination, and fluoroscopy of the chest is stressed as a reliable diagnostic approach in the recognition of an extracardiac shunt and its effect on the central circulation. Some clinical and diagnostic features are discussed and mention is made of other conditions that need to be considered in the differential diagnosis. The pathologic physiology of an arteriovenous fistula is briefly discussed. The importance is emphasized of recognizing abnormal cardiac findings secondary to a renal arteriovenous shunt which represents a curable form of heart disease after excision of the vascular defect.

#### References

1. Scheifley, C. H.; Daugherty, G. W.; Greene, L. F., and Priestley, J. T.: Arteriovenous fistula of kidney; new observations and report of three cases. *Circulation* 19: 662-671, 1959.
2. Schwartz, J. W.; Borski, A. A., and Jahnki, E. J.: Renal arteriovenous fistula. *Surgery* 37: 951-954, 1955.
3. Muller, W. H., Jr., and Goodwin, W. E.: Renal arteriovenous fistula following nephrectomy. *Ann. Surg.* 144: 240-244, 1956.
4. Hollingsworth, E. W.: Arteriovenous fistula of renal vessels. *Am. J. M. Sc.* 188: 399-403, 1934.
5. Edwards, E. A., and Levine, H.D.: Murmur of peripheral arteriovenous fistula. *New England J. Med.* 247: 502-505, 1952.

6. Dorney, E. R.: Peripheral A-V fistula of fifty-seven years' duration with refractory heart failure. *Am. Heart J.* 54: 778-781, 1957.
7. Holman, E. F.: Physiology of arteriovenous fistula. *Arch. Surg.* 7: 64-82, 1923.
8. Youmans, W. B.: Mechanism of high output circulatory failure. *Ann. Int. Med.* 41: 747-756, 1954.
9. Bohne, A. W., and Henderson, G. L.: Intrarenal arteriovenous aneurysm; case report. *J. Urol.* 77: 818-820, 1957.
10. Slominski-Laws, M. D.; Kiefer, J. H., and Vermeulen, C. W.: Arteriovenous aneurysm of kidney; case report. *J. Urol.* 75: 586-591, 1956.
11. Hamilton, G. R.; Getz, R. J., and Jerome, S.: Arteriovenous fistula of renal vessels: case report and review of literature. *J. Urol.* 69: 203-207, 1953.
12. Kirby, C. K., and others: Arteriovenous fistula of renal vessels; case report. *Surgery* 37: 267-271, 1955.
13. Myhre, J. R.: Arteriovenous fistula of renal vessels; case report. *Circulation* 14: 185-187, 1956.
14. Baron, G. J., and Koeneemann, R. H.: Arteriovenous fistula of renal vessels; case report. *Radiology* 64: 85-87, 1955.
15. Adams, H. D.: Congenital arteriovenous and cirroid aneurysms. *Surg. Gynec. & Obst.* 92: 693-697, 1951.
16. Pearse, R., and MacMillan, R. L.: Congenital arteriovenous aneurysm of renal artery. *J. Urol.* 58: 235-238, 1947.
17. Reid, M. R.: Abnormal arteriovenous communications, acquired and congenital. IV. Treatment of abnormal arteriovenous communications. *Arch. Surg.* 11: 237-253, 1925.