

# Cleveland Clinic Quarterly

Volume 27

JULY 1960

No. 3

## HYPOGASTRIC ARTERIOGRAPHY PRIOR TO CONTINUOUS INFUSION OF MALIGNANT TUMORS OF THE UTERINE CERVIX AND VAGINA

### A Preliminary Report

PAUL R. ZEIT, M.D.,  
*Department of Obstetrics and Gynecology*

C. ROBERT HUGHES, M.D.,  
*Department of Radiology*

JOHN J. CAHILL, M.D.,\* and J. GREGORY HAMILTON, M.D.\*  
*Department of Obstetrics and Gynecology*

RECENTLY, Sullivan, Miller, and Sikes<sup>1</sup> reported the treatment of advanced squamous-cell carcinoma of the mouth and the nasopharynx by continuous intraarterial infusion with amethopterin. In several of their patients regression of the tumor was so striking that an attempt to adapt their technics and methods to the treatment of squamous-cell carcinoma of the uterine cervix and the vagina was undertaken here at the Cleveland Clinic. The project has been in progress since December, 1959, and this preliminary report is concerned with the visualization of the vascular anatomy of the uterus and of the upper vagina in nine patients.

For maximum benefit from infusion of malignant tumors in any location, the following four requirements must be met: (1) the one or two arteries selected for infusion must deliver most of their blood to the region of the tumor; (2) most of the blood supply of the tumor itself must come from these arteries; (3)

\*Fellow in the Department of Obstetrics and Gynecology.

the vessels must be accessible and of adequate size to be catheterized easily; (4) the sacrifice of the arteries must be possible, if necessary, without serious damage to normal tissues. For infusion of carcinoma of the uterus, cervix, and upper vagina, these four requirements are fulfilled by employing the hypogastric arteries. Sullivan and Miller<sup>2</sup> have used these arteries for the infusion of tumors of the bladder in two male patients. It is logical that the hypogastric arteries be used in female patients for treatment of carcinoma of the cervix and of the vagina.

We have followed a strict policy of performing arteriography at the time of laparotomy on every patient who is to receive hypogastric arterial infusion. From the arteriogram, information is obtained concerning the accuracy of placement of the catheter in the artery, and an accurate estimation is possible of the amount of the drug that will reach the region of the tumor. We have observed no undesirable side effects from the contrast medium in any of our patients, nor any complications from the procedure of arteriography.

### Anatomy of the Hypogastric Arteries

The many variations of the hypogastric arteries have been noted by anatomists and surgeons for many years. A classic description and tabulation of the variations was given by Lipshutz<sup>3</sup> in 1918, and this has been confirmed and enlarged upon by many others, among whom are Quimby,<sup>4</sup> and Shafiroff, Grillo, and Baron.<sup>5</sup> In general, the arterial branches are anatomically classified as parietal and visceral groups, and it is the visceral group that is used in the chemotherapy of carcinoma of the cervix and of the vagina.

*Figure 1* shows an arteriogram of a normal right hypogastric artery in an adult female. It demonstrates the division of the artery, soon after its origin, into an anterior and a posterior trunk. This early division is an almost constant feature of the artery, but there is individual variation in the branches derived from each trunk. The superior gluteal artery always arises from the posterior trunk, and in the arteriogram shown it is the only major branch (C) of this trunk; this is considered the most common arrangement.<sup>5</sup> A second frequent pattern is that demonstrated in *Figure 2*, where both the superior and the inferior gluteal arteries arise from the posterior trunk. The left posterior trunk has been ligated so that neither gluteal artery contains contrast medium. A catheter lies in the right posterior trunk, and on this side the gluteal arteries are the only arteries shown (A and B).

In six of the nine patients the more common anatomic arrangement was found, wherein the superior gluteal artery arose from the posterior trunk of the hypogastric artery, and the inferior gluteal artery arose separately from the hypogastric artery. In these patients the posterior trunk and the inferior gluteal artery had to be ligated separately, to divert to the visceral branches most of the blood flow in the hypogastric artery. In the remaining three patients the posterior trunks gave rise to both the superior and inferior gluteal arteries; in each of these patients

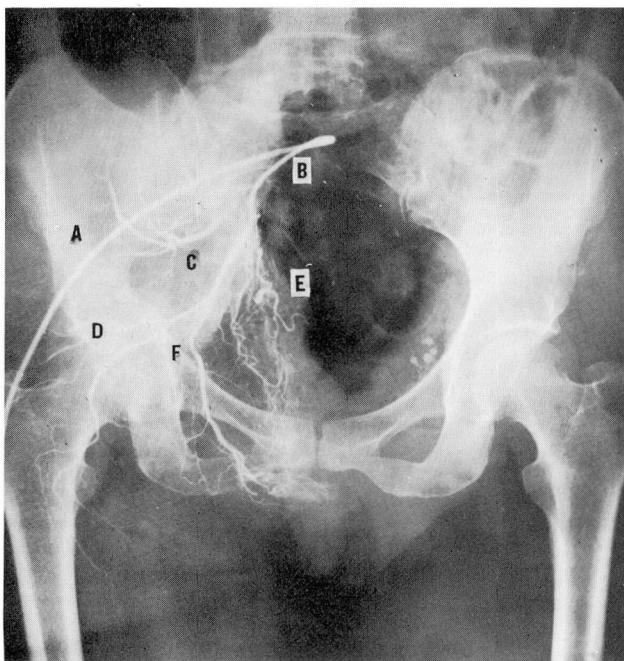


Fig. 1. Right hypogastric arteriogram showing the most common variant of the hypogastric artery in an adult female: A, Catheter leading into hypogastric artery near its origin. B, Hypogastric artery before its bifurcation. C, Superior gluteal artery, which in this patient is the only branch of the posterior trunk. D, Inferior gluteal artery. E, Uterine artery. F, Internal pudendal artery.

only one ligature was needed. Thus, ligation of the posterior trunk prevents flow of the infusate into the superior gluteal artery in almost every instance, and into the inferior gluteal artery, as well, in many patients. Elimination of blood flow in these two vessels directs almost all of the flow toward the uterus, cervix, and vagina, through the uterine and the internal pudendal arteries (*Figs. 2 and 3*). In *Figure 3* can be seen an ideal distribution of flow for infusion of tumors of the cervix and the vagina, which meets the first requirement in effective infusions.

The second requirement for effective infusions is that most of the blood supply of the tumor be derived from the arteries that are to be infused. The uterus and the cervix receive their blood supply from the uterine and ovarian arteries; the vagina is supplied by the vaginal, the middle hemorrhoidal, and the internal pudendal arteries, all of which are branches of the hypogastric arteries.

The size and accessibility of the hypogastric arteries are well known to all pelvic surgeons. The hypogastric arteries can be easily exposed with a minimum of dissection during the exploratory laparotomy that always should be performed to determine the extent and the distribution of the neoplastic tissue. Both hypo-

gastric arteries can be ligated at their origins without damage to the rectum, anus, bladder, or perineum.<sup>4-8</sup> It has been our experience that ligation of both hypogastric arteries and both ovarian arteries produces no ill effects.

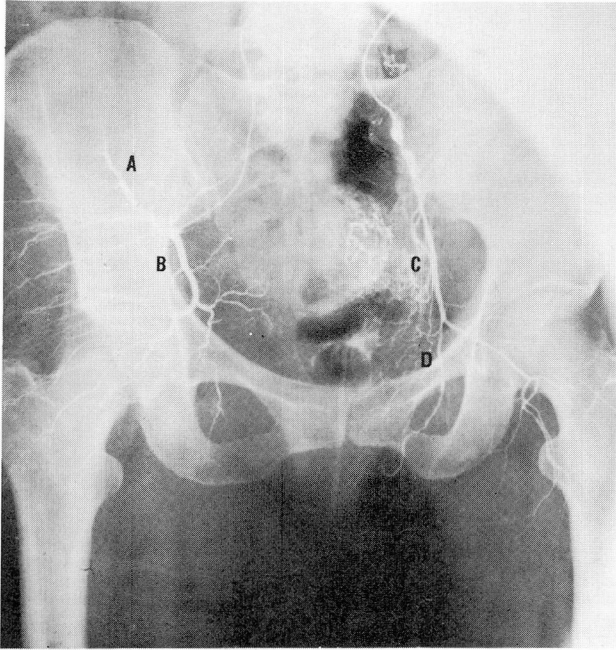


Fig. 2. Bilateral arteriogram showing the second most common variant of the hypogastric artery in an adult female. The superior and inferior gluteal arteries both arise from the posterior trunk. On the patient's right only the posterior trunk and its branches are filled with contrast medium. On her left only the anterior trunk and its branches are visualized. A, Superior gluteal artery (right). B, Inferior gluteal artery (right). C, Uterine artery (left). D, Internal pudendal artery (left).

### Technic of Arteriography

A hypogastric artery is exposed by reflecting the peritoneum. First the posterior trunk is ligated with a silk ligature as close to its origin as possible. This is done before the catheter is threaded into the vessel, because the posterior trunk lies in almost a direct line with the first part of the hypogastric artery, and the catheter will usually thread into the posterior trunk. Two bulldog clamps are placed on the artery, one clamp near its origin from the common iliac artery, and the other clamp well down on the anterior trunk. Between the two clamps a No. 18 needle is inserted through the wall of the vessel, and through the lumen of this needle a fine polyethylene catheter is threaded. The needle is withdrawn over the catheter, and the bulldog clamps are released. Catheterization is an almost



bloodless procedure; the elasticity of the vascular wall is usually sufficient to prevent leakage around the catheter. From 7 to 8 ml. of Hypaque Sodium 50%\* is injected rapidly through the catheter, and as the injection is completed the roentgen film is exposed.

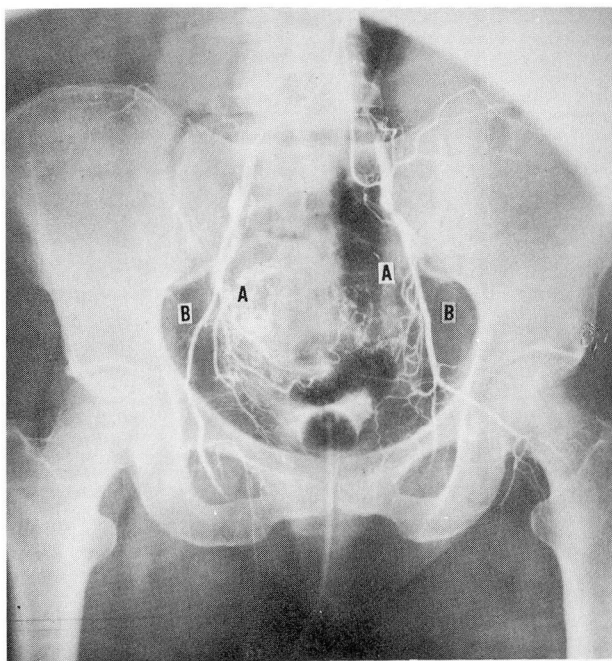


Fig. 3. Bilateral arteriogram (same patient as *Figure 2*) after both posterior trunks were ligated. The elimination of the gluteal arteries from the hypogastric circulation has directed most of the flow to the region of the uterus, cervix, and vagina. Note also the evidence of the concentration of contrast medium in the region of the bladder. A, Uterine artery. B, Internal pudendal artery.

### Summary

Four anatomic requirements for a technically successful continuous infusion of a malignant tumor in any part of the body are: (1) the one or two arteries selected for infusion must deliver most of their blood to the region of the tumor; (2) most of the blood supply of the tumor itself must come from these arteries; (3) the vessels must be accessible and of adequate size to be catheterized easily; (4) sacrifice of the arteries must be possible, if necessary, without serious damage to normal tissues.

The anatomic arrangement of the hypogastric arteries in the human female, as demonstrated by arteriograms, is such that the above four requirements can be fulfilled for infusion of malignant tumors of the uterine cervix and vagina.

\*Winthrop Laboratories.

Ligation of the superior and inferior gluteal arteries diverts most of the blood flow in the hypogastric artery to the uterine, internal pudendal, middle hemorrhoidal, and vaginal arteries.

The technic of hypogastric arteriography has been briefly described. In the nine patients reported by the authors there were no undesirable effects or complications arising from the procedure.

#### References

1. Sullivan, R. D.; Miller, E., and Sikes, M. P.: Antimetabolite-metabolite combination cancer chemotherapy. Effects of intraarterial Methotrexate-intramuscular citrovorum factor therapy in human cancer. *Cancer* 12: 1248-1262, 1959.
2. Sullivan, R. D., and Miller, E.: Personal communication, May 12, 1960.
3. Lipshutz, B.: Composite study of hypogastric artery and its branches. *Ann. Surg.* 67: 584, 1918.
4. Quimby, W. C., Jr.: The Anatomy and Blood Vessels of the Pelvis, Chap. 1, pp. 26-64, in *Surgical Treatment of Cancer of the Cervix*, edited by J. V. Meigs. New York: Grune & Stratton, Inc., 1954, 453 pp.
5. Shafiroff, B. G. P.; Grillo, E. B., and Baron, H.: Bilateral ligation of hypogastric arteries. *Am. J. Surg.* 98: 34-40, 1959.
6. Daro, A. F.; Nora, E. G., Jr.; Gollin, H. A., and Howell, R. E.: Artery ligation in bleeding cervical cancer. *Am. J. Obst. & Gynec.* 78: 197-199, 1959.
7. Decker, W. H.: Ligation of hypogastric artery in postoperative uterine artery hemorrhage; report of case. *Obst. & Gynec.* 5: 109-110, 1955.
8. Hecht, E. L., and Blumenthal, E. D.: Recurrent bleeding from vaginal vault following total abdominal hysterectomy. *Am. J. Obst. & Gynec.* 67: 195-197, 1954.