

R-WAVE VOLTAGE CHANGES IN RELATION TO ARTERIAL PRESSURE IN HYPERTENSIVE PATIENTS

ATHAN J. GEORGOPOULOS, M.D.,* PHILIP A. VLASTARIS, M.D.,†

and

WILLIAM L. PROUDFIT, M.D.

Department of Cardiovascular Disease

HIGH voltage of R waves in left precordial leads of the electrocardiogram has been proposed as a sign of left ventricular hypertrophy.^{1,2} A high incidence of abnormally large R waves in V_5 has been reported in hypertensive patients with high diastolic arterial pressure.³ A rise in blood pressure following infusion of *l*-norepinephrine in normotensive subjects,⁴ and ligation of the aorta in animals,⁵ has resulted in an increase in the amplitude of the R waves. Considerable reduction in the voltage of R waves has been observed following satisfactory treatment of hypertension with methonium compounds⁶ and other antihypertensive agents.⁷ These observations suggest that elevated arterial pressure may be an important factor in influencing the amplitude of R waves, but this relationship has not been adequately investigated.

The present study determines the possible effects that the lowering of arterial pressure exerts on the amplitude of R waves in left precordial leads of hypertensive patients whose electrocardiograms show evidence that meets the criteria for left ventricular hypertrophy as defined by Sokolow and Lyon.¹

Methods and Material

Twenty hypertensive patients whose electrocardiograms showed increased voltages of R and S waves in leads V_5 and V_1 , respectively, were studied at the Cleveland Clinic Hospital. All the patients had a mild to moderately severe hypertension that was benign in 13 patients, malignant in 1 patient, and associated with renal arterial lesions in 6 patients. Evidence of mild cardiac enlargement with some prominence of the left ventricle was present in the roentgenograms of 9 patients, whereas in those of 11 patients the cardiac size and configuration were normal.

By using the criteria of Sokolow and Lyon,¹ namely, the sum of voltages of R waves in V_5 and S waves in V_1 as greater than 35 mm., left ventricular hypertrophy could have been diagnosed in all the cases. The amplitude of R waves in V_5 or V_6 ranged from 19 to 40 mm., the mean value being 26.5 mm. Intraventricular conduction defect was not evident in any patient.

*Formerly Fellow; present address: 54 Herman Street, Salonika, Greece.

†Formerly Fellow; present address: Athens, Greece.

Arterial pressure was lowered in all 20 patients by intravenous infusion of sodium nitroprusside administered according to the recommendations of Page, Corcoran, Dustan, and Koppanyi.⁸ Arterial pressure was measured with a sphygmomanometer before the infusion of sodium nitroprusside and every 30 seconds thereafter. The arterial pressure was kept at various desired levels until electrocardiographic records were obtained. Control electrocardiograms were recorded for each patient, that is, six standard limb leads and six precordial leads, V_1 through V_6 . Thereafter, during the infusion of sodium nitroprusside, only the precordial leads V_1 and V_5 or V_6 were recorded in 15 patients, and complete electrocardiograms of five patients at various desired levels of arterial pressure.

Results

In 19 of the 20 patients, lowering of arterial pressure with sodium nitroprusside resulted in a decrease of the amplitude of R waves in lead V_5 . The reduction ranged from 3 to 19 mm., or from 14 to 49 per cent of the control values. In the one patient, no changes occurred. The average control amplitude of R waves in V_5 for all the patients was 26.5 mm. Following intravenous administration of sodium nitroprusside, this average amplitude was reduced to 18.9 mm., or 71.3 per cent of the control values. Reduction of the amplitude of the R waves was approximately proportional to the decrease in arterial pressure until low normotensive levels were achieved; further lowering of arterial pressure to hypotensive levels did not result in further reduction in the voltages of the R waves.

Changes in the voltages of S waves in V_1 or V_2 were not consistent. In one half of the patients an increase occurred, ranging from 1 to 6 mm., the mean increase being 11 per cent of the control values. In the other half the voltages were reduced from 1 to 8 mm., the mean reduction being 13.9 per cent of the control values. The sums of R waves in V_5 and S waves in V_1 were reduced in

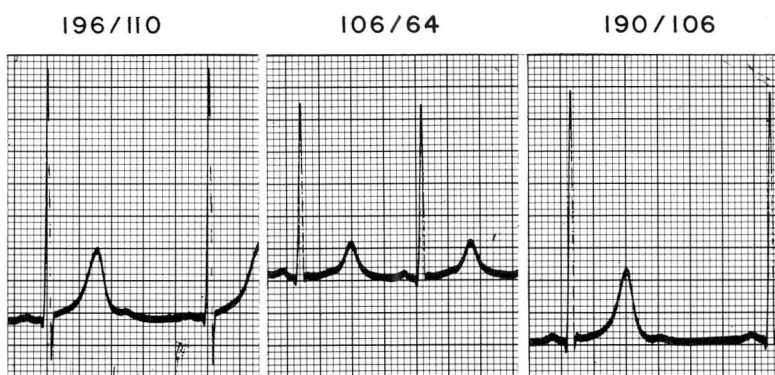

Fig. 1. Electrocardiograms (V_5) showing decreases in voltage of the R wave during normotensive period (after administration of sodium nitroprusside), and increases in voltage after hypertension returns, following termination of sodium nitroprusside administration.

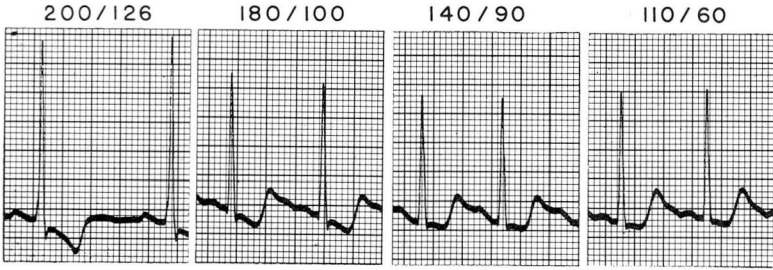


Fig. 2. Electrocardiograms (V_5) showing changes in R waves, S-T segments, and T waves during progressive lowering of blood pressure by administration of sodium nitroprusside.

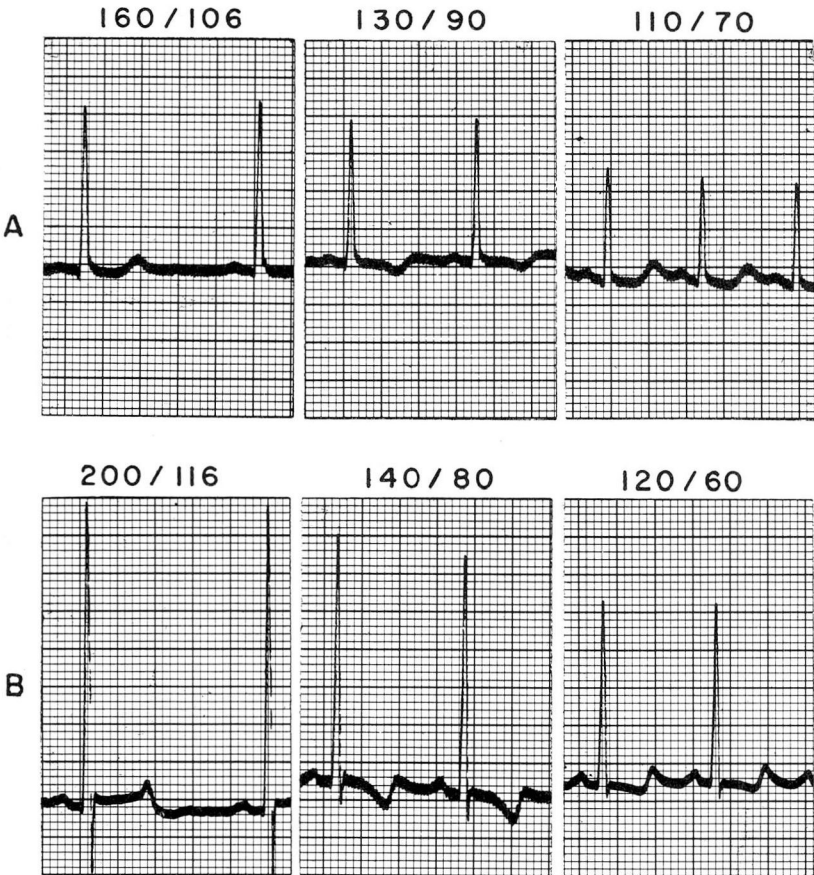


Fig. 3A and B. Electrocardiograms (V_5) showing R-wave and T-wave changes in two patients during lowering of blood pressure; inversion of previously upright T waves in records taken at blood pressure levels intermediate between control and normotensive periods.

all the patients when the arterial pressure was lowered to normotensive levels; the reduction ranged from 4 to 21 mm., the mean reduction being 15.6 per cent of the control values.

Complete electrocardiograms were recorded before and during infusion of sodium nitroprusside in five patients; the electric axis of the heart changed from horizontal to semivertical in three and to vertical in two patients.

The intrinsicoid deflection in left precordial leads was not affected. The changes of S-T segments and T waves in V_5 or V_6 (Fig. 1) were not significant in 15 patients. Of the other five patients, in one patient the S-T segments became less depressed, following progressive lowering of arterial pressure, and the T waves changed from inverted to predominantly upright (Fig. 2); in one patient the upright T wave became diphasic; in the other three patients, moderate reduction of arterial pressure resulted in inversion of the previously upright T waves, but further lowering of blood pressure was accompanied by diphasic or upright T waves (Fig. 3).

Discussion

Increased voltage of R waves in left precordial leads has been ascribed to an increased mass of left ventricular musculature^{2,9} and has been proposed as a sign of left ventricular hypertrophy.^{1,2} Although Doyle⁶ observed a reduction in amplitude of R waves in hypertensive patients following treatment with hexamethonium compound, and suggested that this decrease was not necessarily due to involution of the hypertrophied muscle following control of hypertension, he concluded that this mechanism was the most probable explanation.

The results of the present study indicate that, in hypertensive patients, acute lowering of arterial pressure to low normal levels results in significant decreases in the voltages of R waves in V_5 and V_6 , the decreases being approximately proportional to the degree of decrease in arterial pressure. When further decreases of arterial pressure from normotensive to hypotensive levels were achieved, further reduction of the voltages of R waves did not occur.

Since lowering of arterial pressure following long-term antihypertensive treatment has also resulted in reduction of the amplitude of R waves,^{6,7} we believe that, because of its variability with the level of arterial pressure, the height of R waves in left precordial leads of hypertensive patients is not a valid sign of anatomic left ventricular hypertrophy. Similarly, although less variable, the summation of R waves in V_5 and of S waves in V_1 does not represent a reliable criterion for left ventricular hypertrophy in hypertensive patients. It seems that the voltages of S waves in V_1 or V_2 remain more or less stable and do not vary with the arterial pressure.

The mechanism by which lowering of arterial pressure results in reduction of voltage of R waves is not clear. The suggested factors influencing the height of R waves are the thickness of the left ventricle,⁹ the direction of spread of depolar-

ization,¹⁰ the distance of the exploring electrode from the surface of the heart,¹¹ and the stroke volume.¹² These factors, however, do not seem to explain the results of this study. The observed changes in the electric position of the heart also do not account for the reductions in R-wave voltages.

Summary

Reducing the arterial pressures with sodium nitroprusside in hypertensive patients was accompanied by significant decreases in R-wave voltages in left precordial leads. This effect should lead to caution in attributing high R-wave voltages to anatomic left ventricular hypertrophy in hypertensive patients.

References

1. Sokolow, M., and Lyon, T. P.: Ventricular complex in left ventricular hypertrophy as obtained by unipolar precordial and limb leads. *Am. Heart J.* 37: 161-186, 1949.
2. Gubner, R., and Ungerleider, H. E.: Electrocardiographic criteria of left ventricular hypertrophy; factors determining evolution of electrocardiographic patterns in hypertrophy and bundle branch block. *Arch. Int. Med.* 72: 196-209, 1943.
3. Simpson, F. O.: Electrocardiographic signs of left ventricular hypertrophy and strain in hypertensive patients. *Brit. Heart J.* 22: 227-235, 1960.
4. Cumming, G. R., and Proudfit, W. L.: High-voltage QRS complexes in absence of left ventricular hypertrophy. *Circulation* 19: 406-408, 1959.
5. Robb, J. S., and Robb, R. C.: Hypertension electrocardiograms experimentally produced and anatomically explained; left ventricular strain. *Am. J. M. Sc.* 203 (new ser.): 634-641, 1942.
6. Doyle, A. E.: Electrocardiographic changes in hypertension treated by methonium compounds. *Am. Heart J.* 45: 363-381, 1953.
7. Georgopoulos, A. J.; Proudfit, W. L., and Page, I. H.: Relationship between arterial pressure and negative U waves in electrocardiograms of hypertensive patients. *Circulation*: In press.
8. Page, I. H.; Corcoran, A. C.; Dustan, H. P., and Koppanyi, T.: Cardiovascular actions of sodium nitroprusside in animals and hypertensive patients. *Circulation* 11: 188-198, 1955.
9. Goldberger, E.: *Unipolar Lead Electrocardiography and Vectorcardiography*, 3d ed. Philadelphia: Lea & Febiger, 1953, 601 pp.; p. 209.
10. Sodi-Pallares, D., and Calder, R. M.: *New Bases of Electrocardiography*. St. Louis: C. V. Mosby Co., 1956, 725 pp.; p. 242.
11. Kossmann, C. E., and Johnston, F. D.: Precordial electrocardiogram; potential variations of precordium and of extremities in normal subjects. *Am. Heart J.* 10: 925-941, 1934-1935.
12. Lipeschkin, E.: *Modern Electrocardiography*, vol. 1: The P-Q-R-S-T-U Complex. Baltimore: Williams & Wilkins Co., 1951, 598 pp.; pp. 234-235.