

Cleveland Clinic Quarterly

Volume 28

JULY 1961

No. 3

"FUNCTIONING" PULMONARY NEOPLASMS:
I. THE CARCINOID TUMOR;
II. THE HEMANGIOPERICYTOMA

LAWRENCE J. McCORMACK, M.D.,
Division of Pathology

WILLIAM M. McISAAC, M.B., Ph.D., M.R.C.S.,
HAAKON RAGDE, M.D.,*
Division of Research

LAURENCE K. GROVES, M.D., and DONALD B. EFFLER, M.D.
Department of Thoracic Surgery

THE initial recognition of the so-called "carcinoid syndrome" by Thorson, Biörck, Björkman, and Waldenström,¹ as a clinicopathologic entity, has expanded the knowledge of functioning tumors to include neoplastic entities not previously believed to possess any endocrine activity. Although the disorder was initially believed to be limited to metastasizing gastrointestinal carcinoid tumors, evidence has accumulated that some malignant and metastasizing bronchial tumors have the same propensity to produce the syndrome of hyperserotonemia. In 1957 a review of 21 cases of bronchial adenoma, encountered and treated at the Cleveland Clinic, was reported.² Later, a case of malignant carcinoid diagnosed six months after the removal of a bronchial neoplasm³ aroused our interest in the possible serotonin-producing properties of these tumors; consequently, we have made a detailed study of the three such tumors encountered since that time.

*Formerly Fellow in the Department of Internal Medicine; present address: Apartment 27, Number 1, Ellerdale Avenue, Montreal, Quebec, Canada.

An allied problem concerns the nature of the hemangiopericytoma. This type of tumor was originally recognized by Stout and Murray,⁴ and a series of cases was reported by McCormack and Gallivan.⁵ Korn, Bensch, Liebow, and Castleman,⁶ however, have suggested the resemblance of one of these tumors to the "multiple peripheral bronchial adenomas."⁷ This stimulated us to make a detailed pathologic and biochemical study of a recent specimen of malignant hemangiopericytoma.

I. The Carcinoid Tumor

Report of Cases

Case 1. A 49-year-old white man was admitted to the Cleveland Clinic Hospital on January 31, 1960, because of a pulmonary "coin lesion." A routine chest roentgenogram revealed evidence of the lesion that in 1958 was diagnosed as "a small granuloma in the right mid-lung field." The patient was in good health and without a complaint. He underwent a cholecystectomy in 1957; his mother and one brother have diabetes mellitus.

Physical examination showed a well-developed, well-nourished white man in no distress. Oral temperature was 98.6 F.; radial pulse rate was 72 and regular; blood pressure was 140/80 mm. of Hg. The skin was of good color; the cholecystectomy scar was visible over the upper part of the abdomen. The chest was clear, and the heart was normal in size, had a good rhythm, and normal sounds. Cardiac murmurs were absent. The abdomen was scaphoid, and there were no palpable masses or enlarged organs. On a thoracic laminagram there was no evidence of a laminated type of calcification or a halo. A comparison of the current chest roentgenogram with the one in 1958 revealed evidence that the lesion had become sharply demarcated.

The hemoglobin was 16.0 gm. per 100 ml., and the cell volume was 48 ml. The urine specific gravity was 1.013, contained no albumin or sugar, and only an occasional leukocyte. A 5-hydroxyindoleacetic acid study was not done. Purified protein derivative tuberculin, and histoplasmin skin tests were both negative. A bronchoscopic examination revealed no evidence of the lesion, and washings obtained from the right lower lobe and the right main bronchi were free of tumor cells or microorganisms. An electrocardiogram was normal. On February 1, 1960, the patient underwent a right lower lobectomy. The postoperative course was uneventful, and the patient was discharged from the hospital on February 9, 1960. He has had no further pulmonary problems.

Case 2. A 54-year-old white man was admitted to the Cleveland Clinic Hospital on February 10, 1960, for investigation and treatment of a lesion in the left lower pulmonary lobe. Evidence of this lesion was discovered in 1956 on a routine chest roentgenogram, but the patient had no further investigation until an intermittent neuromuscular type of chest pain developed and he wondered whether or not there was a relationship between the mass and the pain. Upon admission to the hospital the patient was in good health.

He had had the usual childhood diseases without sequela. In 1921 he underwent a thyroidectomy for "goiter," and in 1956 a colostomy because of "rupture of the bowel." A year later he underwent "repair of the colostomy." Findings from his family history and systemic review were essentially normal.

On physical examination the radial pulse rate was 75; the blood pressure was 198/110 mm. of Hg. General appearance was that of a well-developed, well-nourished, middle-aged, white man with a "slight cyanotic flush to face and extremities," and in no distress. Oral temperature was 98.0 F. A thyroidectomy scar and four abdominal surgical scars were visible. The thorax revealed diminished expansion bilaterally. The breath sounds were diminished throughout the lung fields, but this decrease was more apparent over the apices. There was no dullness or rales or rhonchi. Cardiac murmurs were absent. The abdomen was soft, nontender, and no masses or enlarged organs were palpable. Peripheral arterial pulses were diminished in both lower extremities. A roentgenogram of the chest showed a 2-cm. round, sharply demarcated density in the region of the left mid-lung field. There was evidence of old, healed fractures of the seventh and eighth ribs posteriorly on the left. A vital capacity determination was within the normal range.

Studies of the blood yielded the following values: hemoglobin, 16.4 gm. per 100 ml.; cell volume, 48 ml.; leukocyte count, 5,700 per cubic millimeter, with a normal differential count. The Bromsulphalein test showed 10 per cent of the dye to be retained at 45 minutes. The thymol turbidity was normal. The blood urea was 18 mg. per 100 ml. and a fasting blood sugar concentration was 77 mg. per 100 ml. Electrolyte values were within the normal range. The urine specimen had a specific gravity of 1.022, and it contained no albumin or formed elements. The amount of 5-hydroxyindoleacetic acid in the urine was not determined.

On February 11, 1960, the patient underwent a left lower lobectomy. The operative report stated: "The left lung appears to be quite normal except for the lesion in the left lower lobe which by palpation was centrally located and was quite soft. The hilus is normal except for some minor node involvement which appears to be entirely inflammatory. I was impressed, however, by the moderate increase in pulmonary artery pressure and believe that this patient does have moderate pulmonary hypertension. The etiology of this is not apparent." The postoperative course was relatively uneventful with the exception of a rather severe adynamic ileus that cleared after conservative therapy. The patient was discharged from the hospital on February 25, 1960.

Case 3. A 48-year-old white man was admitted to the Cleveland Clinic Hospital on January 26, 1960, having been referred to us with a tentative diagnosis of bronchogenic carcinoma. About three weeks before that time the patient became ill with "the flu," and because of his slow recovery a chest roentgenogram was made; it disclosed evidence of an infiltrative lesion in the right lung. During the week before admission he improved, and upon arrival had no specific complaint. In 1955 he received antibiotics for "an abscess" in the right side of the chest. Findings from a review of the systems and the family history were essentially normal.

On physical examination he was well-developed, well-nourished, and in no distress. Oral temperature was 100.6 F., radial pulse rate was 80 and regular, and blood pressure was 125/70 mm. of Hg. The skin was of a good color, and there were no lymph node enlargements. The chest was clear according to percussion and auscultation, and examination of the heart disclosed no abnormality. Blood studies showed a hemoglobin content of 13.0 gm. per 100 ml., a cell volume of 40 ml., a leukocyte count of 12,000 per cubic millimeter with a relatively normal differential count. A fasting blood sugar

concentration was 88 gm. per 100 ml. and the blood urea content was 24 mg. per 100 ml. Urinalysis gave the following results: specific gravity 1.020, absence of sugar and albumin, and occasional erythrocytes and leukocytes in the sediments. The amount of 5-hydroxyindoleacetic acid in the urine specimen was not determined.

A bronchoscopic examination on the day of admission disclosed a lesion in the basal segment of the right lower lobe. A culture of bronchial washings produced an alpha hemolytic streptococcus, but neoplastic cells and acid-fast organisms were absent. After the bronchoscopic procedure, chills and fever developed; examination of the chest disclosed a dullness over the right paravertebral basal lung field. Decreased breath sounds and inspiratory rales were present over the same area. A chest roentgenogram revealed an area of infiltrate extending from the right hilus into the right lower lobe, and was thought to be compatible with pneumonitis secondary to obstruction from a neoplasm.

The pneumonic process responded well to treatment with antibiotics, and on February 3, 1960, the patient underwent operation. As a result of the recent exudative process the surgeon was unable to distinguish whether the neoplasm was benign or malignant, and therefore he performed a bilobectomy of the right lower and middle lobes. The patient had an uneventful postoperative course and was discharged from the hospital on February 10, 1960.

Pathologic findings. The tumors varied both in their gross and in their microscopic features. In the first patient (case 1) the lesion consisted of a 2.8-cm. red-gray, unobstructing, firm, homogeneous, circumscribed mass. A slight endobronchial protrusion extended into the posterior segment of the lower lobe bronchus. In the second patient (case 2) a 2-cm. gray-purple circumscribed tumor lay beneath the mucosa of the basal segment of the left lower lobe. It similarly expanded into the parenchyma, but no bronchial obstruction was present. In the third patient (case 3) the tumor was a 3.5-cm. by 2-cm. by 2-cm., gray, firm, homogeneous lesion that apparently arose in the posterior basal segment of the right lower lobe, completely obstructed it, and extended slightly into the main bronchus of the right lower lobe (*Fig. 1*). This extension produced partial blockade of the remaining bronchi to this lobe.

Microscopically, the neoplasm in patient 1 was comprised of uniform small cells so characteristic of the carcinoid of the bronchus (*Fig. 2A*). The sheets of cells were sharply margined from blood vessels, and focally contained areas of microcystic formation, which were irregular in shape and size and did not resemble true lumen formation. The microcysts contained a pink granular coagulum. Only at the margins of the tumor was there evidence of cording and small island formation. The individual cells possessed a sparse amount of indistinct pink-staining cytoplasm; the nuclei were uniform, round to oval, and possessed the characteristic chromatin stippling with occasional large masses that might be interpreted as nucleoli, which is so characteristic of these tumors. Mitosis was not apparent.

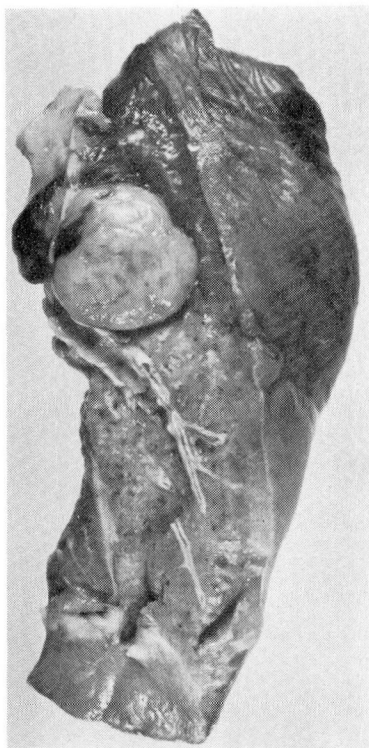


Fig. 1. Case 3. Photograph of resected right lower lobe. The endobronchial portion is demarcated by retention of bronchial cartilages.

In case 2 the neoplasm had a morphologic pattern similar to that in case 1 (*Fig. 2B*), but the cells were somewhat larger, and there was more cytoplasm present. The cells were sharply margined from the encompassed blood vessels.

In case 3 the neoplasm had large areas morphologically identical to those in case 1; however, there also were areas where the cells were arranged in cords with greater cell size and more nuclear irregularity (*Fig. 3*). These ribbons of cells contained frequent lumens. They were separated not by dense hyaline connective tissue, but by the microcystic areas that possibly could be degenerative in origin.

None of these tumors showed evidence of extension beyond their primary locations within the lungs. Regrettably, through a lack of foresight and possibly because of the previous poor results with formalin-fixed bronchial carcinoids, none of the available neoplastic tissue was fixed in formalin, and no report can be given as to the presence or absence of argentophilic granules.

Biochemical findings. The presence of serotonin in the tumorous tissue from the first two patients (cases 1 and 2) was established by chromatography and bio-

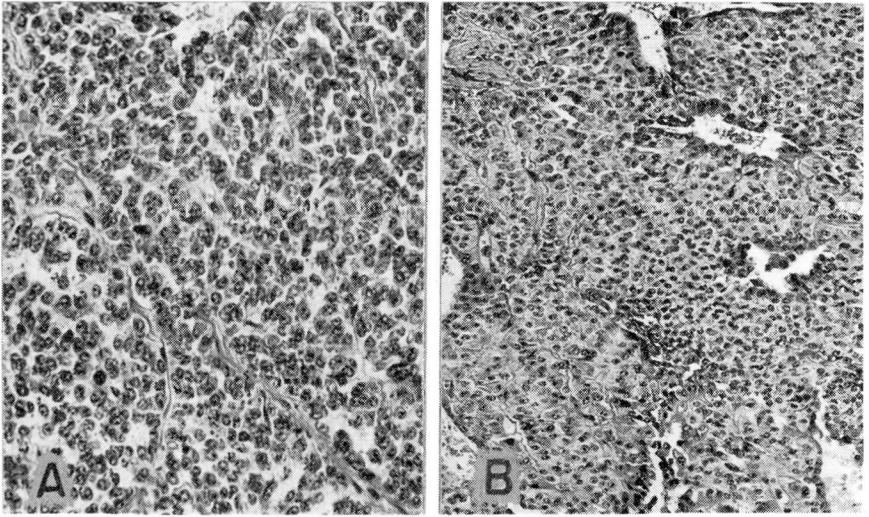


Fig. 2. Photomicrographs showing some of the varied carcinoid patterns. A, Case 1, characteristic pattern showing closely packed cells with stippled nuclei. Two microcysts are present. Hematoxylin-eosin stain; magnification X 300. B, Case 2, showing the cells to possess more cytoplasm but the same general type of arrangement. Hematoxylin-eosin stain; magnification X 165.

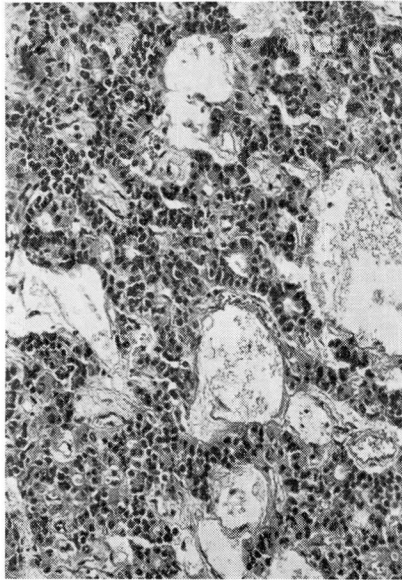


Fig. 3. Case 3. Different microscopic patterns are shown in many areas. The microcystic formation is prominent. In addition, acini can be seen in the cords of irregular cells. Hematoxylin-eosin stain; magnification X 160.

assay. Neoplastic tissue was homogenized in acetone, was filtered, and was concentrated to 0.5 ml. in vacuo at 37 C. The concentrate was used for paper chromatography in two solvent systems (A, propanol/ammonia, 7:3; B, butanol/acetic acid/water 4:1:5). A positive Ehrlich-reacting compound with R_f^* values of 0.48 and 0.54 (in solvents A and B respectively), which were identical with authentic serotonin, was observed. No chromatographic evidence for the presence of serotonin in the neoplastic tissue from the third patient (case 3) was found.

Aqueous dilutions of the concentrate were tested for their oxytocic activity on the isolated rat uterus preparation. The extracts of the neoplastic tissues from patients 1 and 2 had potent activity that could be completely antagonized by the addition of bromolysergic acid to the muscle bath. This provided further proof of the presence of large amounts of serotonin in these tissues. However, the extract of the tumor from patient 3 possessed only weak activity. Estimation of the amount of serotonin present in these tissues was made fluorometrically, using an Aminco-Bowman spectrophotofluorometer;⁸ the results are given in *Table 1*.

Table 1.—Identification and estimation of serotonin in bronchial adenoma tissue

Case	Identification		Serotonin content, micrograms per gram of tumor‡
	Chromatographic*	Biologic†	
1	+	+	160
2	+	+	20
3	—	±	5

* *Positive Ehrlich-reacting compound with the same R_f as authentic serotonin in two solvent systems.*

† *Oxytocic activity that could be inhibited by bromolysergic acid.*

‡ *Estimated spectrophotofluorometrically.*

II. The Hemangiopericytoma

Report of a Case

Case 4. A 49-year-old white housewife was first examined at the Cleveland Clinic in April, 1961, because of an asymptomatic nodule evidenced on a chest roentgenogram while the patient was hospitalized for cholecystectomy two months previously. The lesion was not disclosed on a mobile chest roentgenogram two years previously. The

* R_f value is the distance traveled by the compound divided by the distance traveled by the solvent front.

patient was entirely asymptomatic and had no unusual findings in her medical history. Her mother, a diabetic, had died of carcinoma of the breast.

Physical examination revealed a well-nourished, well-developed white woman in no distress with no physical abnormalities. The blood pressure was 160/90 mm. of Hg; height was 62½ inches; weight was 113½ pounds. The heart rate was regular.

A chest roentgenogram delineated evidence of a nodular lesion approximately 2 cm. in diameter in the posterior segment of the right upper pulmonary lobe. The lesion apparently was not calcified; there was no reaction around it. There was no evidence of hilar lymphadenopathy. The blood studies revealed: hemoglobin, 13.2 gm. per 100 ml.; cell volume, 37 ml.; leukocyte count, 10,500 (78 per cent neutrophils, 3 per cent eosinophils, 4 per cent lymphocytes, and 4 per cent monocytes) per cubic millimeter. Urinalysis revealed: specific gravity, 1.020; negative results of sugar and albumin tests; occasional erythrocytes and leukocytes. The patient was hospitalized and underwent a right upper lobectomy; postoperative recovery was uneventful.

Pathologic findings. The resected lung contained a 2-cm. tumor near the apex. It was associated with the anterior upper segment of the bronchial tree but did not appear to involve it. On cross section the lesion was faintly pink, firm, homogeneous, and bulged above the surrounding cut surface (Fig. 4). Microscopically, the tumor consisted of densely packed, small, spindle cells with hyperchromatic, round to slightly elongated nuclei. The cells were closely applied to thin-walled capillaries, and were arranged in small islands because of the great vascularity of the tumor (Fig. 5A); there was an intimate relationship throughout the entire tumor between the blood vessels and the masses of these spindle cells (Fig. 5B). Mitotic figures, some bizarre, were encountered in moderate numbers. Necrosis was absent. Fronds of the tumor appeared to extend into the surrounding pulmonary parenchyma. Small blood vessels, both arteries and veins, seemed to contain tumor. Because of the morphologic pattern, the diagnosis was malignant hemangiopericytoma.

Biochemical studies. The neoplastic tissue taken for biochemical analysis weighed 2.15 gm. (approximately half the entire tumor). It was homogenized immediately in acetone, was filtered, and then was concentrated. Chromatography did not reveal the presence of serotonin or other indolic compounds. There was, however, chromatographic evidence of the presence of two quaternary compounds that gave positive phosphomolybdic reactions. One of these compounds had the same properties as acetylcholine R_f 0.30 (solvent B). The other compound, R_f 0.90 (solvent B), could not be identified but was not choline R_f 0.25 (solvent B).

Aqueous dilutions of the concentrate were used for bioassay. Oxytocic activity was observed, but since bromolysergic acid only slightly inhibited the smooth-muscle contraction, the major myotrophic component was thought to be something other than serotonin. The contraction, however, could be blocked with atropine (0.1 µg. to the 10-ml. muscle bath) indicating that it was due to acetyl-



Fig. 4. Case 4. Resected upper lobe containing the isolated tumor. No statement can be made as to whether the lesion is primary or metastatic; but it is thought to be the former.

choline or an acetylcholine-like compound. The amount present assayed against a standard proved to be equivalent to 10 μg . acetylcholine per gram of neoplastic tissue.

Since the patient had received a small dose of succinylcholine with the premedication, the possibility that the chromatographic and biologic findings might be due to traces of the drug had to be considered. Although unlikely, since a 500-fold concentration in the neoplastic tissue would have been necessary, the possibility was tested in the following way. Two control tumors removed from patients who had received the same type of premedication were extracted and were chromatographed in the same way. There was no evidence of the presence of succinylcholine.

The amount of serotonin present was assayed spectrophotofluorometrically⁸ and by bioassay, only that part of the smooth-muscle contraction that could be inhibited by bromolysergic acid being ascribed to the amine. The serotonin content of this neoplasm was 4 μg . per gram of tissue.

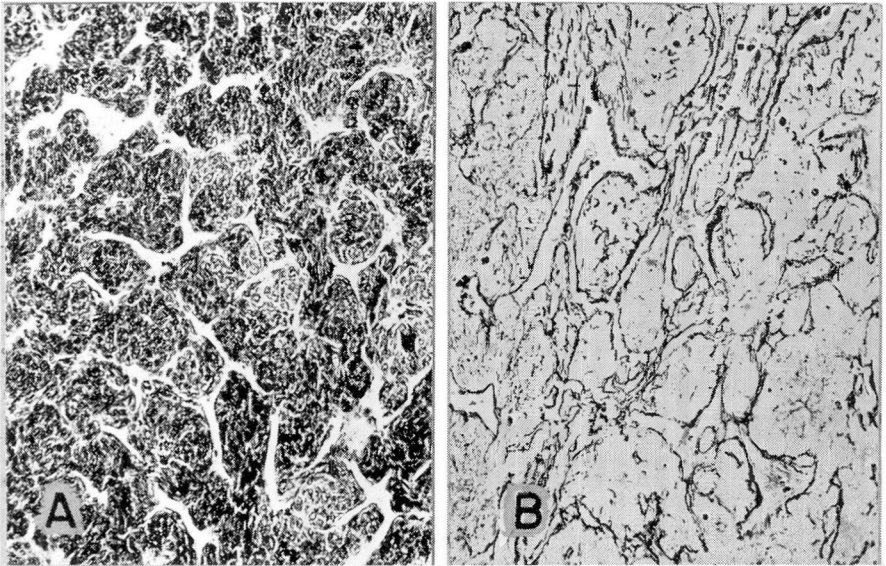


Fig. 5. Case 4. A, Photomicrograph showing closely packed cells with their intimate relationship to vascular channels. Hematoxylin-eosin stain; magnification X 160. B, Reticulin stain emphasizes the margins of the vascular channels; magnification X 100.

Comment

The relationship between certain bronchial neoplasms and the malignant carcinoid syndrome has been recognized by Schneckloth, McIsaac, and Page,³ and by Sjoerdsma.⁹ Others^{10,11} even contend that the term "carcinoid tumor" should be used in the diagnosis of all such neoplasms, benign or malignant, within the bronchus. To substantiate this concept, the presence of serotonin in the small, apparently benign tumors had to be established. Our study has demonstrated the presence of significant amounts of serotonin in such small, apparently benign, bronchial tumors. Presumably there are cells within the bronchial mucosal glands which, although weakly argyrophilic, possess a serotonogenic property. Tumors of these cells, whether benign or malignant, commonly retain this property and consequently should be regarded as "carcinoid tumors."

The results of our biochemical studies of the hemangiopericytoma invite speculation. The presence of a compound that had chromatographic and biologic properties similar to those of acetylcholine, in greater concentration than is found in the central nervous system, would indicate that the tumor had arisen from cells that may have an important physiologic role. If the hemangiopericytoma arises from a specialized cell that occurs as a component of the arteriovenous glomus and produces acetylcholine, this might account for the rapid changes in such arteriovenous shunts in contrast to other capillary action.¹² This straightforward

interpretation of the data is complicated by the presence of another unidentified quaternary compound. Since muscle can produce quaternary compounds, e.g., carnitine, it is not possible at this time to do more than to speculate concerning the physiologic role of the hemangiopericyte.

In conclusion, the correlation of pathologic lesions with the production of physiologically active compounds has proved fruitful in confirming the "carcinoid" nature of some bronchial adenomas, and in arousing speculation in regard to the nature of the hemangiopericyte and its possible role in the regulation of arteriovenous shunts.

Summary

1. The presence of significant amounts of serotonin in some bronchial adenomas has confirmed the "carcinoid" nature of these neoplasms.

2. The presence of two quaternary compounds, one of which was probably acetylcholine, in a hemangiopericytoma has led to speculation concerning the possible physiologic role of the "glomus cell" in the control of arteriovenous shunts.

References

1. Thorson, Å. H.; Biörck, G.; Björkman, G., and Waldenström, J.: Malignant carcinoid of small intestine with metastases to liver, valvular disease of right side of heart (pulmonary stenosis and tricuspid regurgitation without septal defects), peripheral vasomotor symptoms, bronchoconstriction, and unusual type of cyanosis; clinical and pathologic syndrome. *Am. Heart J.* 47: 795-817, 1954.
2. Knesevitch, E. M.; McCormack, L. J.; Effler, D. B., and Groves, L. K.: Bronchial adenoma; clinicopathologic study of 21 cases. *Cleveland Clin. Quart.* 24: 160-173, 1957.
3. Schneckloth, R. E.; McIsaac, W. M., and Page, I. H.: Serotonin metabolism in carcinoid syndrome with metastatic bronchial adenoma. *J.A.M.A.* 170: 1143-1147, 1959.
4. Stout, A. P., and Murray, M. R.: Hemangiopericytoma; vascular tumor featuring Zimmermann's pericytes. *Ann. Surg.* 116: 26-33, 1942.
5. McCormack, L. J., and Gallivan, W. F.: Hemangiopericytoma. *Cancer* 7: 595-601, 1954.
6. Korn, D.; Bensch, K.; Liebow, A. A., and Castleman, B.: Multiple minute pulmonary tumors resembling chemodectomas. *Am. J. Path.* 37: 641-672, 1960.
7. Felton, W. L., II; Liebow, A. A., and Lindskog, G. E.: Peripheral and multiple bronchial adenomas. *Cancer* 6: 555-567, 1953.
8. Bogdanski, D. F.; Pletscher, A.; Brodic, B. B., and Udenfriend, S.: Identification and assay of serotonin in brain. *J. Pharmacol. & Exper. Therap.* 117: 82-88, 1956.
9. Sjoerdsma, A.: Serotonin. *New England J. Med.* 261: 181-188, 1959.
10. Weiss, J., and Ingram, M.: Adenomatoid bronchial tumors. Consideration of carcinoid tumors and salivary tumors of bronchial tree. *Cancer* 14: 161-178, 1961.

11. Goodner, J. T.; Berg, J. W., and Watson, W. L.: Nonbenign nature of bronchial carcinoids and cylindromas. *Cancer* 14: 539-546, 1961.
12. Clark, E. R.: Arterio-venous anastomoses. *Physiol. Rev.* 18: 229-247, 1938.